



CONTROVERSIES & UPDATES IN VASCULAR SURGERY

JANUARY 25-27 2018



MARRIOTT RIVE GAUCHE & CONFERENCE CENTER, PARIS, FRANCE

A Banding Failure Mechanism

A mechanism of banding failure in mega-fistulas

Alexandros Mallios MD, John Lucas III MD, William Jennings MD



L'INSTITUT
MUTUALISTE
MONTSOURIS



Greenwood Leflore Hospital


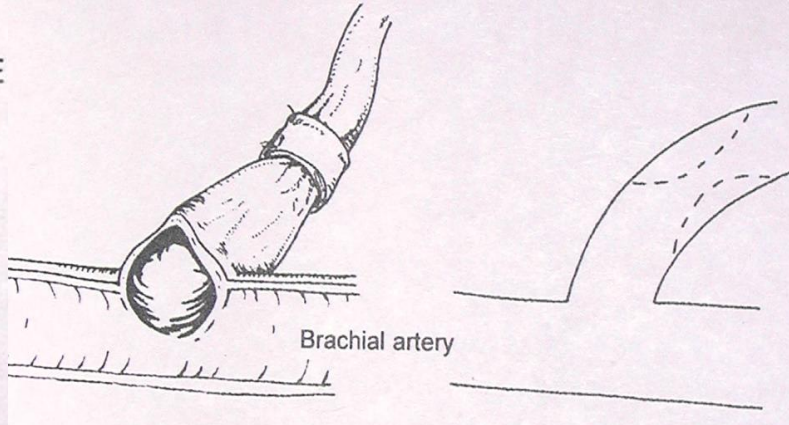
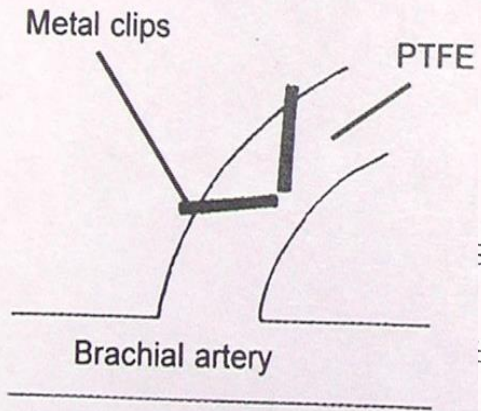




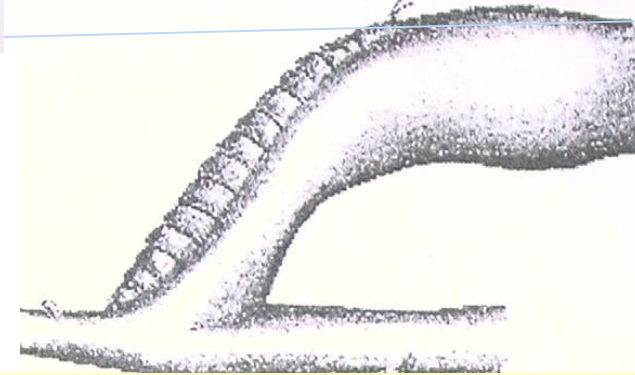
No Disclosures



L'INSTITUT
MUTUALISTE
MONTSOURIS


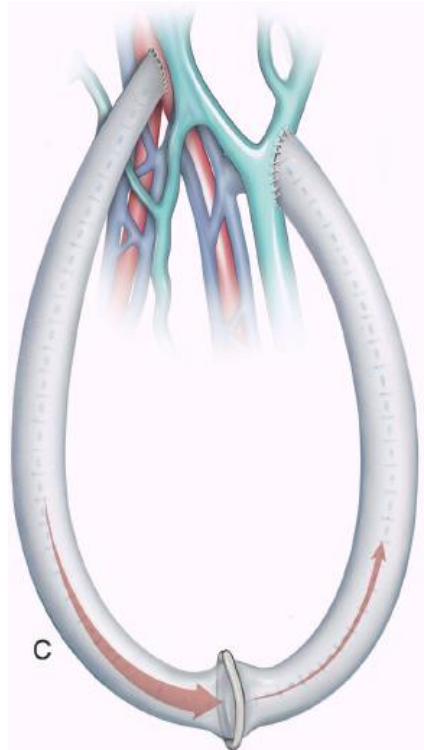


Bakran A. in Vascular Access Simplified. 2003 Trinity Press



Zanow J. in Vascular Access for HD VII. 2001 Precept Press

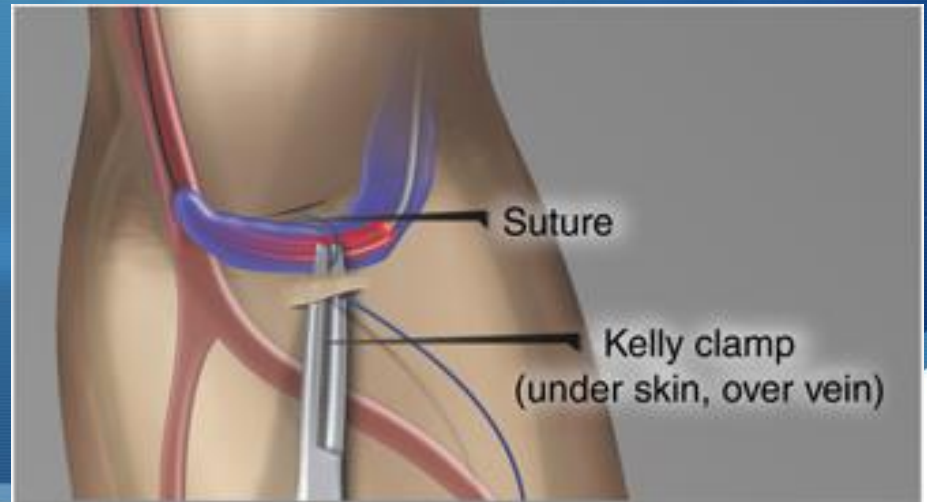
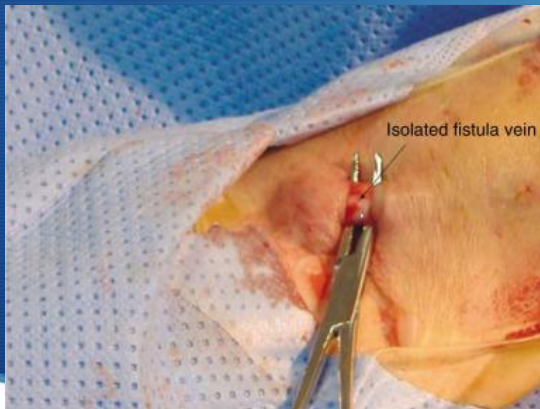
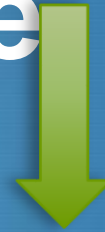So many options.....!

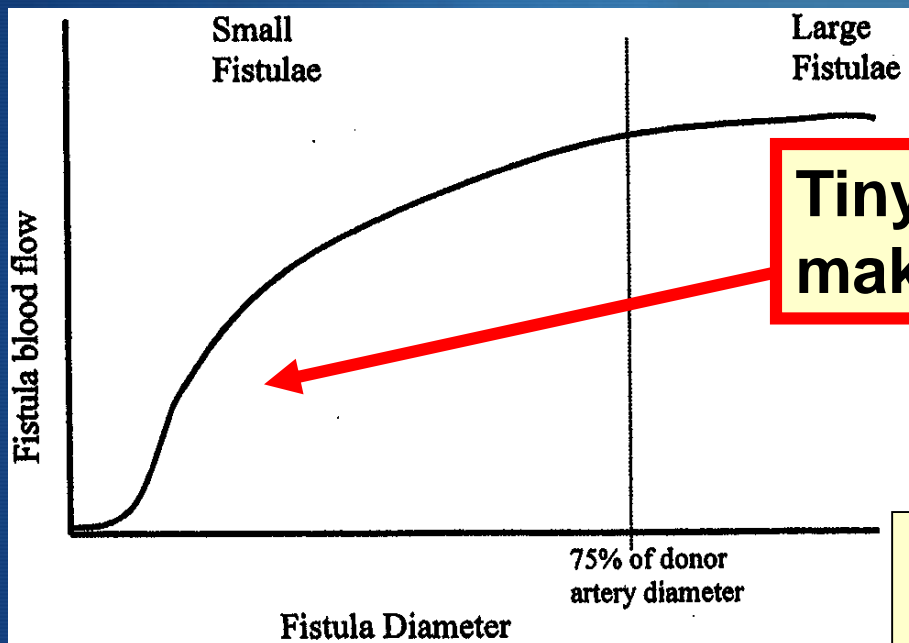


Rubio PA. Atlas of Angioaccess Surgery. 1983 Year Book Medical Publishers

Malik J, Davidson I. J of Vasc Access 2008;9:155-1666

Post-anastomotic Resistance Fistula Flow

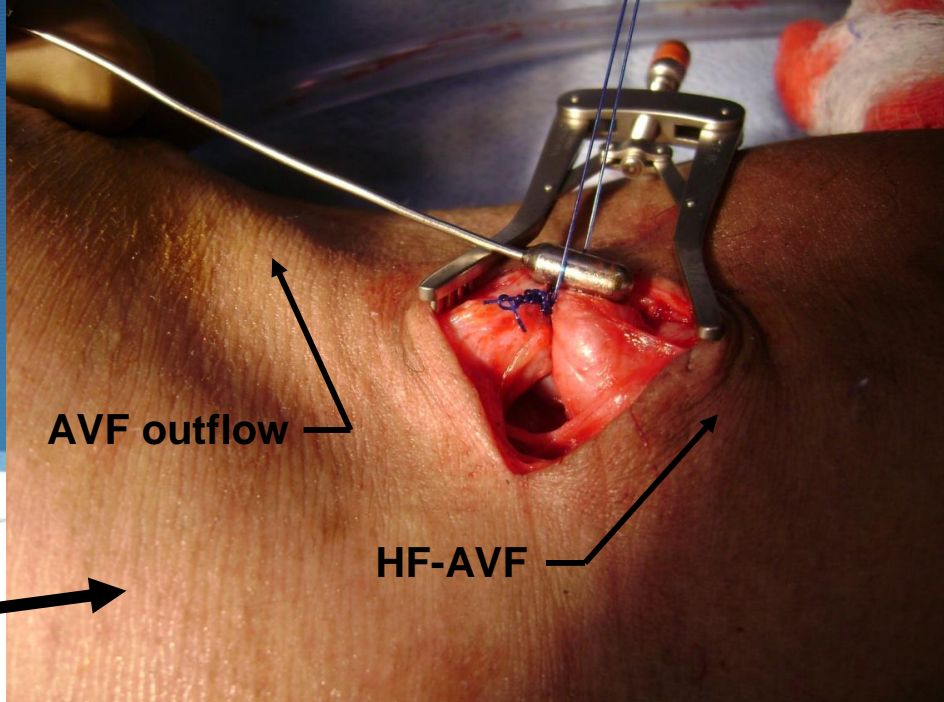




Tiny increments in AVF diameter make *major* changes in flow.

Wixon CL, Hughes JD, Mills JL. Understanding strategies for the treatment of ischemic steal syndromes after hemodialysis access. J Am Coll Surg. 2000 Sep;191(3):301-310.

Figure 2. Sigmoid curve reflecting the flow through an arterio-venous fistula as a function of fistula diameter. Blood flow in small fistulas (20% to 75% of the donor artery diameter) is directly proportional to fistula diameter. Blood flow in large fistulas is independent of the fistula diameter and depends more on the resistance of the inflow artery, the peripheral circulation, and the collateral network.

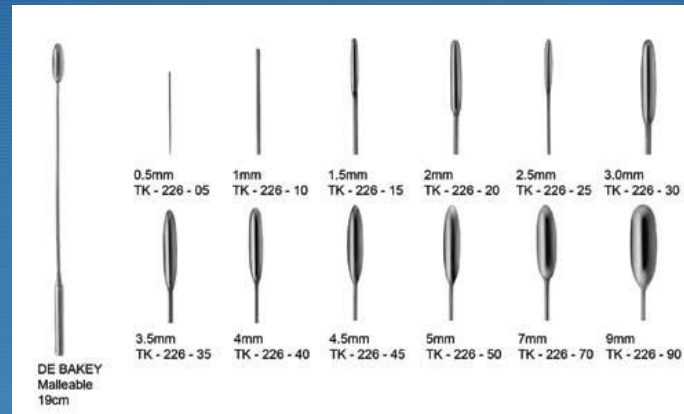


US calculated flow in brachial artery as a surrogate for AVF flow

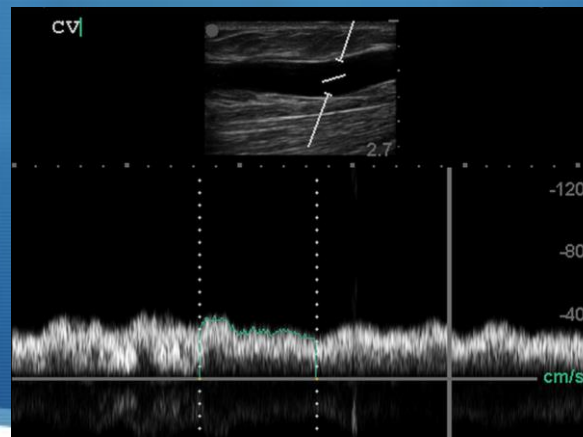
- Precision banding using a vessel dilator as a dowel.
- Flow restriction is created adjacent to the AVF anastomosis, using polypropylene suture and sized in 0.5 mm diameter increments.
- AVF flow rates are re-measured until the target access flow is achieved (500-800ml/min). A second suture was placed at the same site for security.

Gkotsis G, Jennings WC, Malik J, Mallios A, Taubman K. Treatment of high flow arteriovenous fistulas after successful renal transplant using a simple precision banding technique. *Ann Vas Surg.* 2016, Feb;31:85-90.

1. Precision



2. Use of Ultrasound



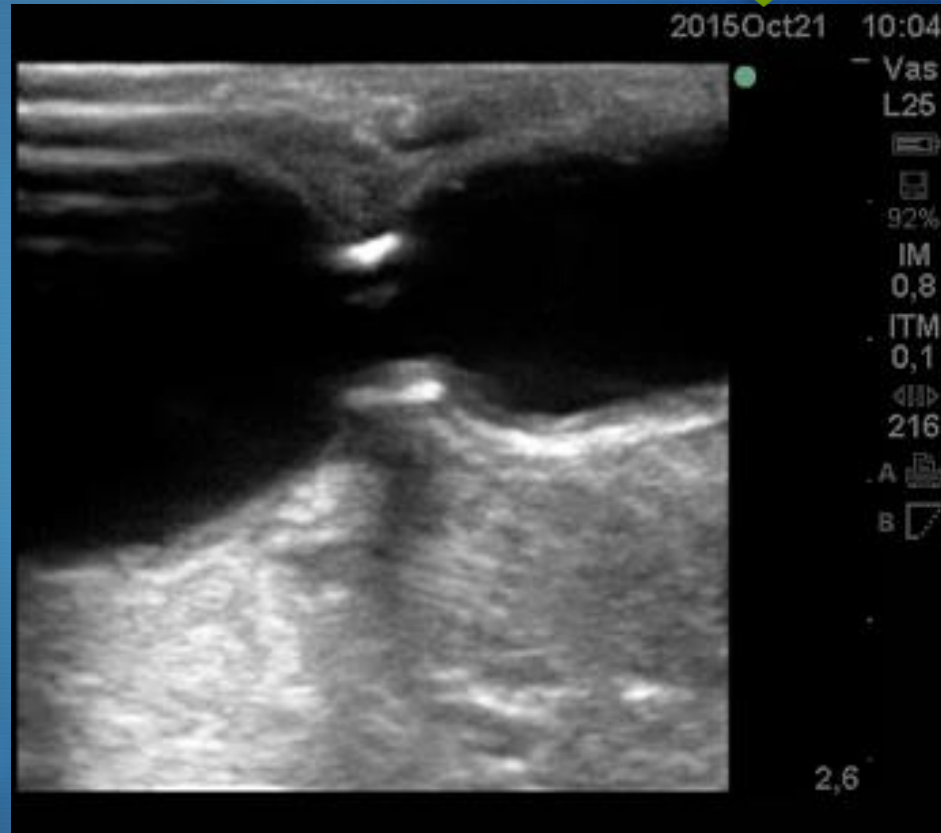
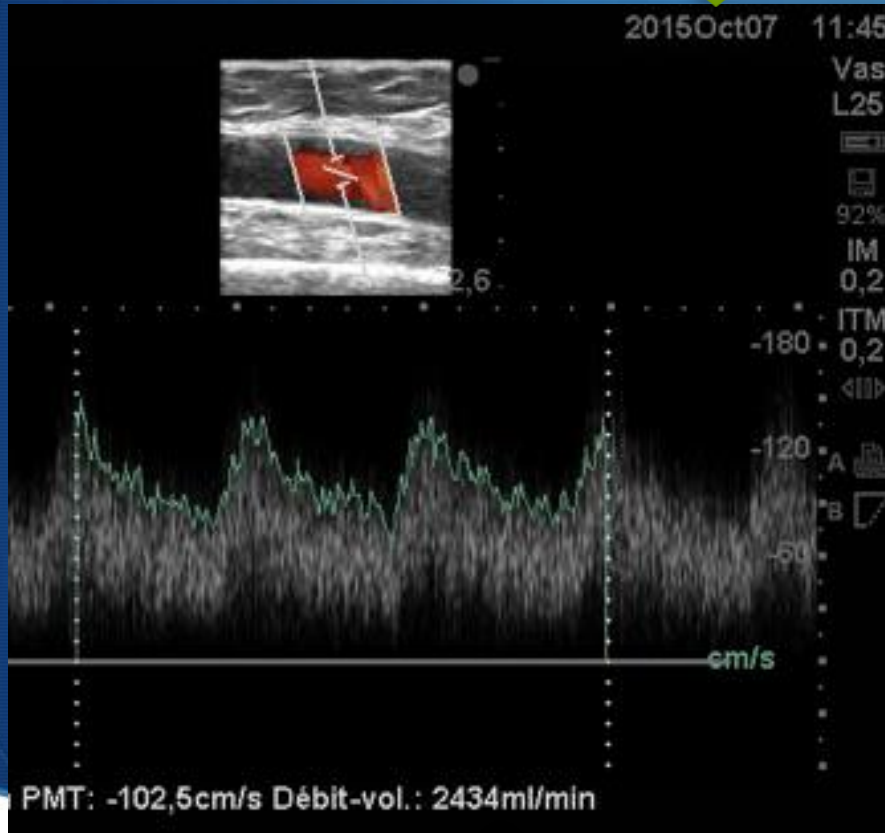
Real time perioperative ultrasound flow replaces guess work!!!

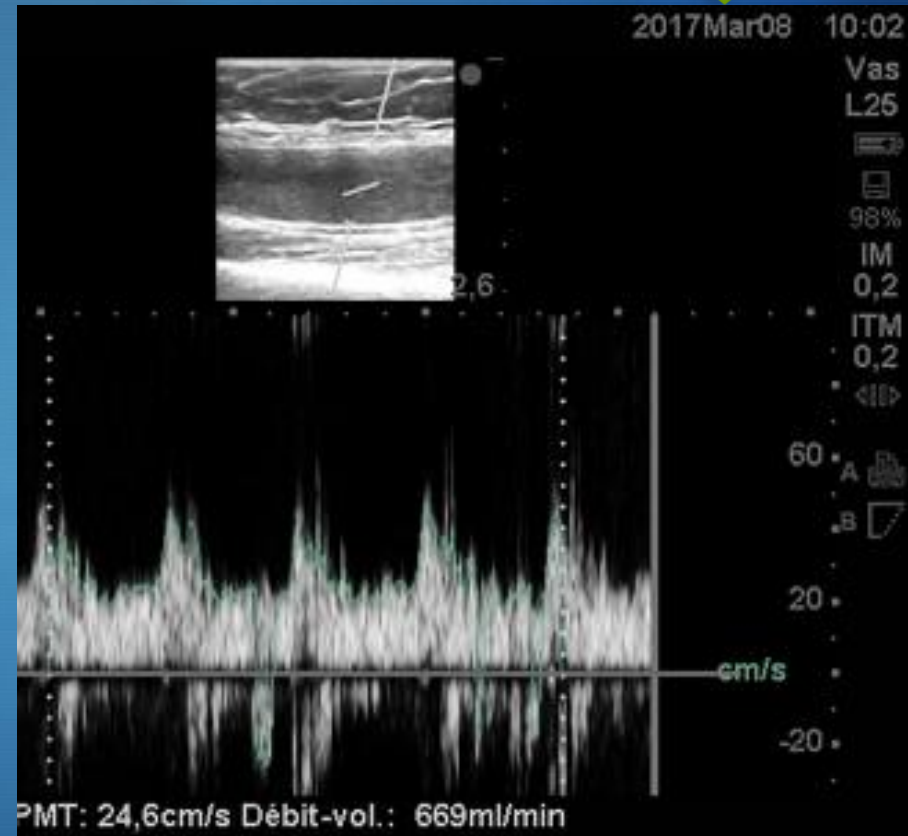
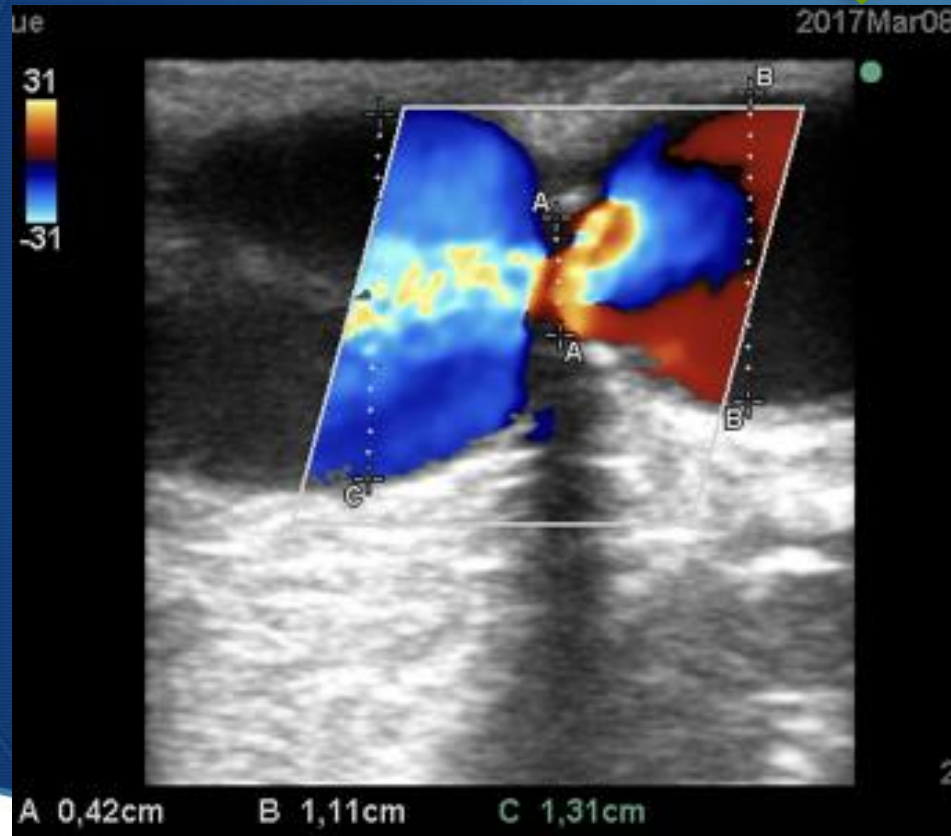Local Anesthesia to Avoid Blood Pressure Variations



Banding Works and is
Durable







However, one lovely
afternoon in.....



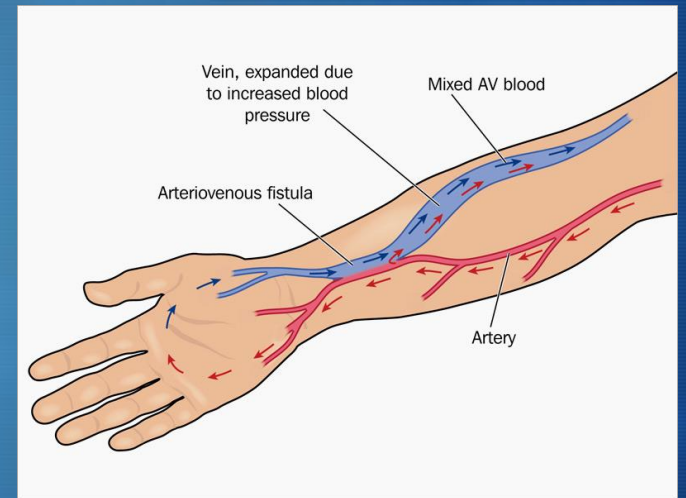
....Jamaica





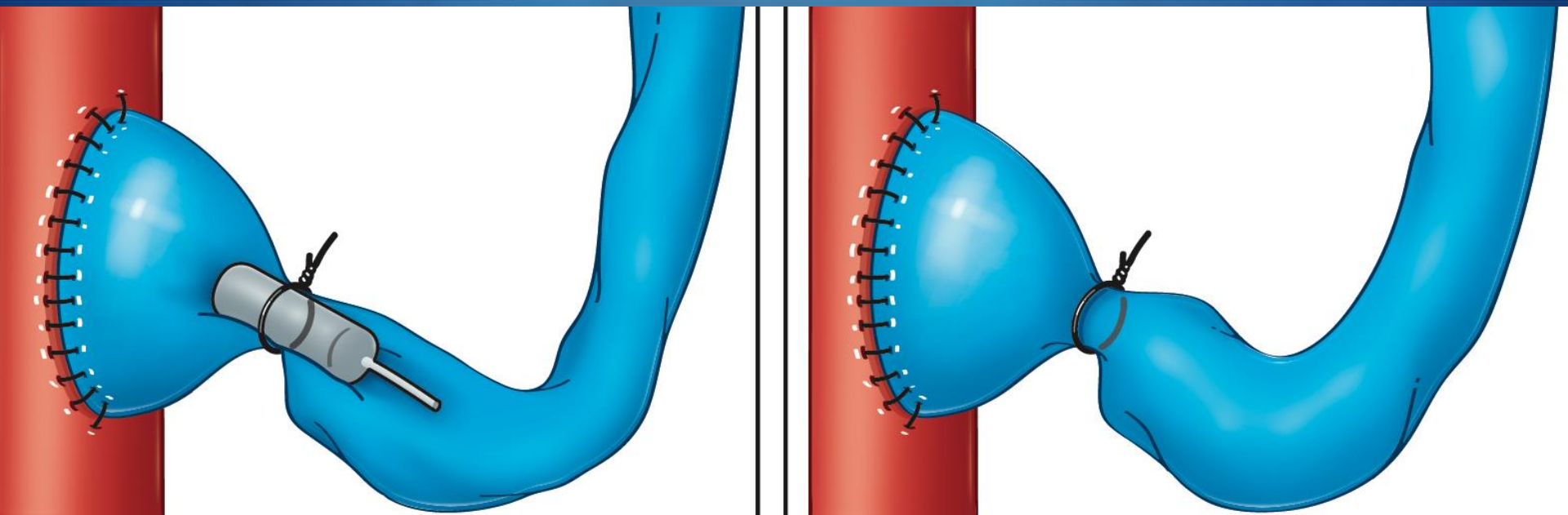


VS

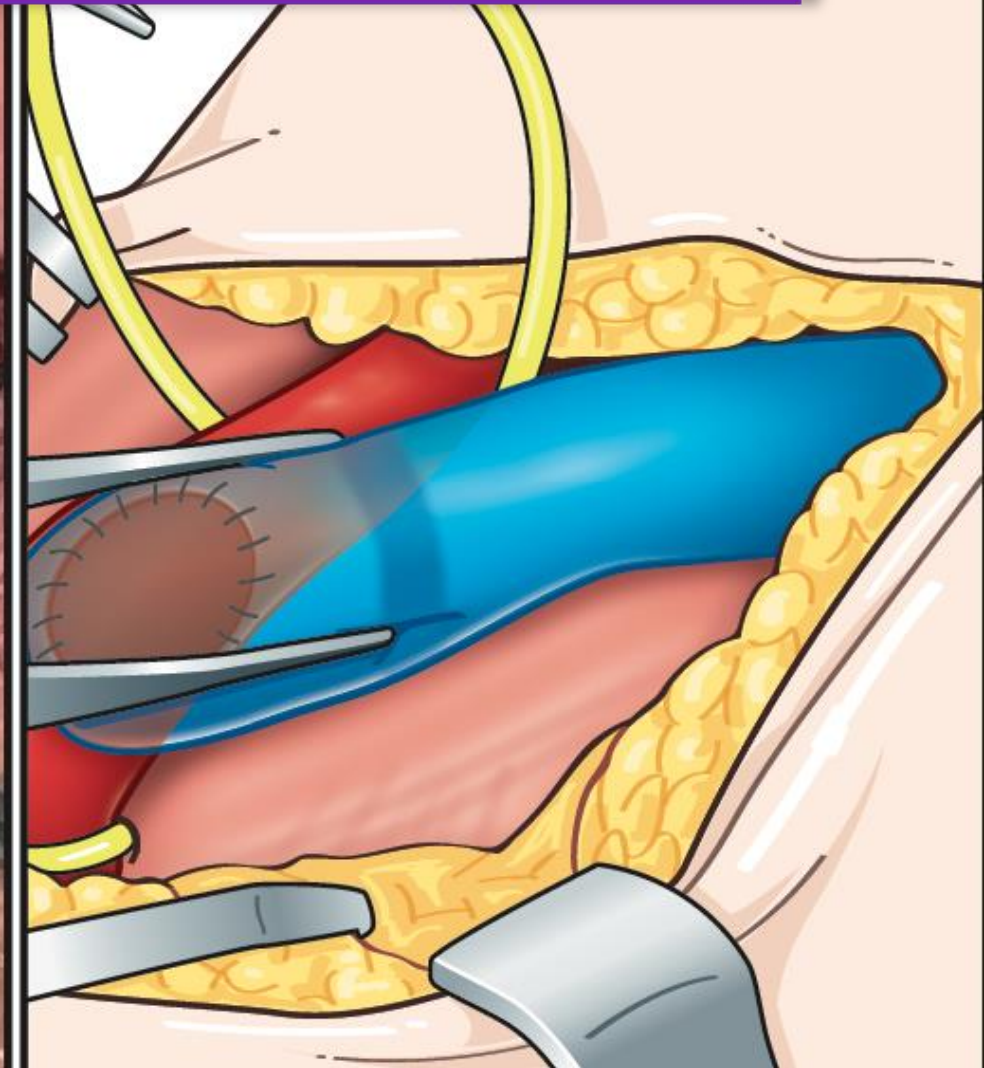
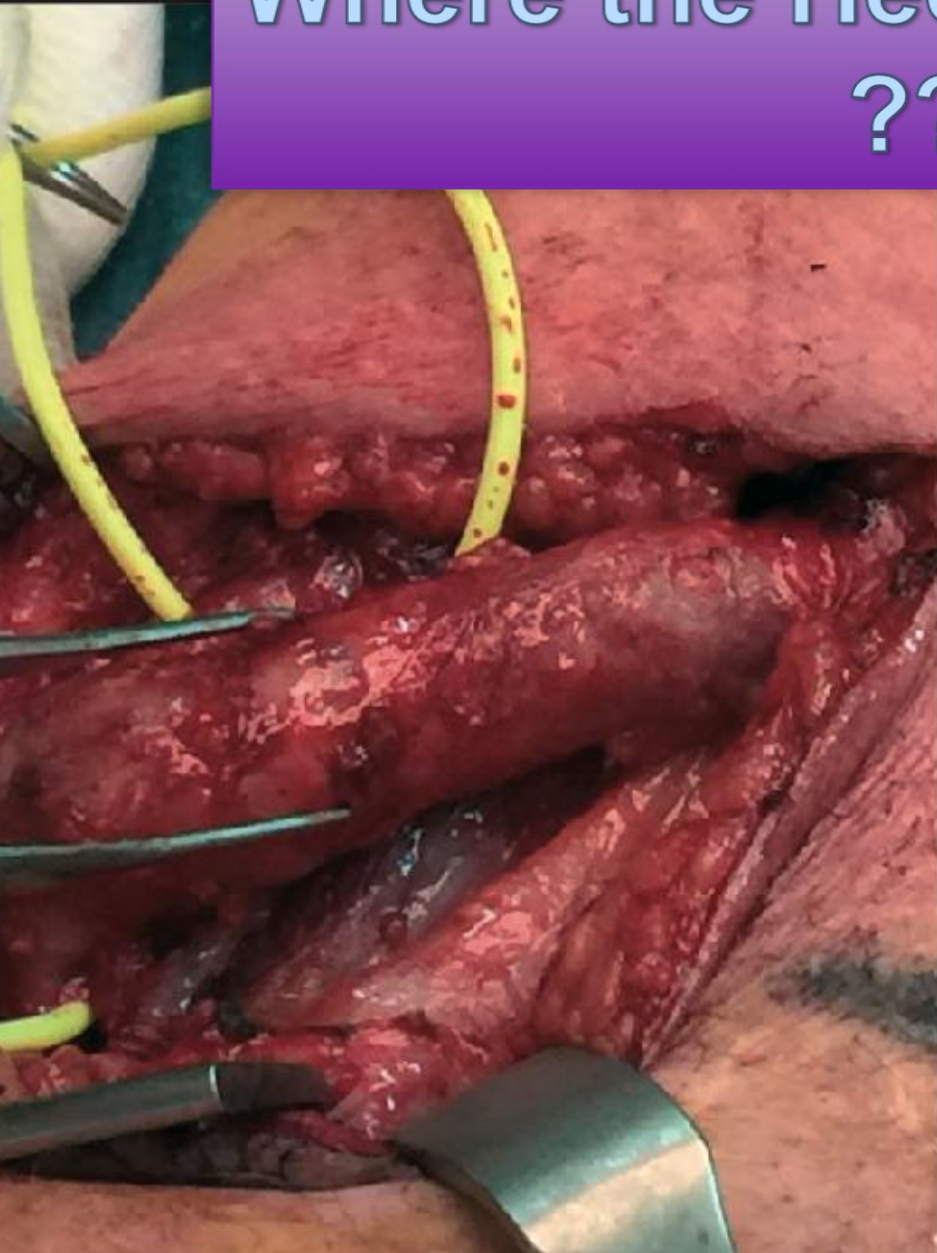

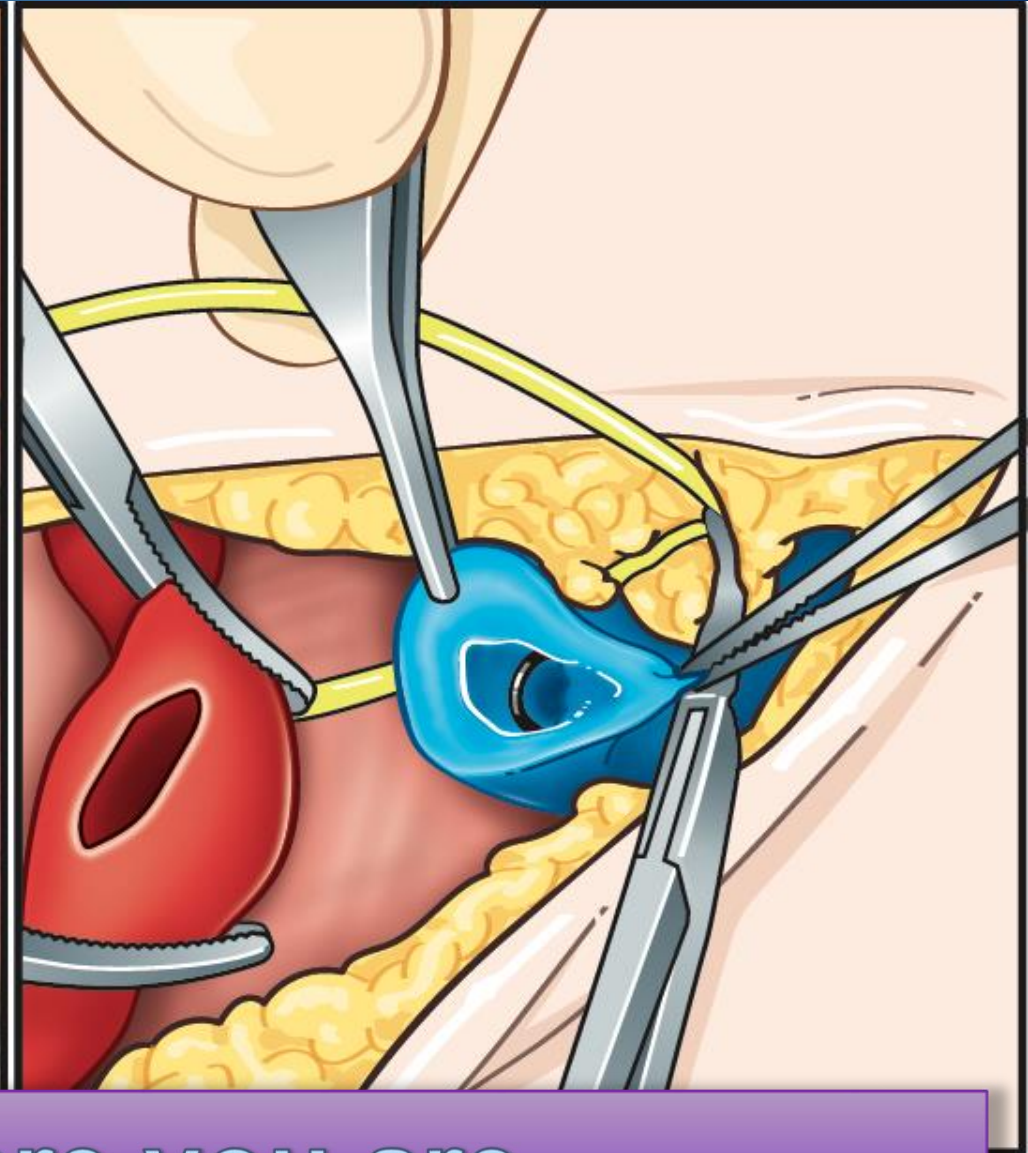
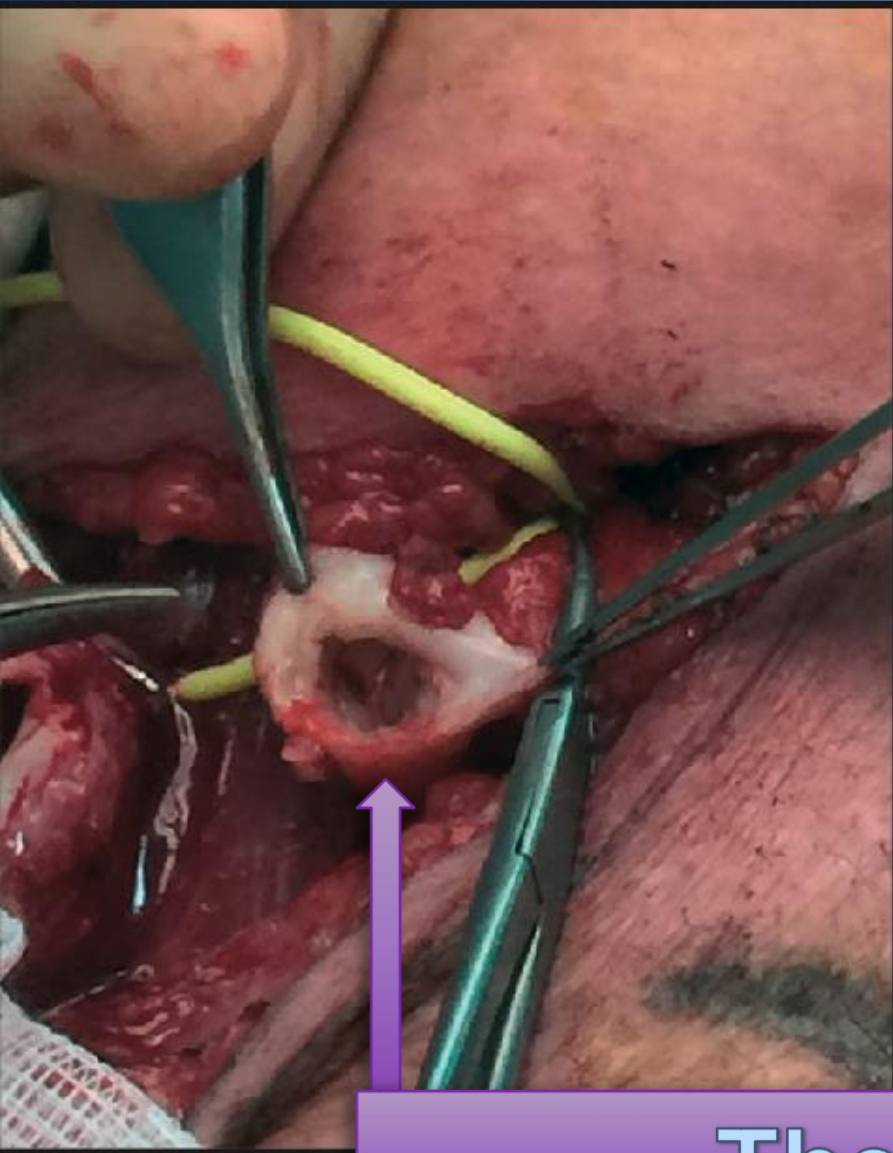4 patients took back for failure of
banding...

found exactly the same thing...

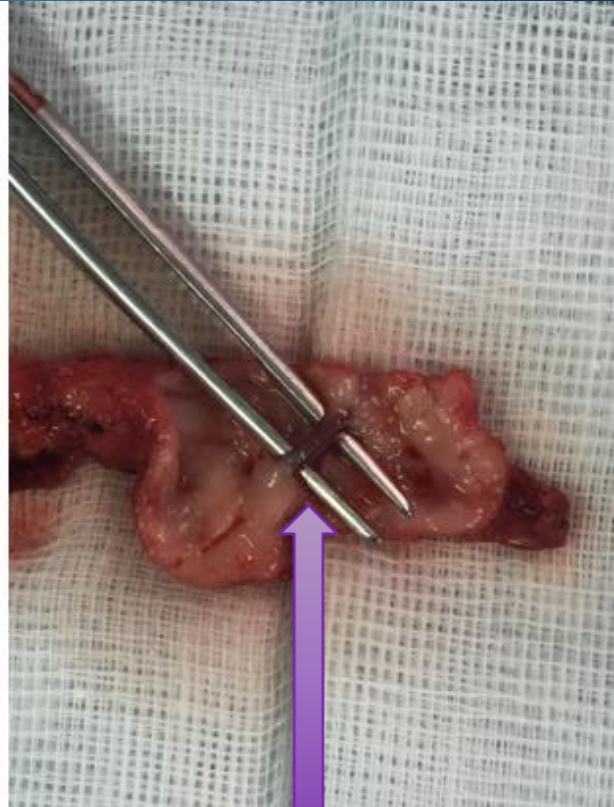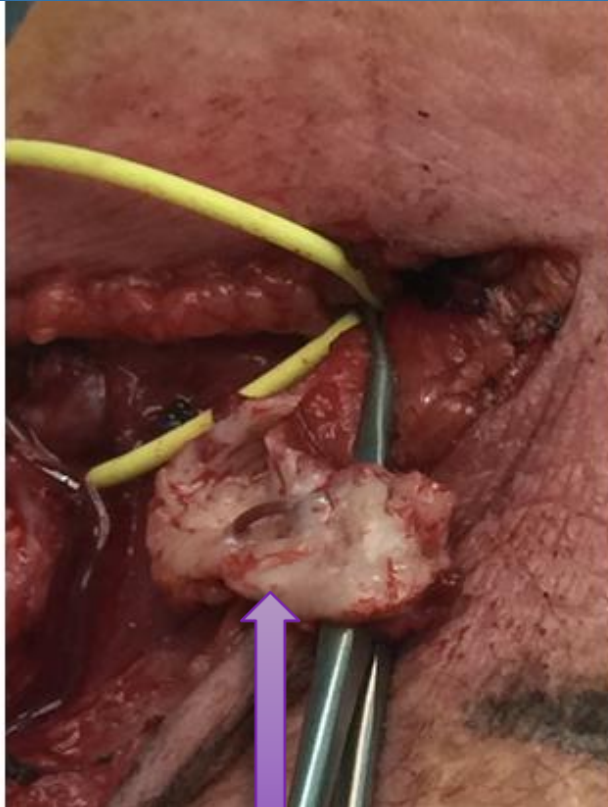
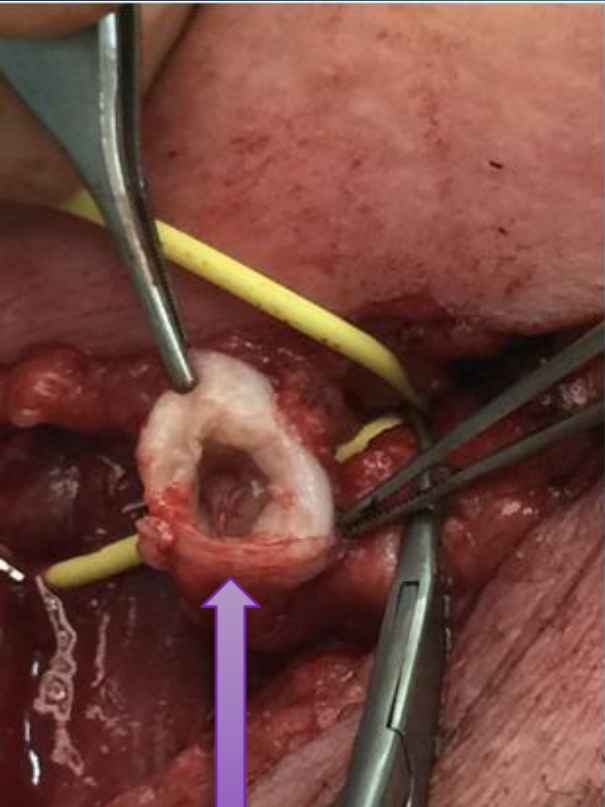


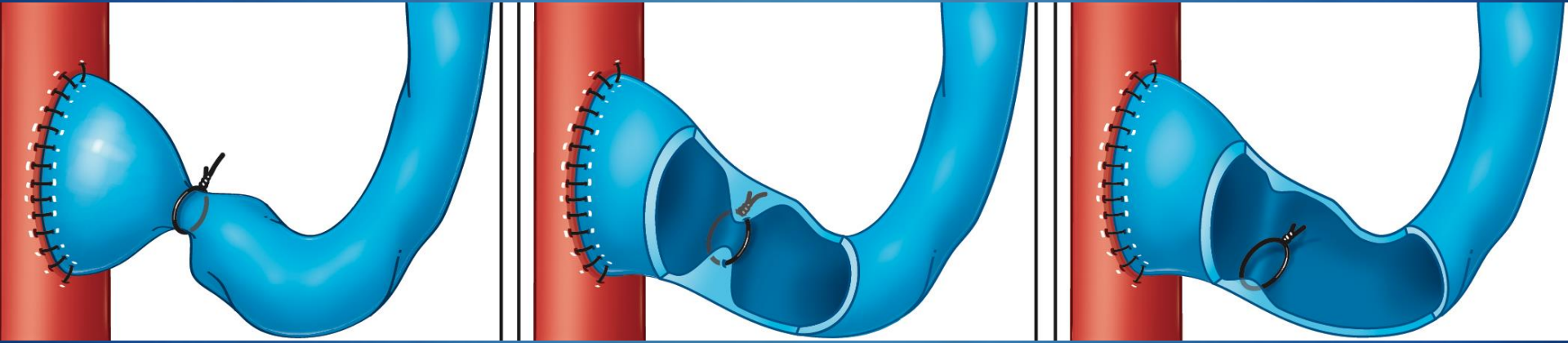
Where the Heck is my Suture ?????





There you are...





- >2cm AVF
- Uncontrolled BP???
- Second suture to taper down??

- Banding Works..
- Caution when it comes to “Mega-Fistulas”
- No single operation is best for all patients...

Thank you for your attention



L'INSTITUT
MUTUALISTE
MONTSOURIS



i-AS 2018

International
Vascular Access
Symposium

PARIS - Friday 14th September 2018

Institut Mutualiste Montsouris

Save the
Date!!!



Institut Mutualiste Montsouris

CONFERENCE DIRECTOR:
Alexandros Mallios MD

SCIENTIFIC Co-DIRECTORS:
Pierre Bourquelot MD
Myriam Combes MD, MBA
William Jennings MD

RENSEIGNEMENTS & LOGISTIQUE
 15 rue de Caumartin
75009 PARIS

Tél. : +33 (0)1 53 79 05 05
Fax : +33 (0)1 53 79 26 88
contact@cr2conseil.com
www.cr2conseil.com

www.ivas2018.com