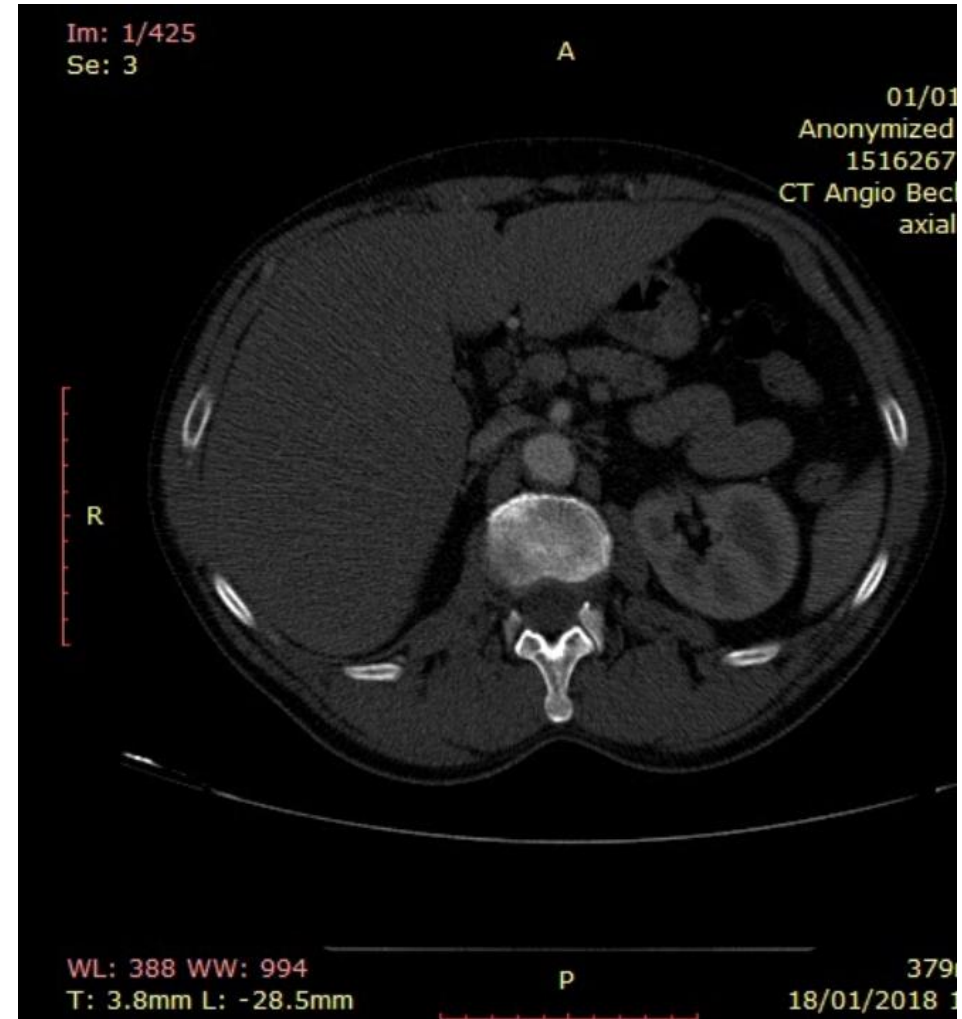




Case presentation

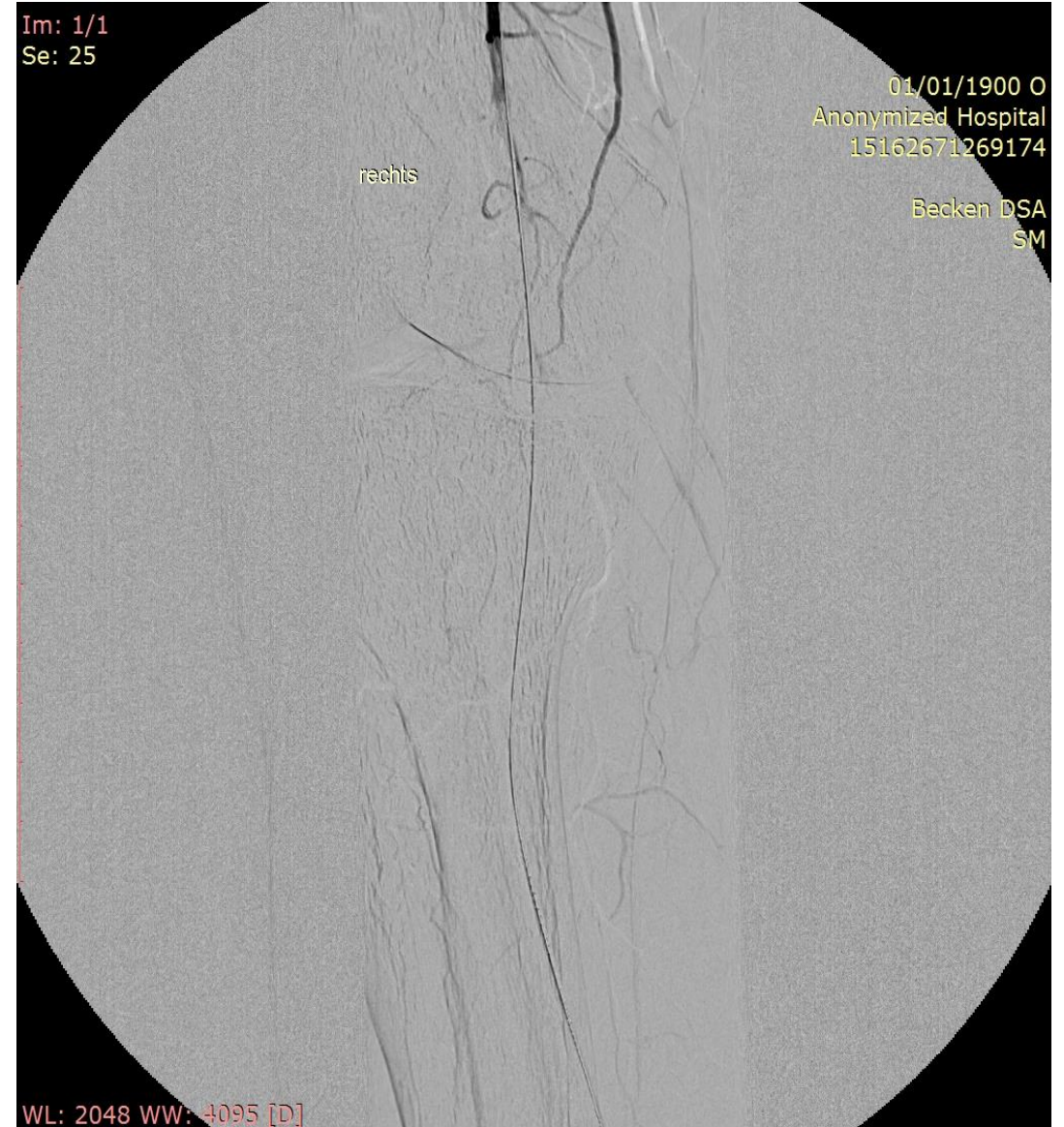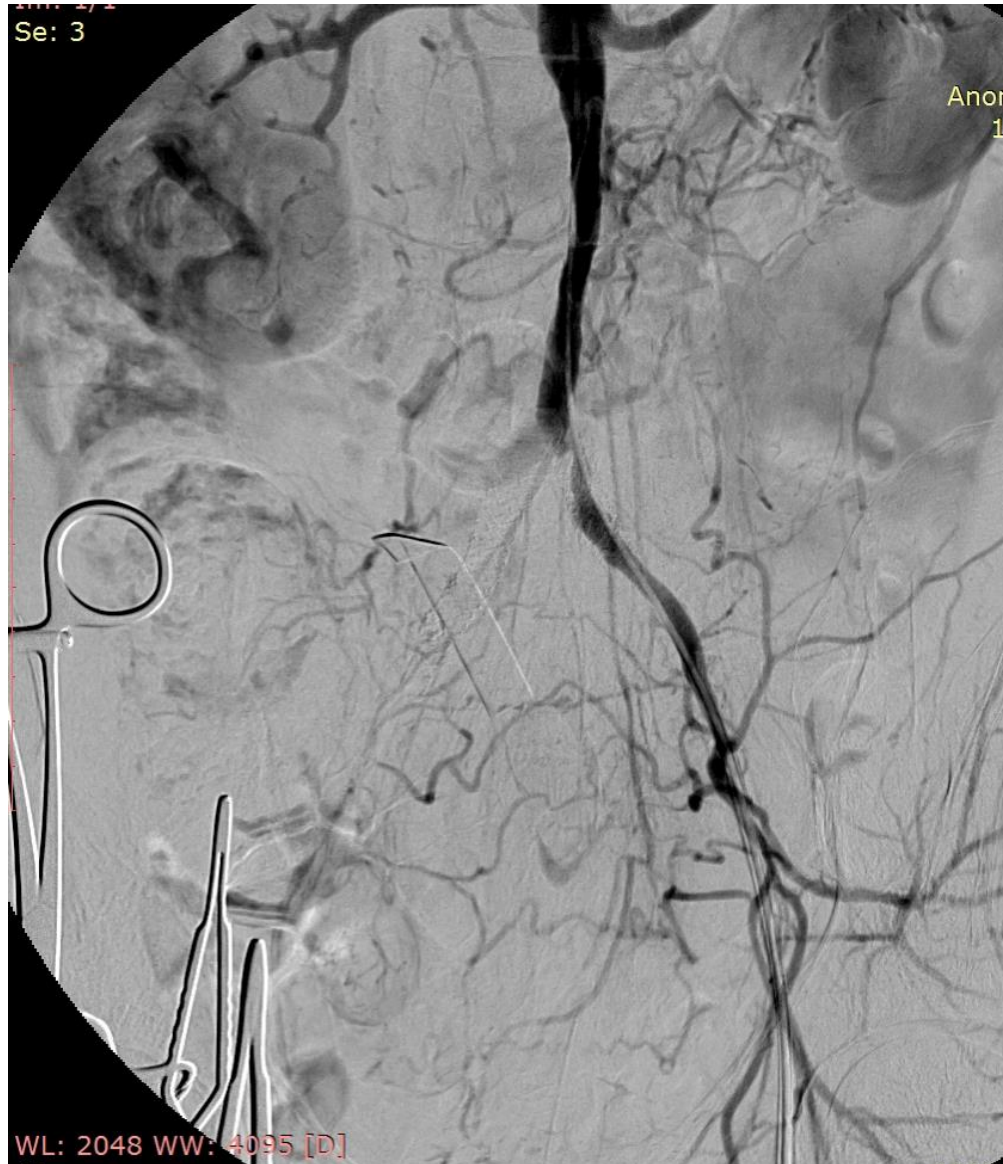51-year old patient with acute ischemia of the right limb

History of drug- and nicotine abuse, limited compliance

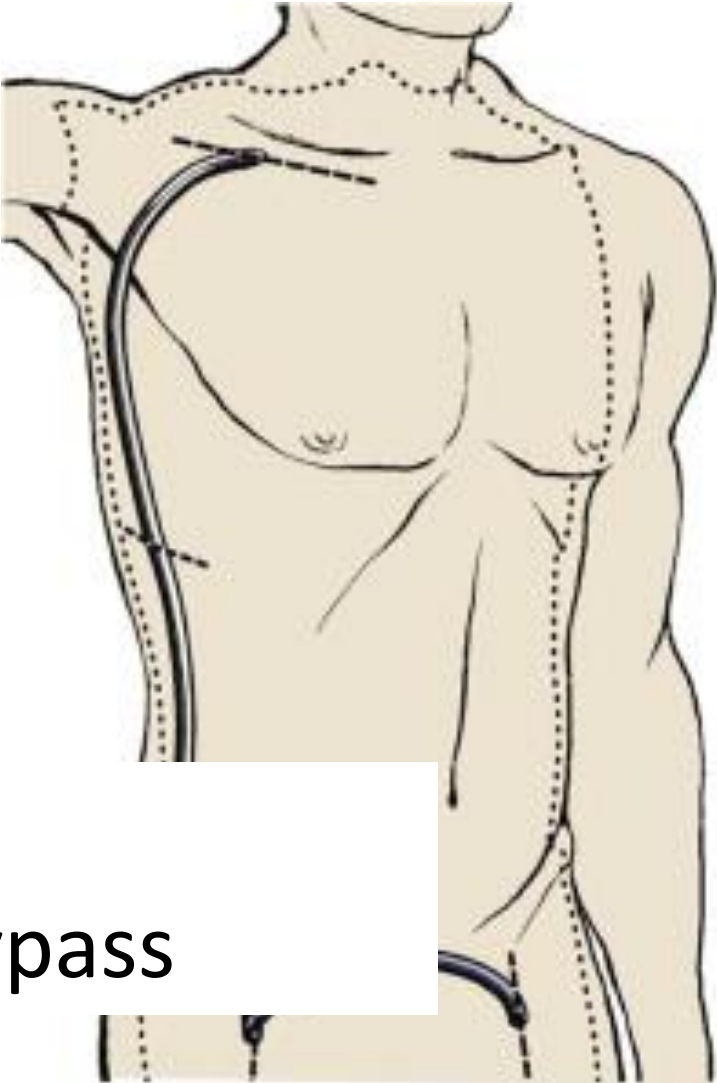
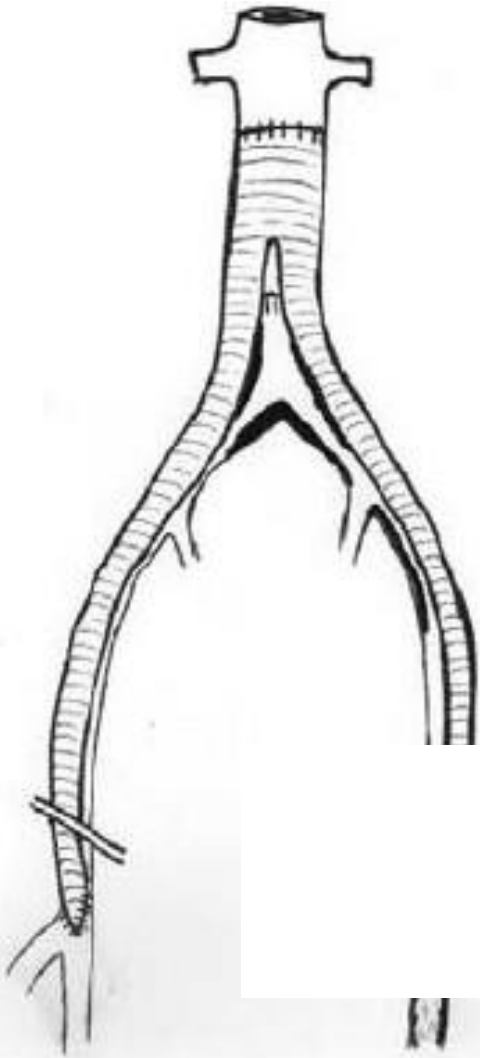




Case presentation



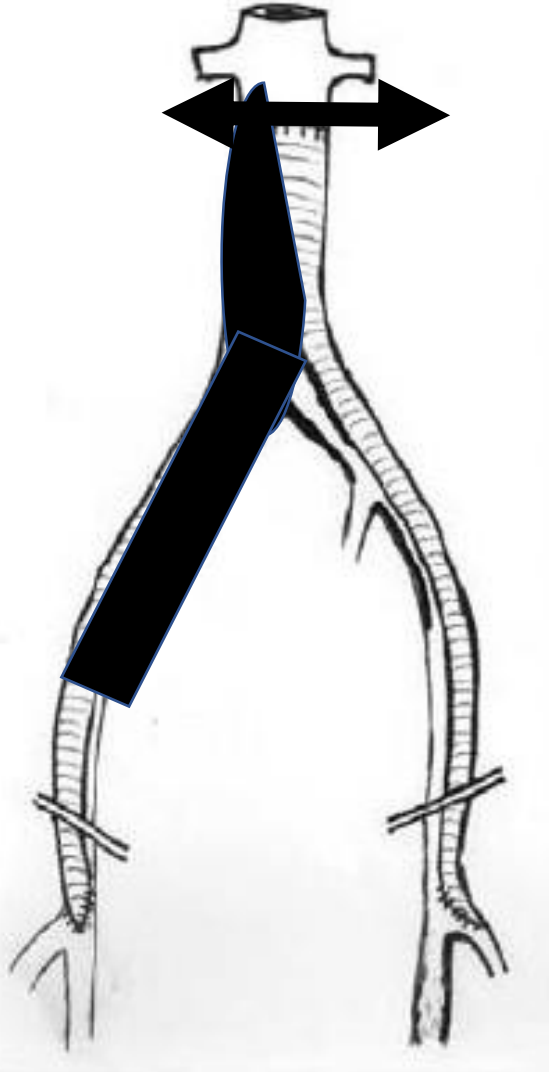
Surgical options



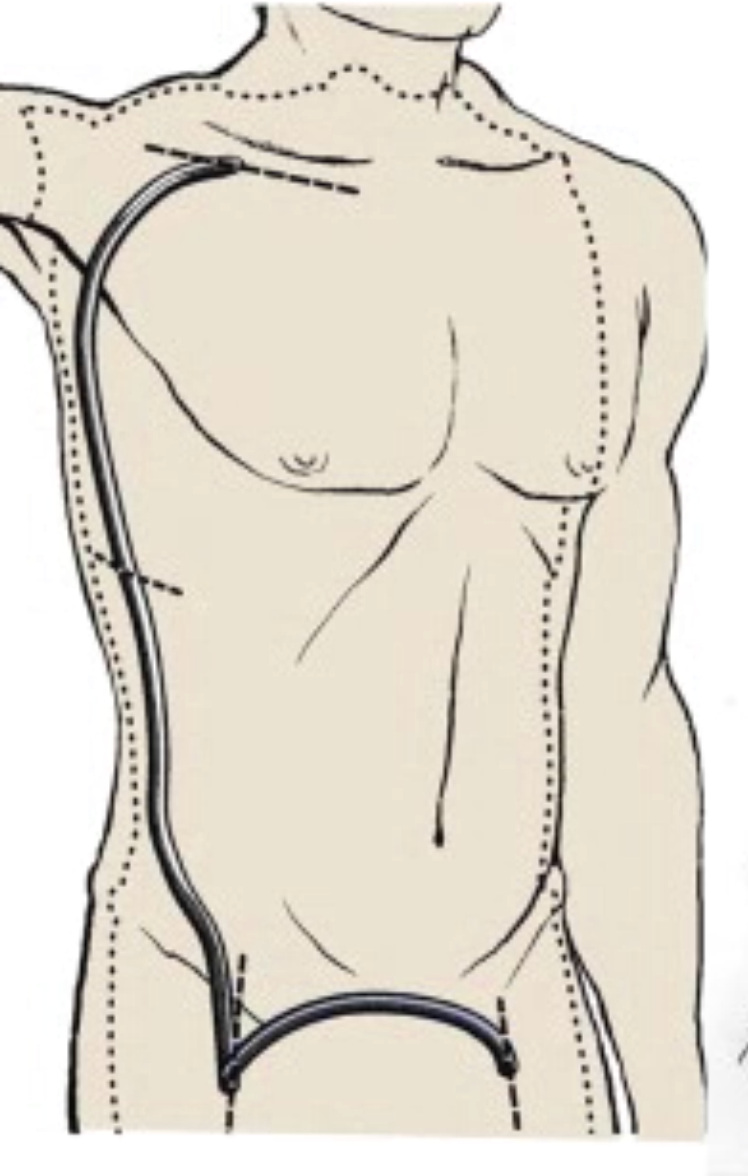
+

Crural Bypass

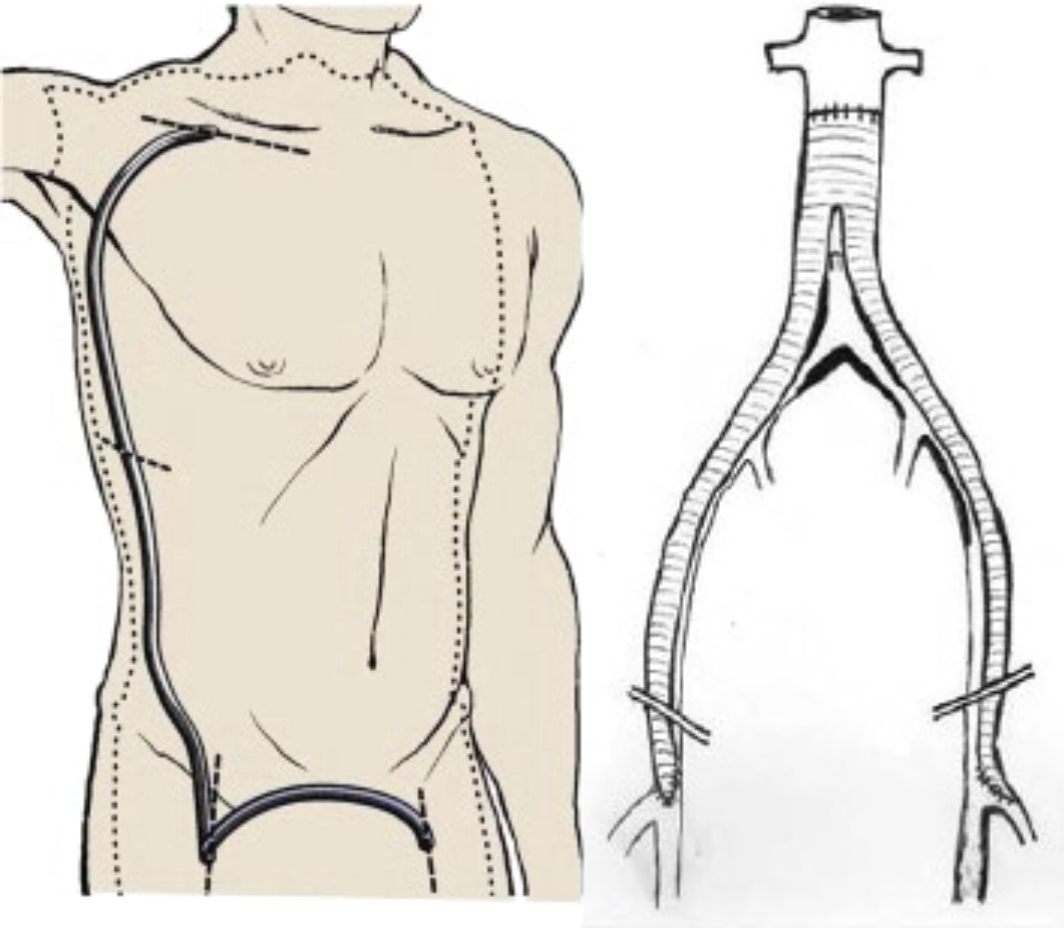
Surgical options



- Risk of thrombus embolization in the renovisceral vessels
- due to excessive thrombus formation in the entire infrarenal aorta



- Risk of early or late infection by limited compliance of the patient, poorer patency

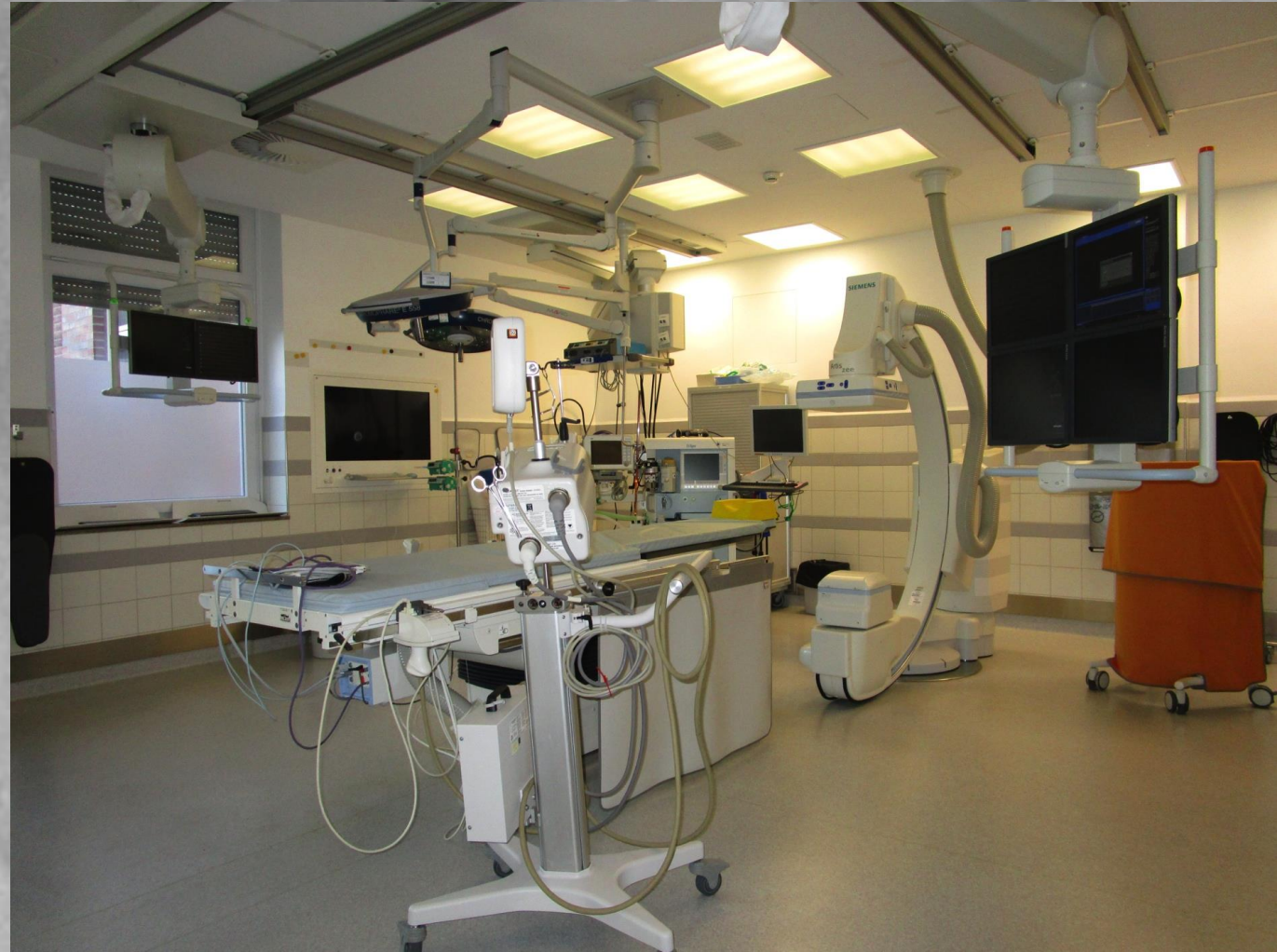

- Invasive procedures
- Prolonged operation time and length of hospital stay
- No other surgical options

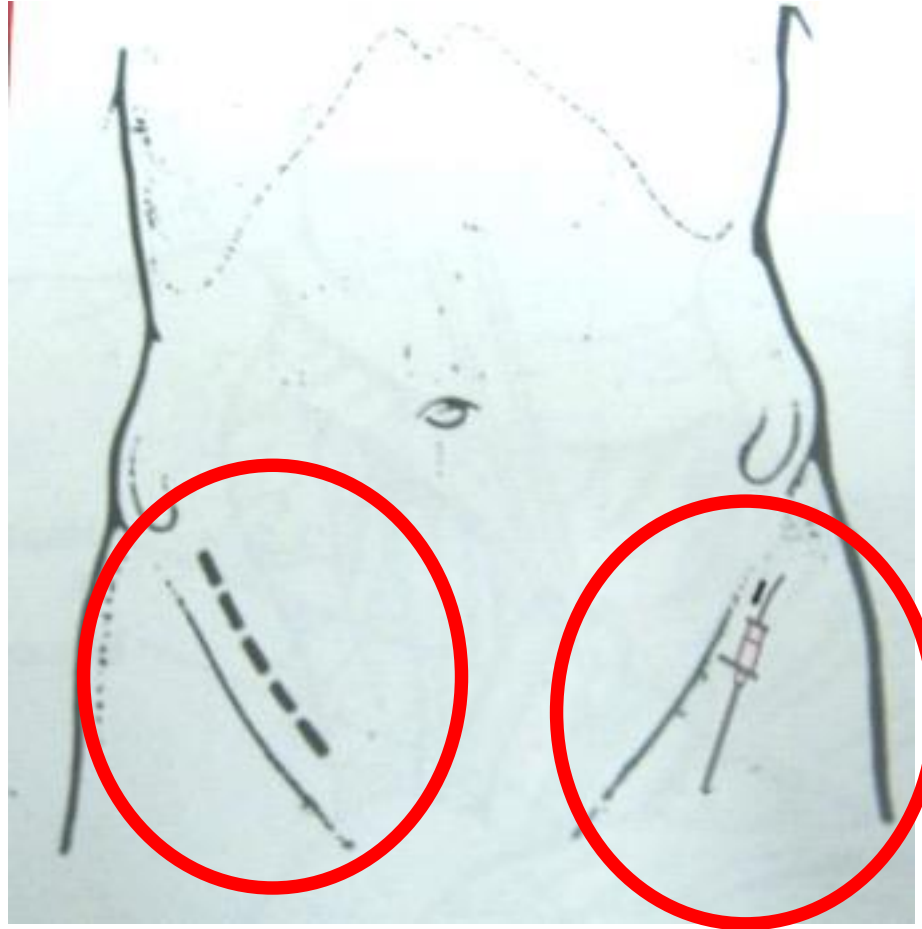


- Alternative?

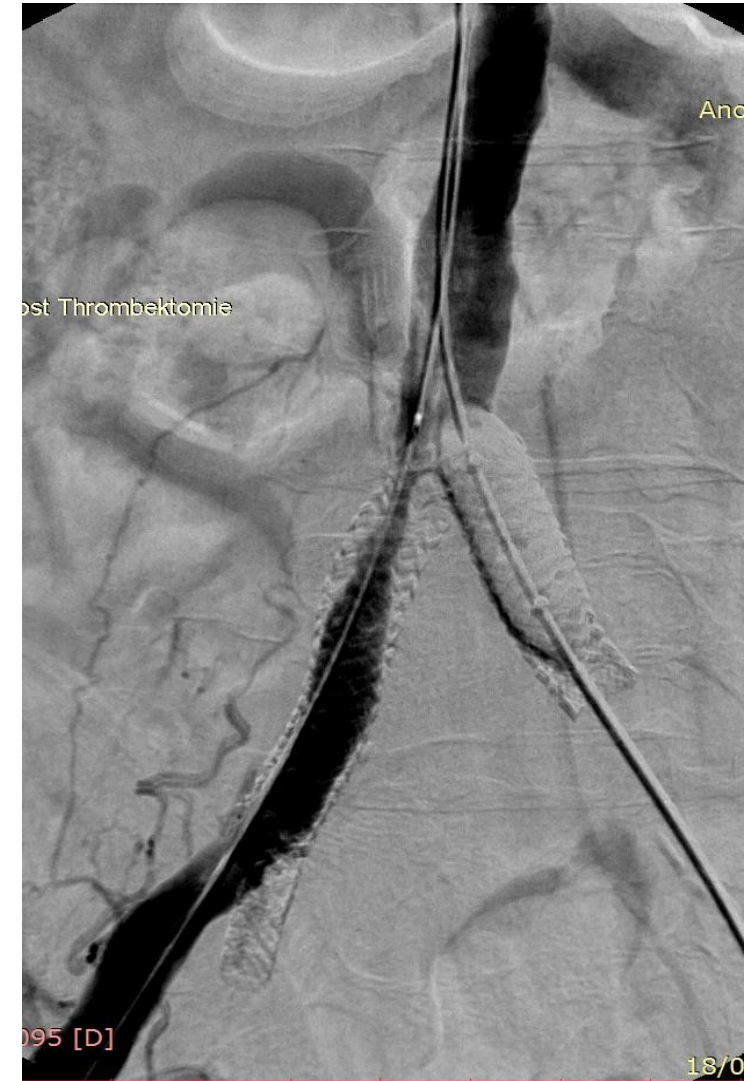
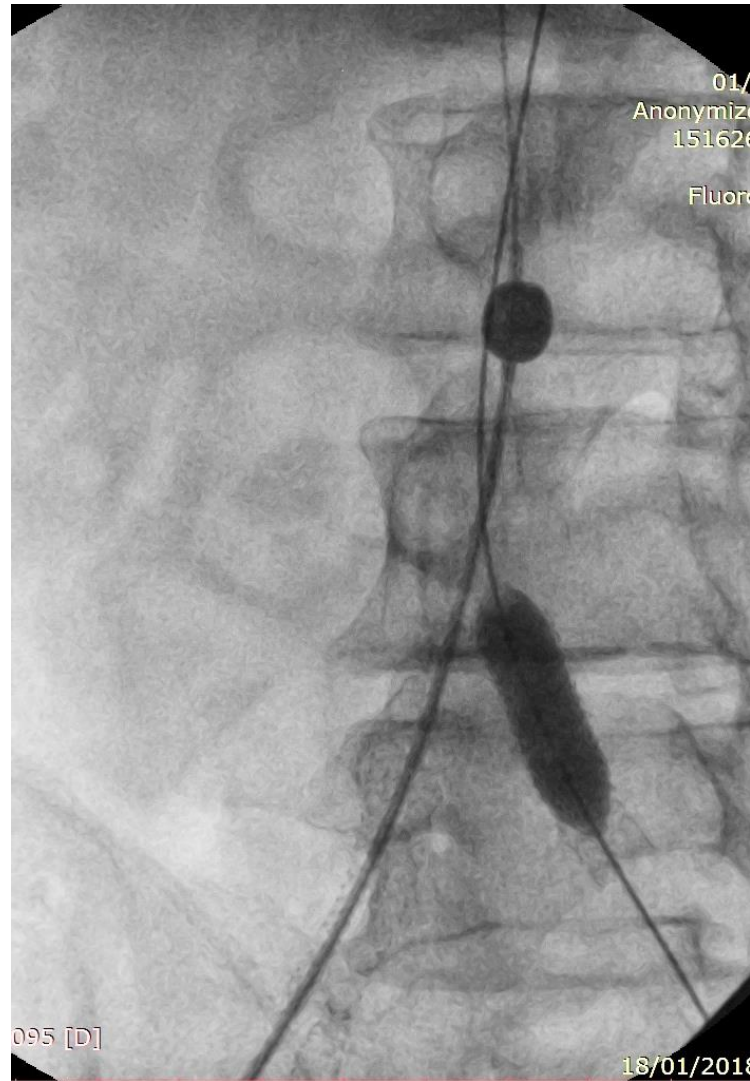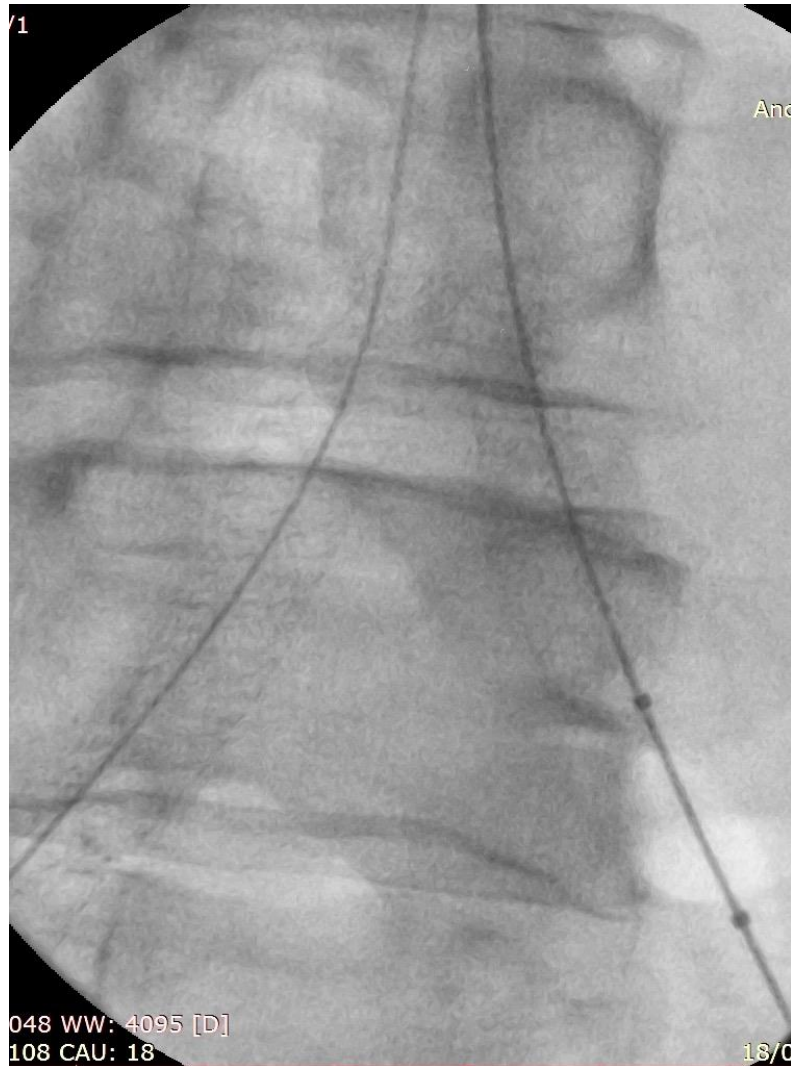
Combination of surgical and less invasive techniques



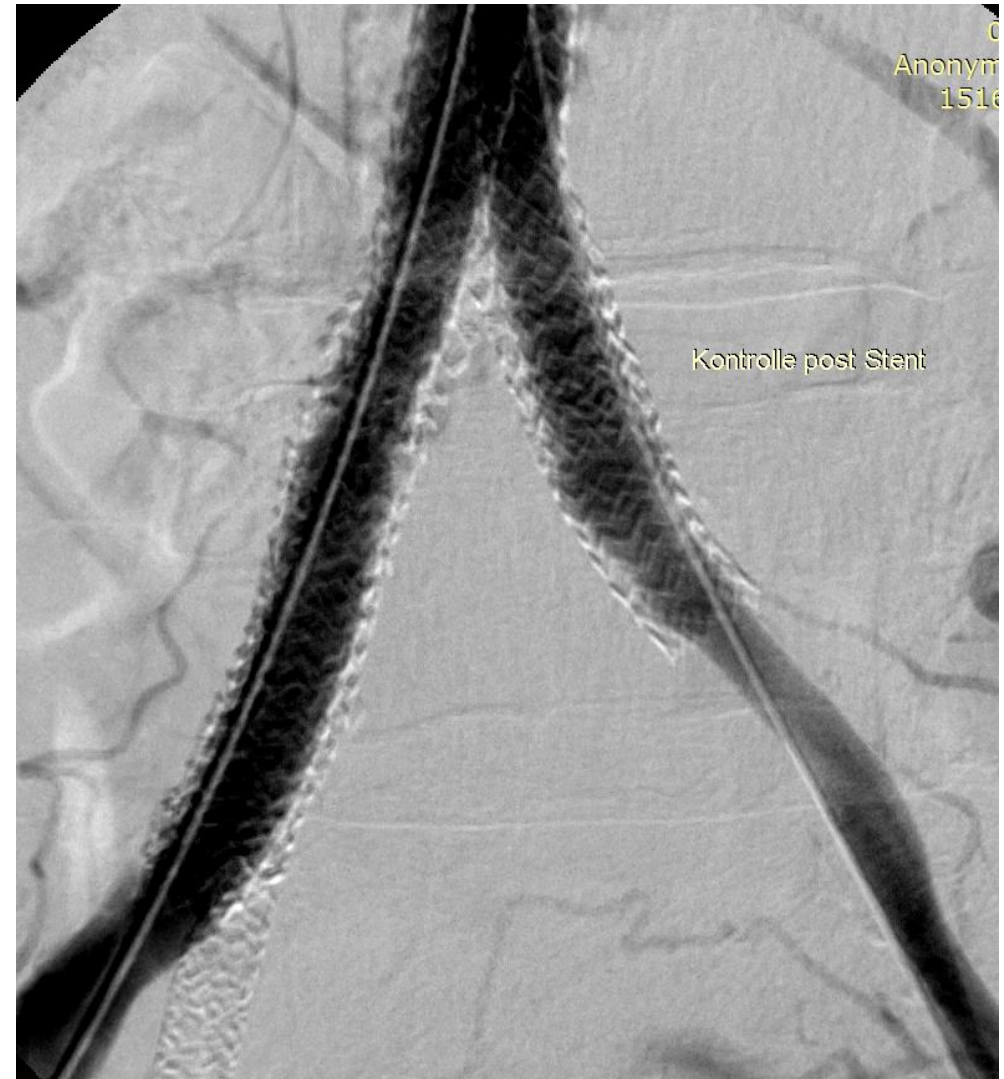
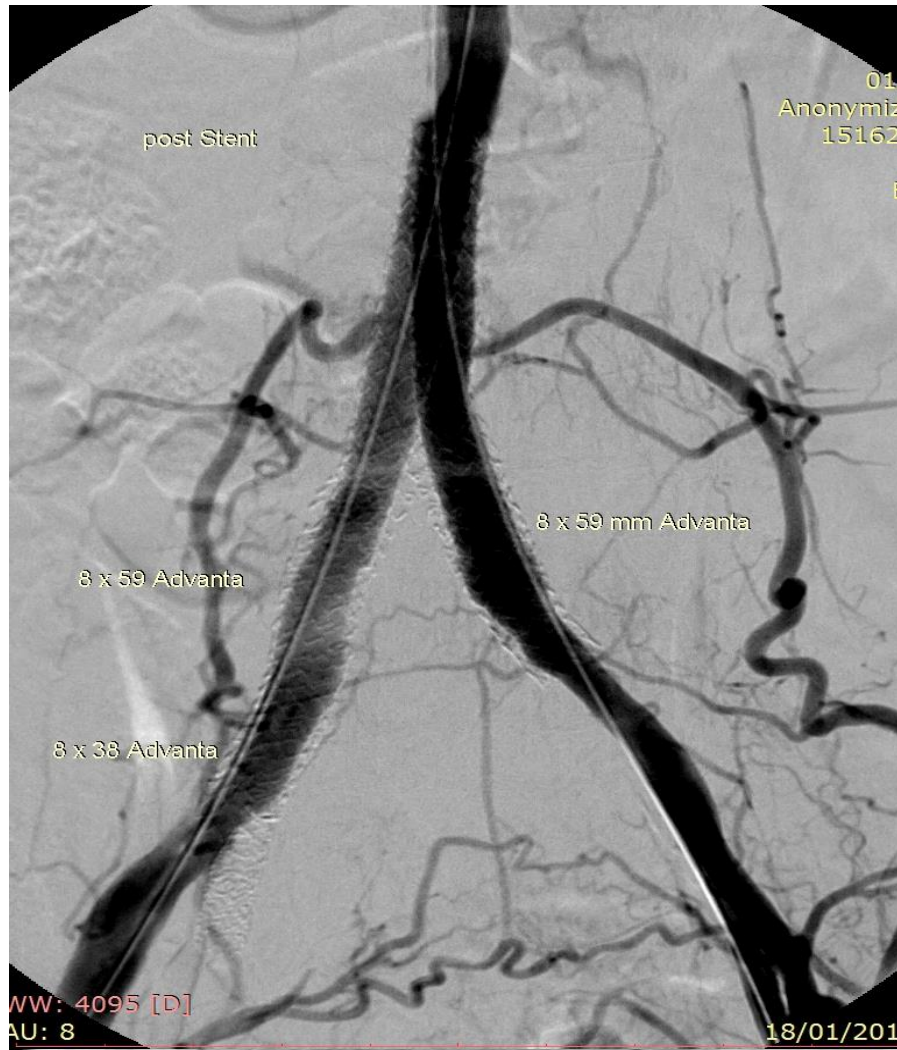Combined hybrid approach



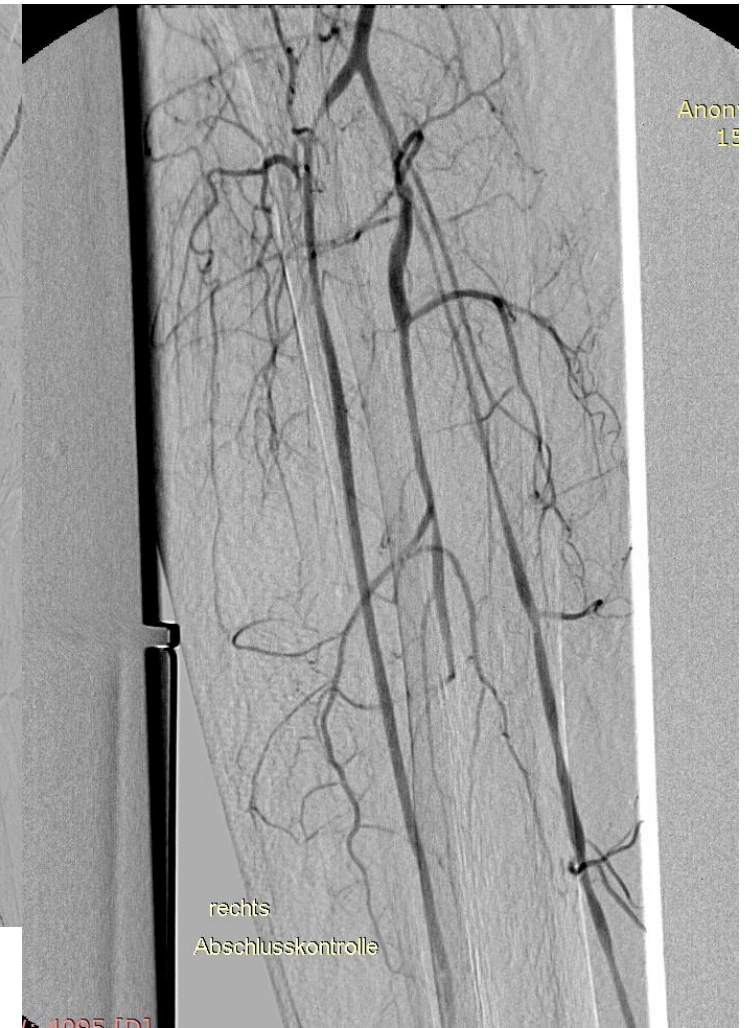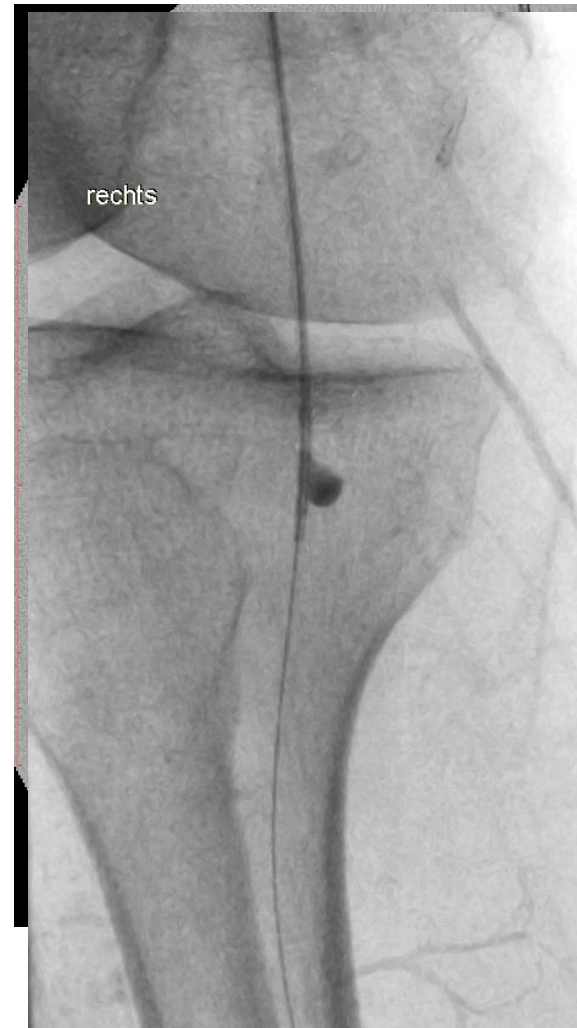
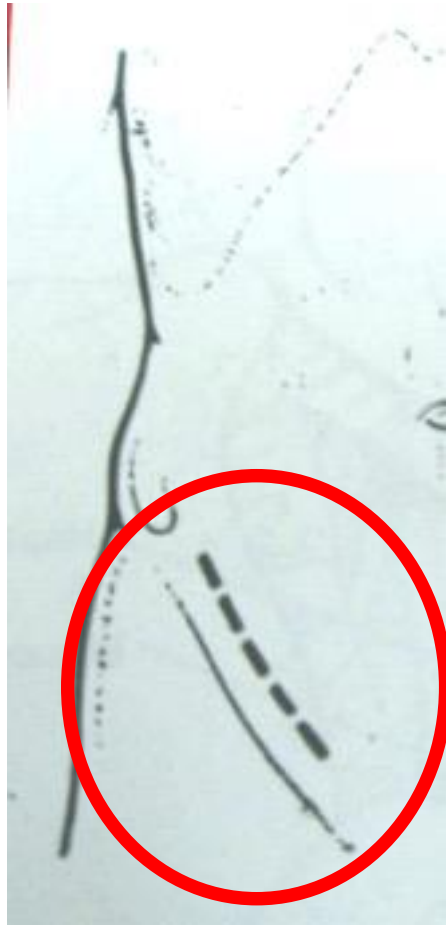Combined hybrid approach



Combined hybrid approach



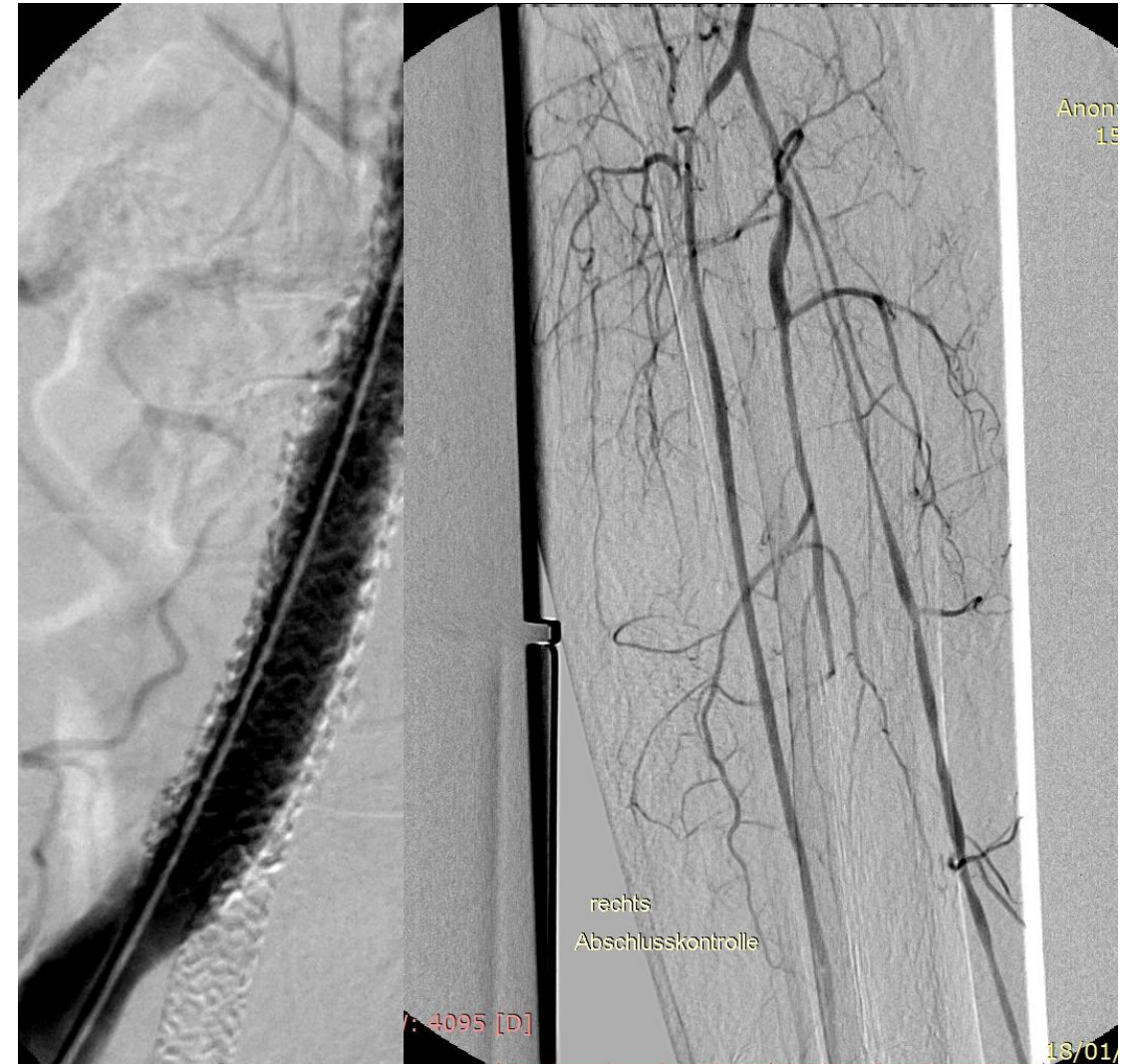Combined hybrid approach





Result

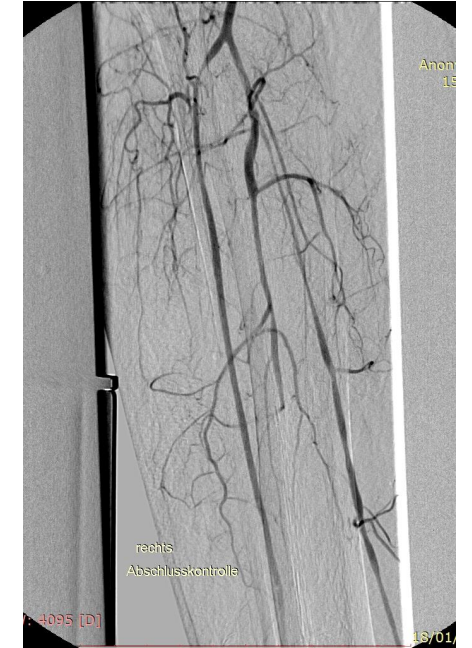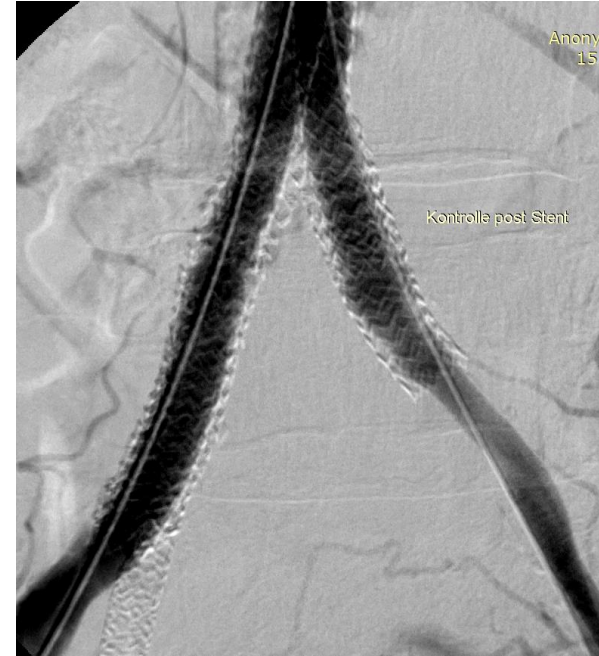- Palpable pulses of the limbs





Result

- Complete pulsstatus



- Discharge on the 18th of January