



CONTROVERSES ET ACTUALITÉS EN CHIRURGIE VASCULAIRE
**CONTROVERSIES & UPDATES
IN VASCULAR SURGERY**

CONTROVERSES ET ACTUALITÉS EN CHIRURGIE VASCULAIRE
CONTROVERSIES & UPDATES
IN VASCULAR SURGERY

FEBRUARY 7-9 2019

MARRIOTT RIVE GAUCHE & CONFERENCE CENTER
PARIS, FRANCE

WWW.CACVS.ORG



Open and Endovascular Treatment of Superior Vena Cava Syndrome of Benign Etiology

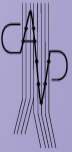George Geroulakos, Professor of Vascular Surgery

Chairman of Department of Vascular Surgery, Attikon University Hospital, Athens



Αγγειοχειρουργική Κλινική Ιατρικής Σχολής
Πανεπιστημίου Αθηνών Π.Γ.Ν. "Αττικόν"

Dept. of Vascular Surgery - University of Athens



Disclosure

Speaker name: **George Geroulakos**

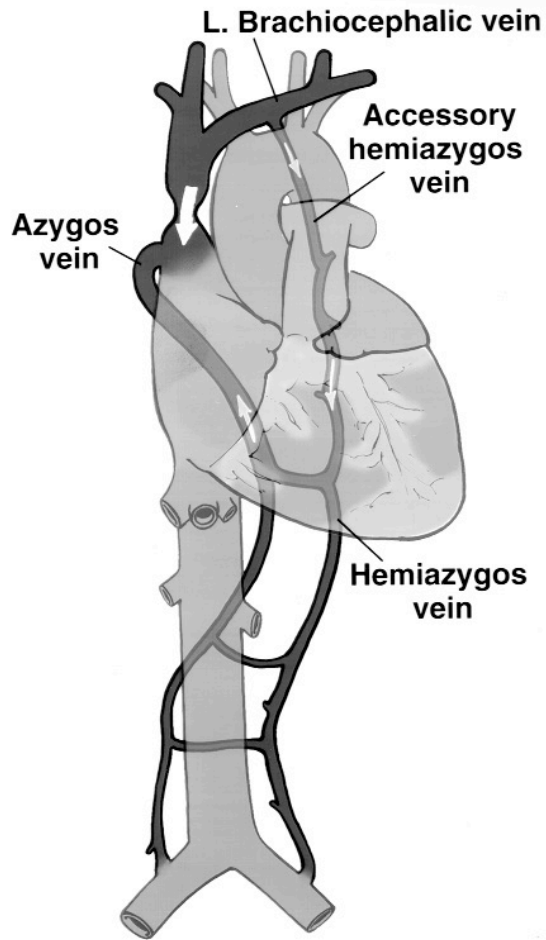
I have the following potential conflicts of interest to report:

- Consulting
- Employment in industry
- Shareholder in a healthcare company
- Owner of a healthcare company
- Other(s)
- I do not have any potential conflict of interest**

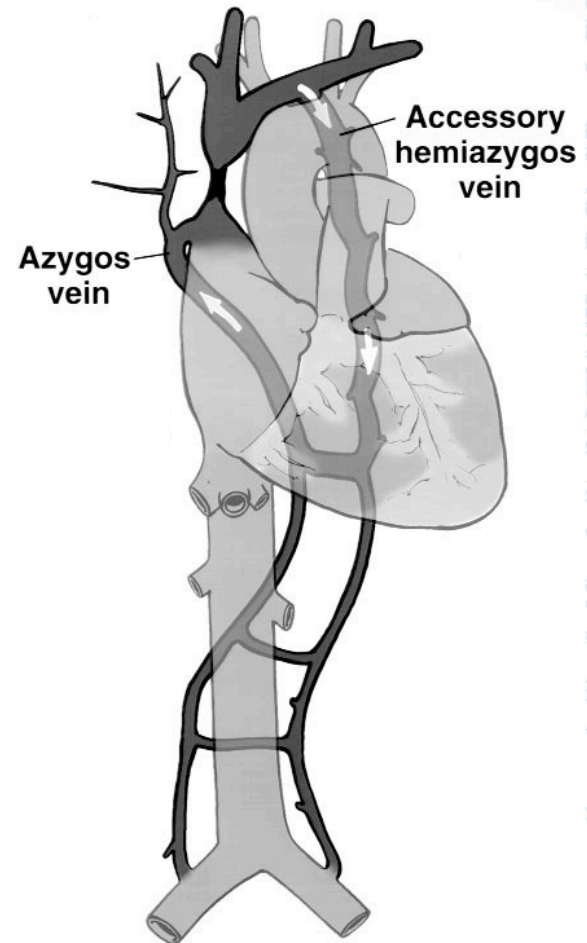
Background

- The increased use of central venous catheters, ports, pacemakers and defibrillators raised the incidence of benign superior vena cava syndrome (SVCS)
- 19.000 cases of SVCS occur every year in the United States
- Benign aetiologies may now comprise up to 40% of cases

Types of SVCS

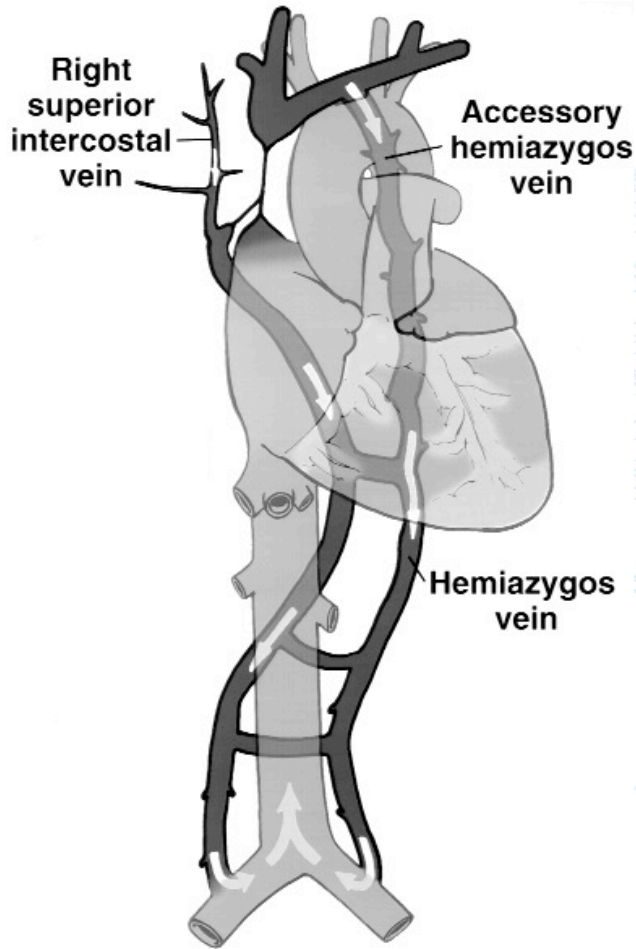


Type I

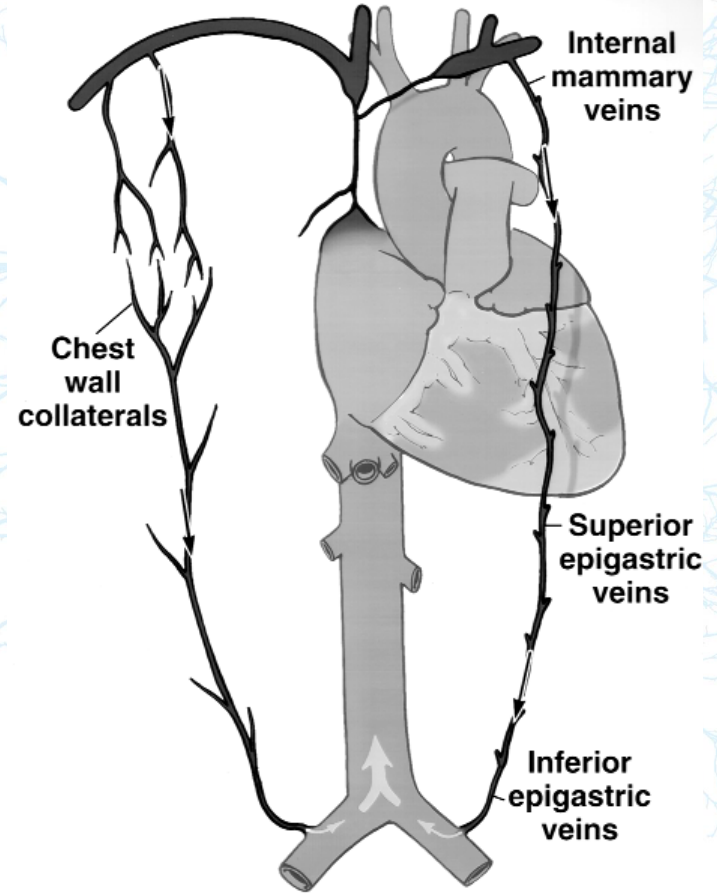


Type II

Types of SVCS



Type III



Type IV

Stanford W, Doty DB. The role of venography and surgery in the management of patients with superior vena cava obstruction. *Ann Thorac Surg* 1986;41:158-63.



Αγγειοχειρουργική Κλινική Ιατρικής Σχολής
Πανεπιστημίου Αθηνών Π.Γ.Ν. "Αττικόν"

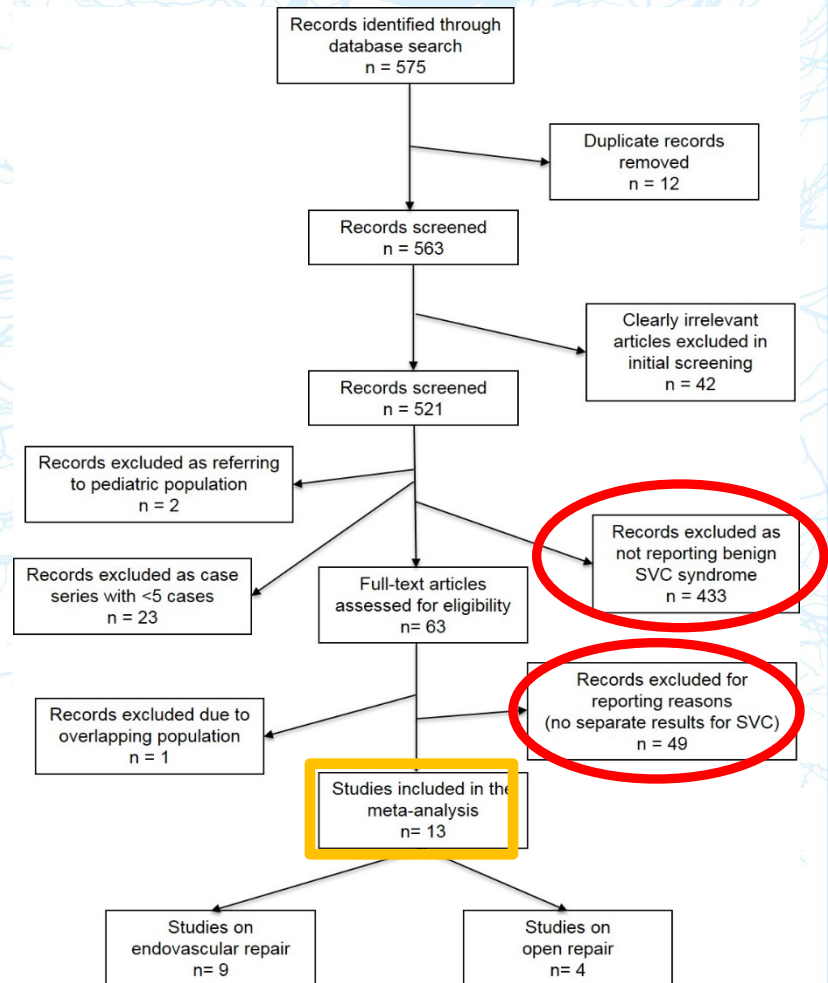
Dept. of Vascular Surgery - University of Athens

Open and Endovascular Treatment of SVCS of Benign Etiology

"endovascular"[All Fields] OR
"open"[All Fields]

AND "vena cava"[All Fields]

AND ("thrombosis"[All Fields]
OR "occlusion"[All Fields])



Endovascular Treatment of SVCS

- **9 studies (all retrospective): 136 patients**
 - **Central venous catheters and pacemakers 80.6%**
 - **Mediastinal fibrosis 13.7%**
 - **Other causes 5.6%**
 - Post radiation fibrosis
 - Benign tumor
 - Goiter
 - Transposition of the great vessels



Endovascular Treatment of SVCS

- **Risk Factors**

- History of DVT
- Neck irradiation
- Behcet disease
- Existing dialysis fistula on the side of pacemaker leads

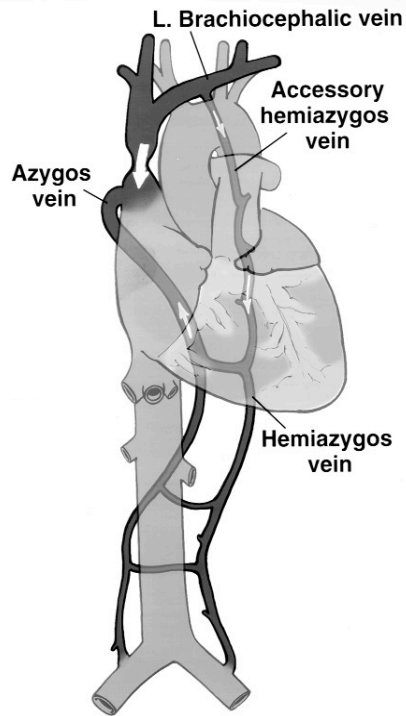
- **Diagnosis**

- Earlier venography
- Later CT venography or MR venography

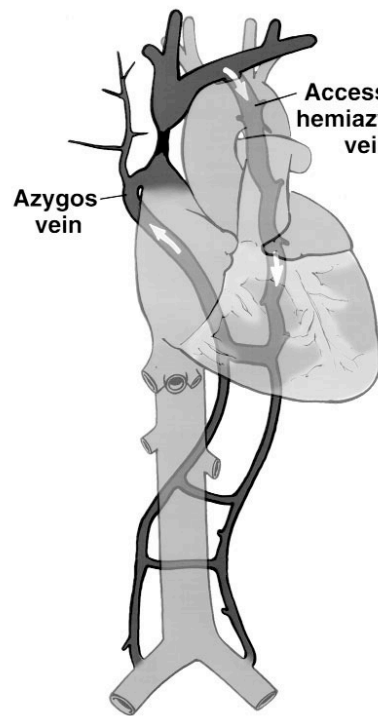


Endovascular Treatment of SVCS

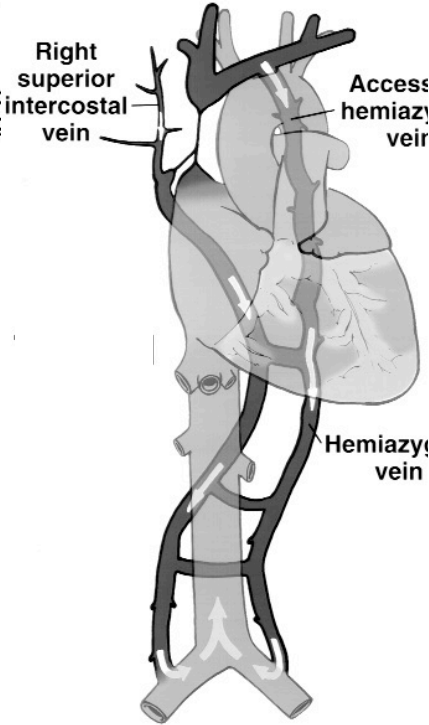
Types of SVCS



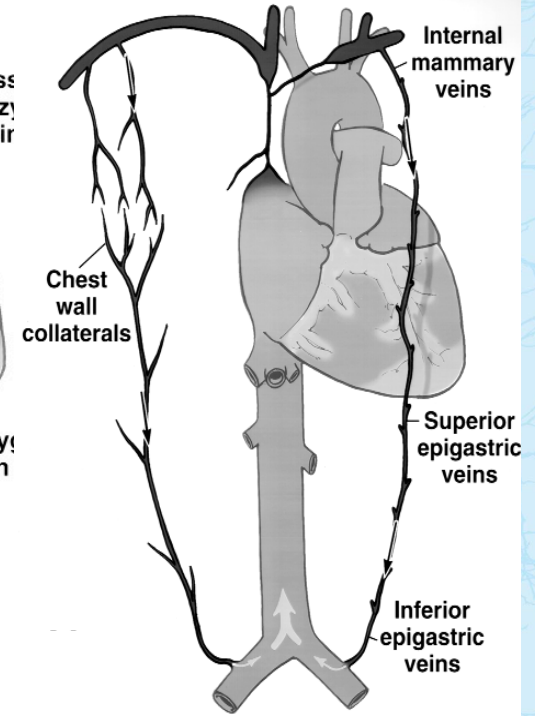
Type I
6.6%



Type II
37.7%



Type III
42.2%



Type IV
13.3%



Endovascular Treatment of SVCS

Technical success 95.6% (132/138)

- PTA + stenting 73.6%
- PTA 17.3%
- Thrombolysis, PTA and stenting 9%

Stents

Self expanding

- Wallstent (Boston Scientific) 53.7%
- S.M.A.R.T (Cordis) 8.7%
- Protégé (eV3 Inc) 5%
- Zilver (Cook), Luminexx (Bard) 1.2%

Balloon expandable

- Palmaz (Cordis) 20%
- Express LD (Boston Scientific) 2.5%
- Gianturco Z stent 1.2%

Covered stents

- Viabahn (W.L. Gore) 3.7%
- iCast (Atrium Maquet) 1.2%



Endovascular Treatment of SVCS

Pacemaker-Induced SVCS

Two Techniques

1. Lead removal, stent implantation, and reimplantation of new leads
2. Plain balloon dilatation of the vein with stent placement in selected cases

Endovascular Treatment of SVCS

Results

- 30- day mortality 0%
- Complications 3.6%
 - Stent migration (2 patients)
 - SVC penetration
 - Arm hematoma
 - 3rd degree heart block



Endovascular Treatment of SVCS

Results

- FU 11-48 months
- Regression of the symptoms: 97.3%
- Recurrence 32 pts (26.6%)
- 58 secondary procedures
 - 48 PTAs
 - 5 PTAs with stenting
 - 3 thrombolyses and
 - 2 bypass grafts



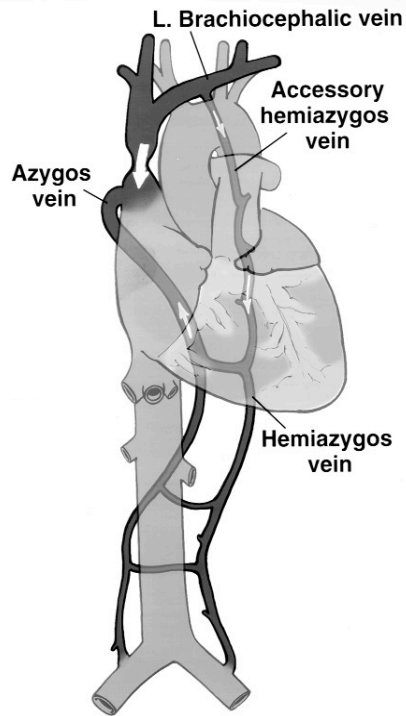
Open Surgical Reconstruction of SVCS

- **4 studies (all retrospective): 87 patients**
 - **Central venous catheters and pacemakers 28.5%**
 - **Mediastinal fibrosis 58.4%**
 - **Other causes 13%**
 - 5 idiopathic thromboses
 - 2 hypercoagulable state
 - 2 after ventriculoatrial shunts
 - 1 surgical excision

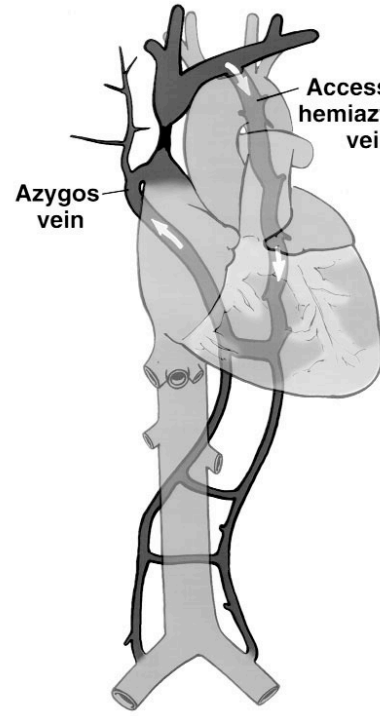


Open Surgical Reconstruction of SVCS

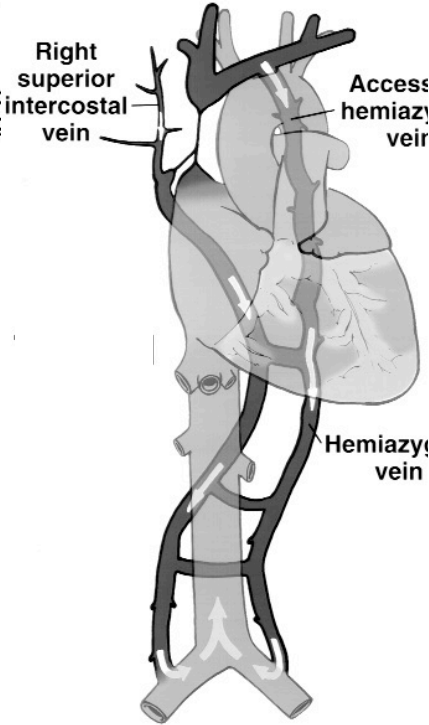
Types of SVCS



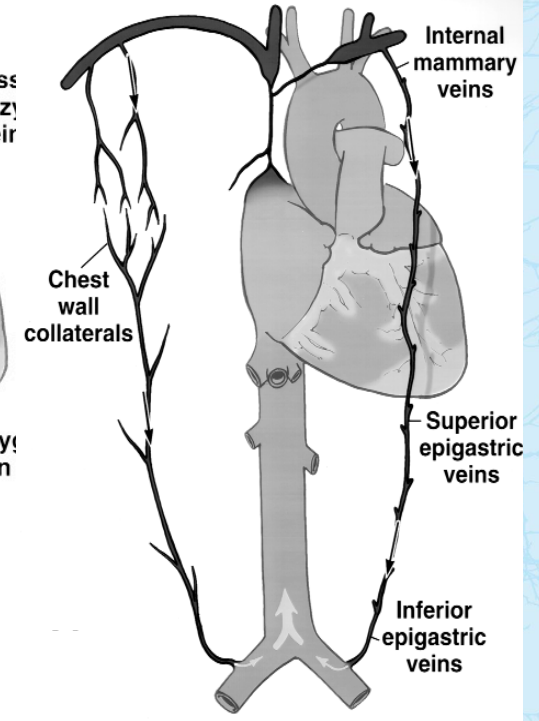
Type I
9.8%



Type II
11.5%



Type III
34.4%



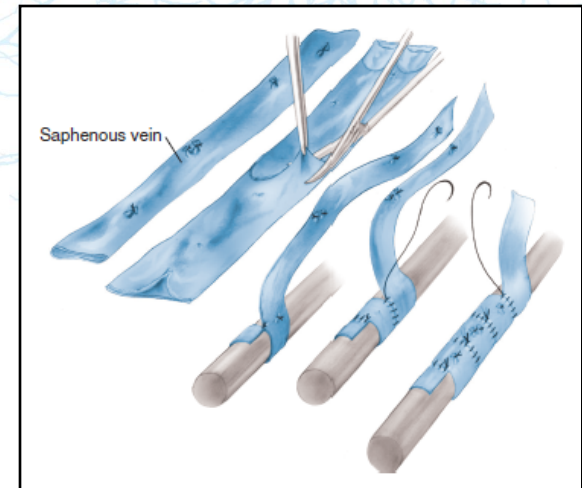
Type IV
44.2%

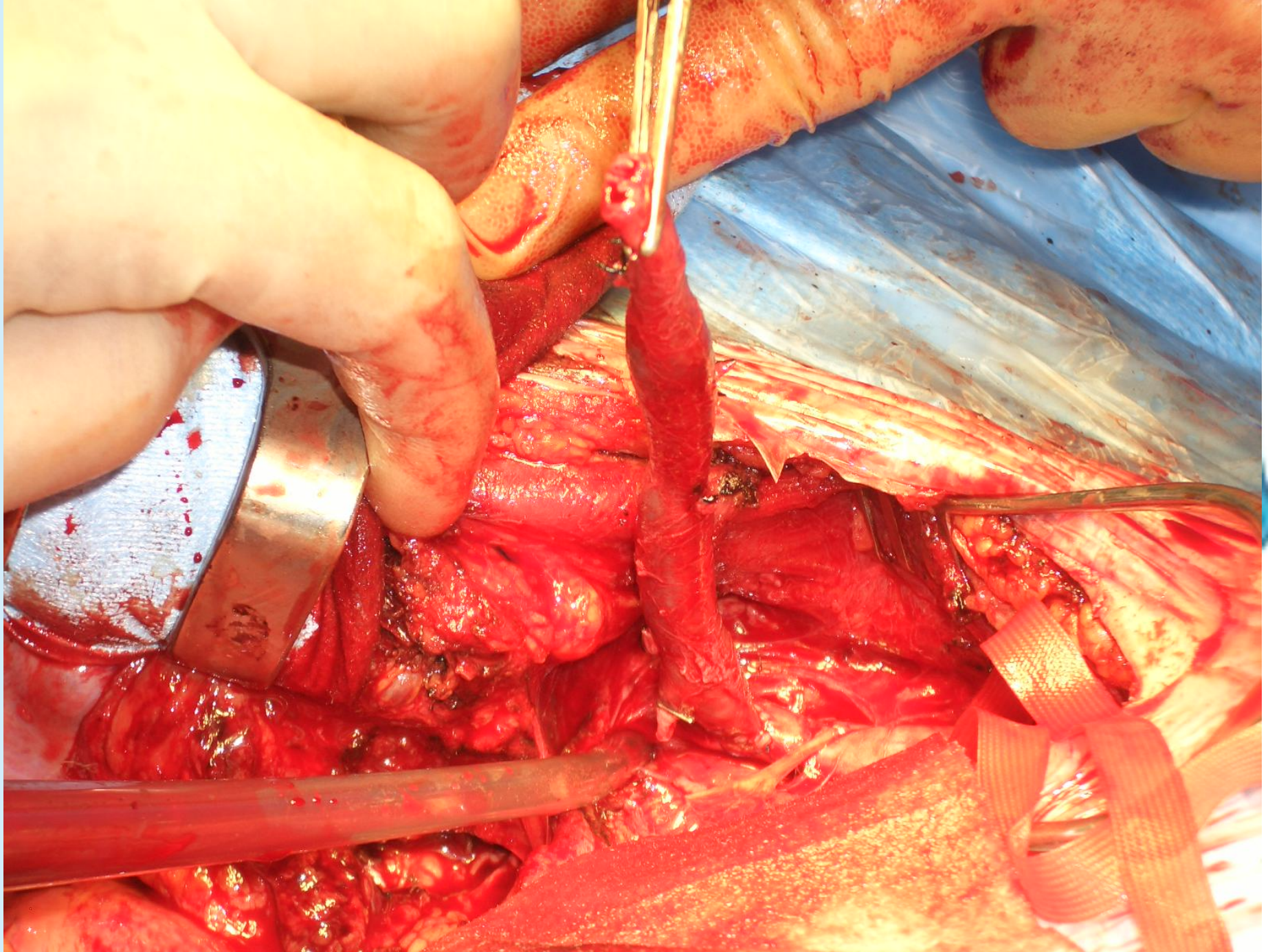


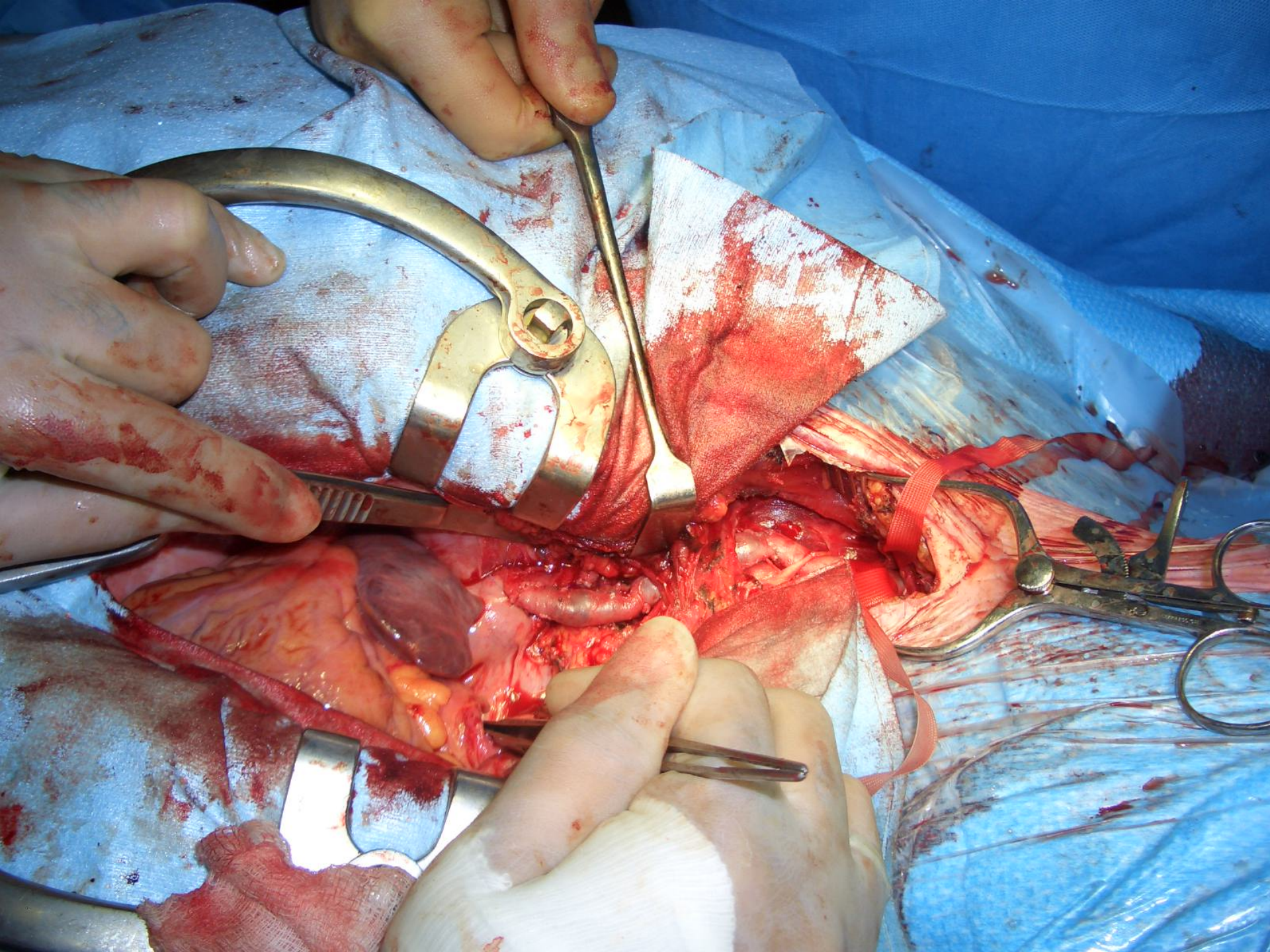
Open Surgical Reconstruction of SVCS

Type of graft

- **Spiral saphenous vein graft 59.7% (52/87)**
 - ✓ Straight (48/52): Innominate or Jugular vein to right atrial appendage
 - ✓ Bifurcated (4/52): Internal jugular vein and innominate vein to right atrial appendage
- **Externally reinforced ePTFE 26.4% (23/87)**
- **Femoral vein 6.8% (6/87)**
- **Human allograft 2.3% (2/87)**
- **Reversed saphenous vein 1.1% (1/87)**
- **Venous transposition 3.4% (3/87)**







Open Surgical Reconstruction of SVCS

Results

- 30- day mortality 0%
- 13 reoperations (15%) before discharge
 - 8 graft thrombosis
 - 3 stenoses of the graft
 - 2 patients with a mediastinal hematoma needing evacuation



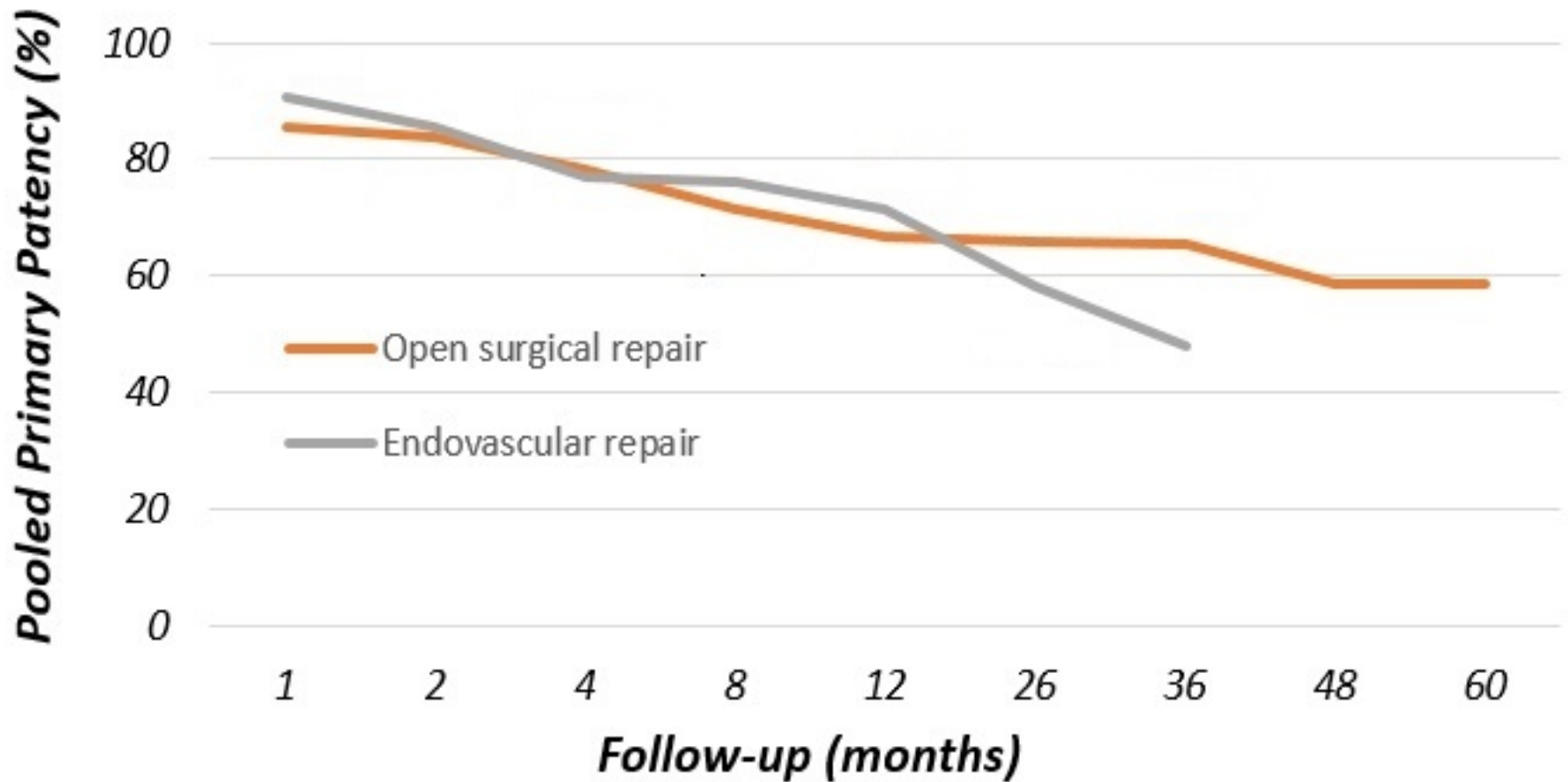
Open Surgical Reconstruction of SVCS

Results

- FU 30 m - 10.9 years
- Complete or partial regression of the symptoms: 93.5%
- Recurrence 24 pts (31.1%)
 - 33 secondary procedures
 - 10 PTAs
 - 11 PTAs with stenting
 - 9 thrombectomies
 - 2 graft replacements
 - 1 thrombolysis



Pooled primary patency after endovascular and open surgical repair for benign SVC syndrome



Conclusions

- Benign SVCS syndrome is now more common as the use of indwelling catheters for dialysis and cardiac therapy expands
- Both open and endovascular treatments show good results regarding regression of the symptoms
- Mid-term primary patency is similar with a significant incidence of secondary interventions



Conclusions

- Endovascular is the first line of treatment for SVCS caused by intravenous devices, while surgery is most often performed for mediastinal fibrosis
- Patients who underwent surgical treatment usually presented with more severe disease
- There is a high incidence of reoperations before discharge after surgery
- Secondary interventions after initial endovascular treatment or open surgery are mainly endovascular





Αγγειοχειρουργική Κλινική Ιατρικής Σχολής
Πανεπιστημίου Αθηνών Π.Γ.Ν. "Αττικόν"

Dept. of Vascular Surgery - University of Athens