

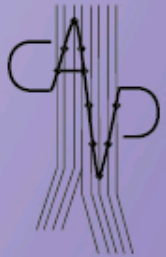


CONTROVERSES ET ACTUALITÉS EN CHIRURGIE VASCULAIRE
CONTROVERSIES & UPDATES
IN VASCULAR SURGERY

FEBRUARY 7-9 2019

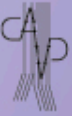MARRIOTT RIVE GAUCHE & CONFERENCE CENTER
PARIS, FRANCE

WWW.CACVS.ORG



USEFULNESS
of
VENA CAVA FILTER

G.FRANCO
CLINIQUE ARAGO
PARIS



Disclosure

Speaker name:

.....

- I have the following potential conflicts of interest to report:
 - Consulting
 - Employment in industry
 - Shareholder in a healthcare company
 - Owner of a healthcare company
 - Other(s)
- I do not have any potential conflict of interest

HISTORY

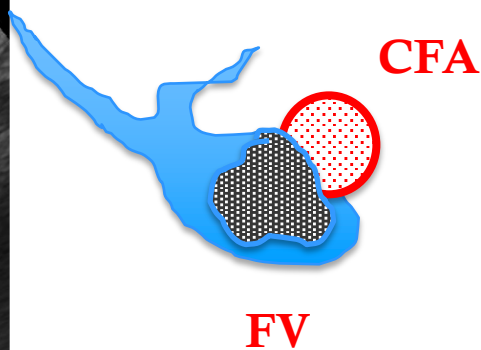
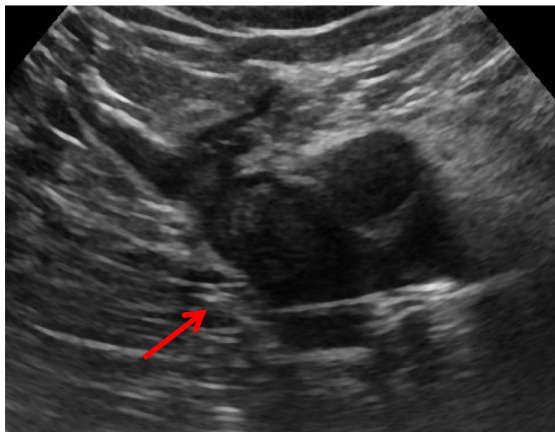
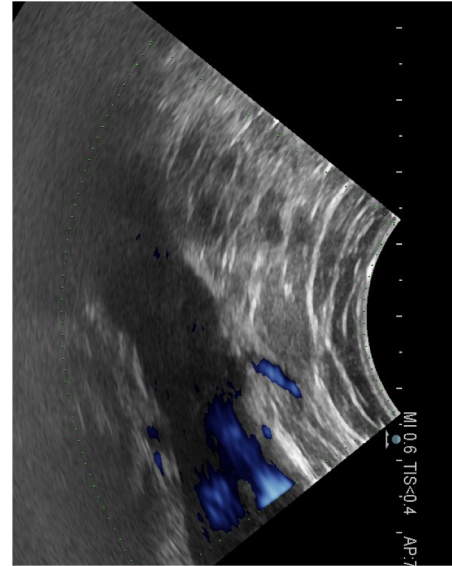
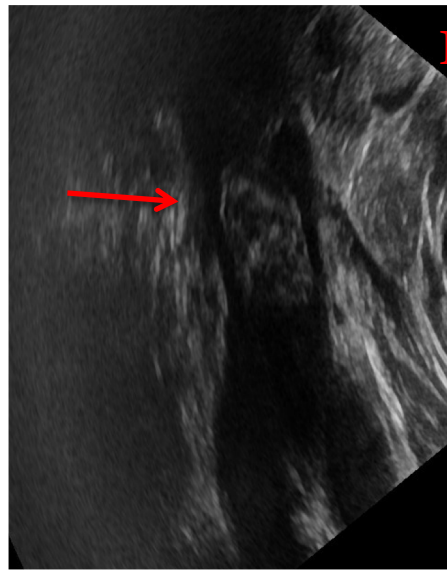
Mr Michel B :90 years old

Left Knee Replacement Surgery

DVT PREVENTION Low molecular weight heparin prevention :Tinzaparine 4500 UI

- Day 3:
- Pain Swelling
- Duplex-Scan:
- Bilateral DVT:
 - Left Femoral Vein thrombosis with long floating clot
 - Right Femoral Vein and Popliteal Vein thrombosis

LEFT FEMORAL THROMBOSIS with FLOTTING CLOT



Treatment Tinzaparine 14 000 UI Anti-Xa/0,7 mL

Treatment Tinzaparine 14 000 UI Anti-Xa/0,7 mL

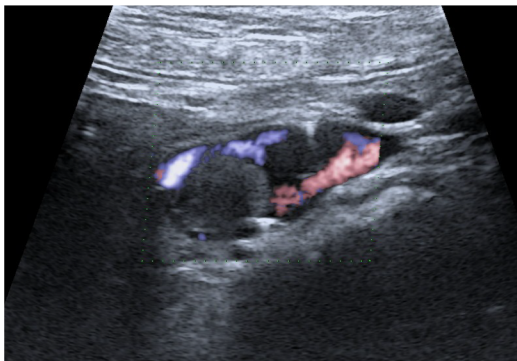
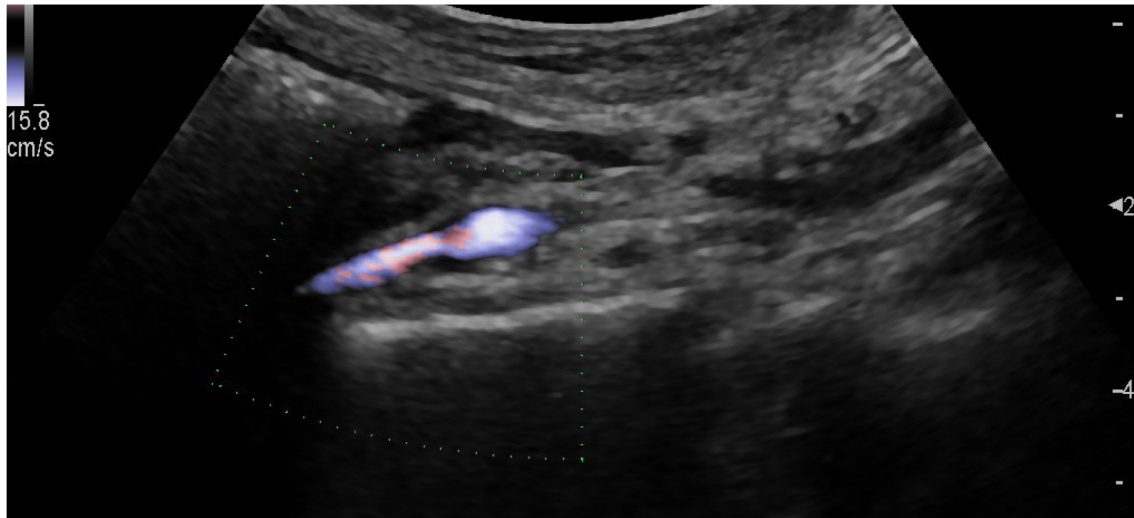
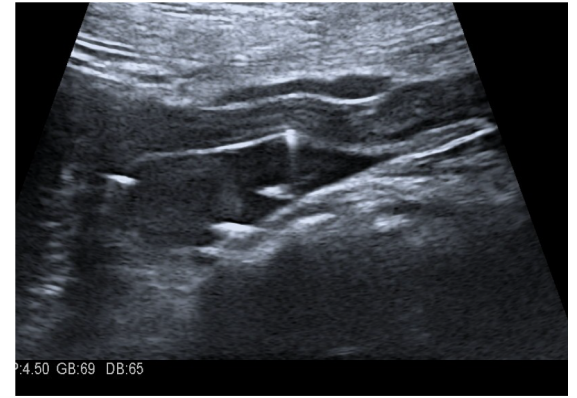
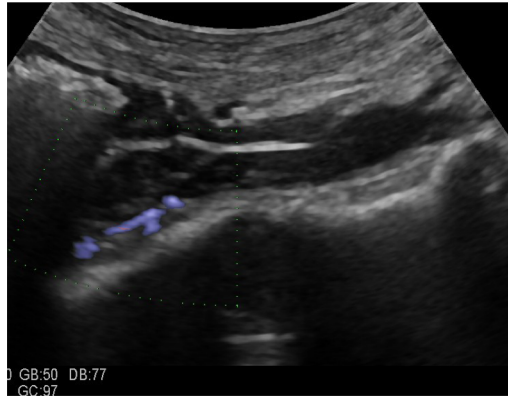
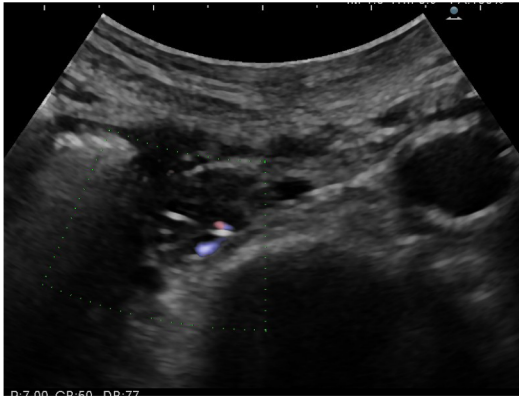
Day 7:

- **Severe active gastro-intestinal bleeding**

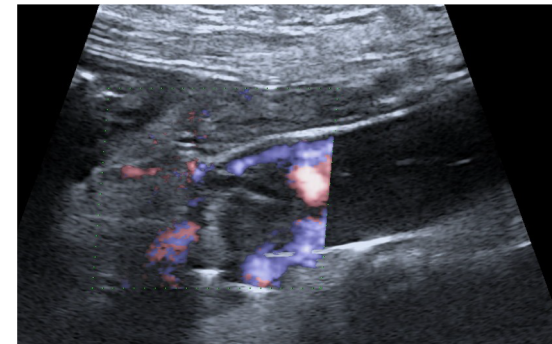
Hematocrit 35%

Hemoglobin:7g

- **Stop LMWH**
- **IVC Retrievable Filter Placement**



**D 10 :Control
INFERIOR VENA CAVA
CLOT TRAPPED BY THE FILTER**



THANK YOU Mr GREENFIELD

Inferior vena cava (IVC) filter

