

# Posterior Tibial Vein Ablation

- R.Milleret – Cluj Napoca -
- I am consultant and shareholder of Miravas .

# The TIVA Technique

## TIBIAL VEIN ABLATION

PRINCIPLE : there are 2 Posterior Tibial veins. In some patients , one is dilated and refluxing , the other is normal.

Thus the diseased trunk can be closed to help healing a post-thrombotic ulcers .

# Clinical presentation

- DVT secondary to a trauma ,
- Often no preventive treatment
- Diagnosis not done at the time of occurrence
- \* Associated lipodermatosclerosis

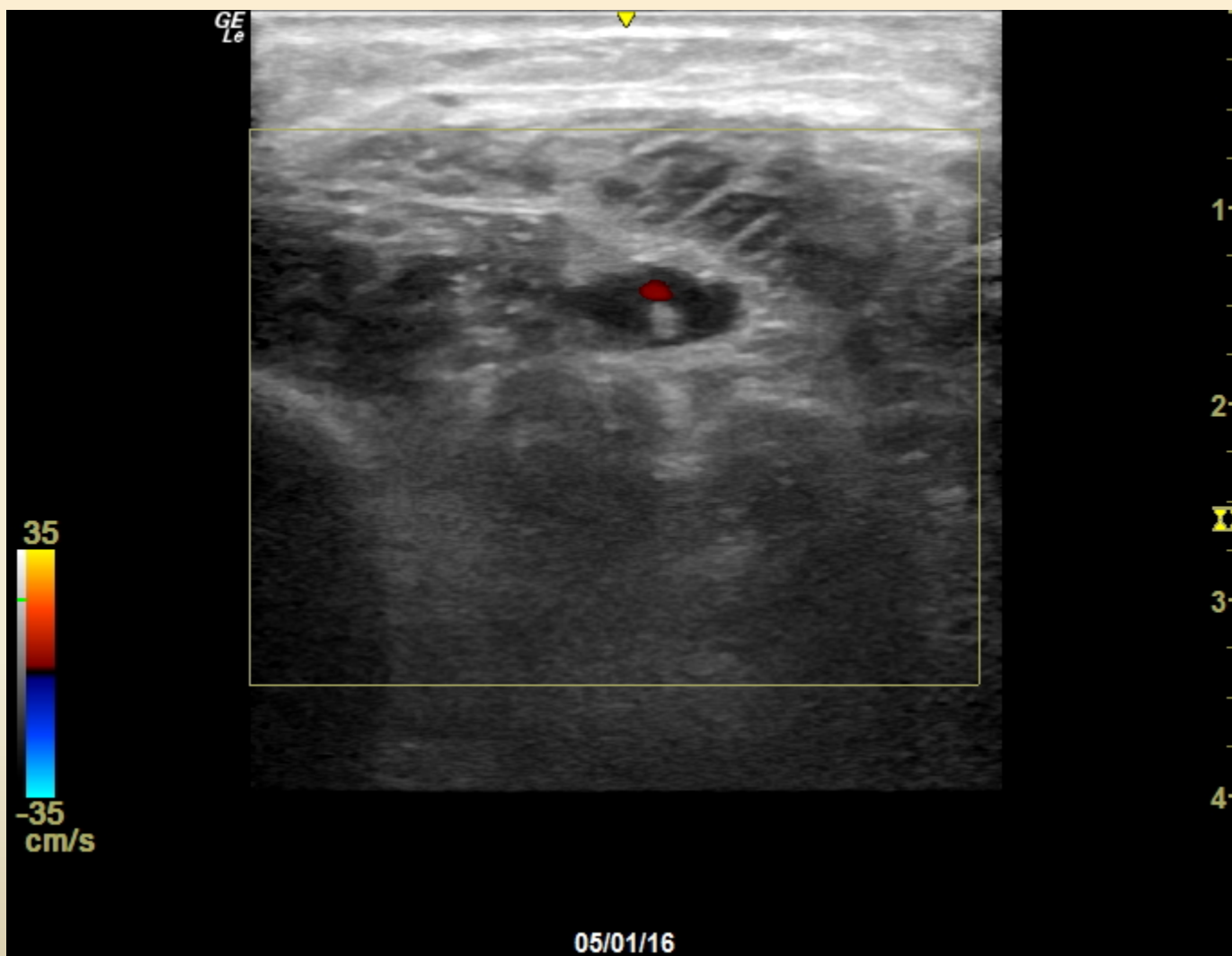
# Technique of TIVA

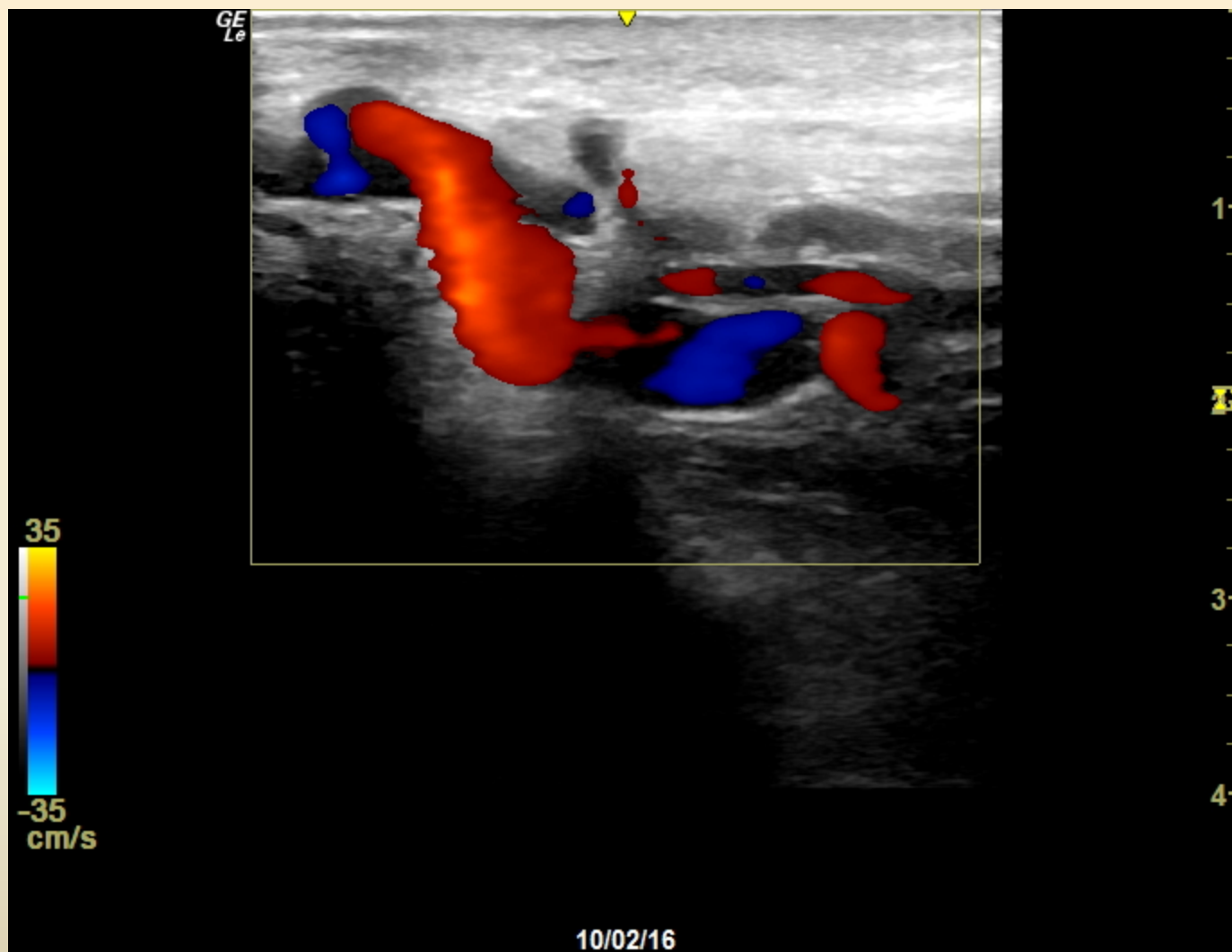- . Echo guided puncture at lower leg level or Popliteal vein if patent .
- Introducer Cook 3 F
- Injection of coils 6 to 8 mm diameter
- Steam injection of 300 joules.
- .

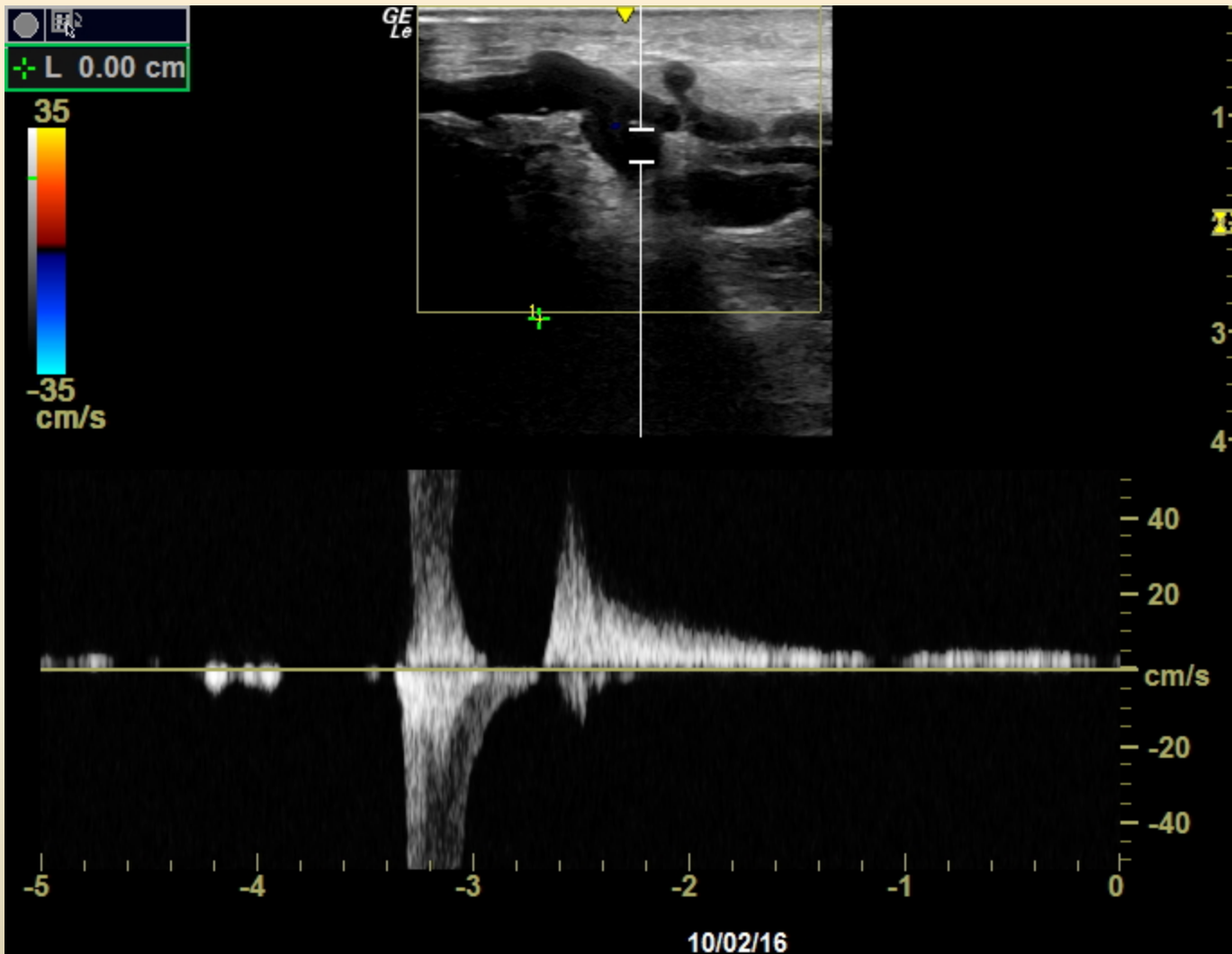
# Why not foam ?

- . Direct foam injection in a deep vein could lead to extensive DVT in these often thrombophilic patients .

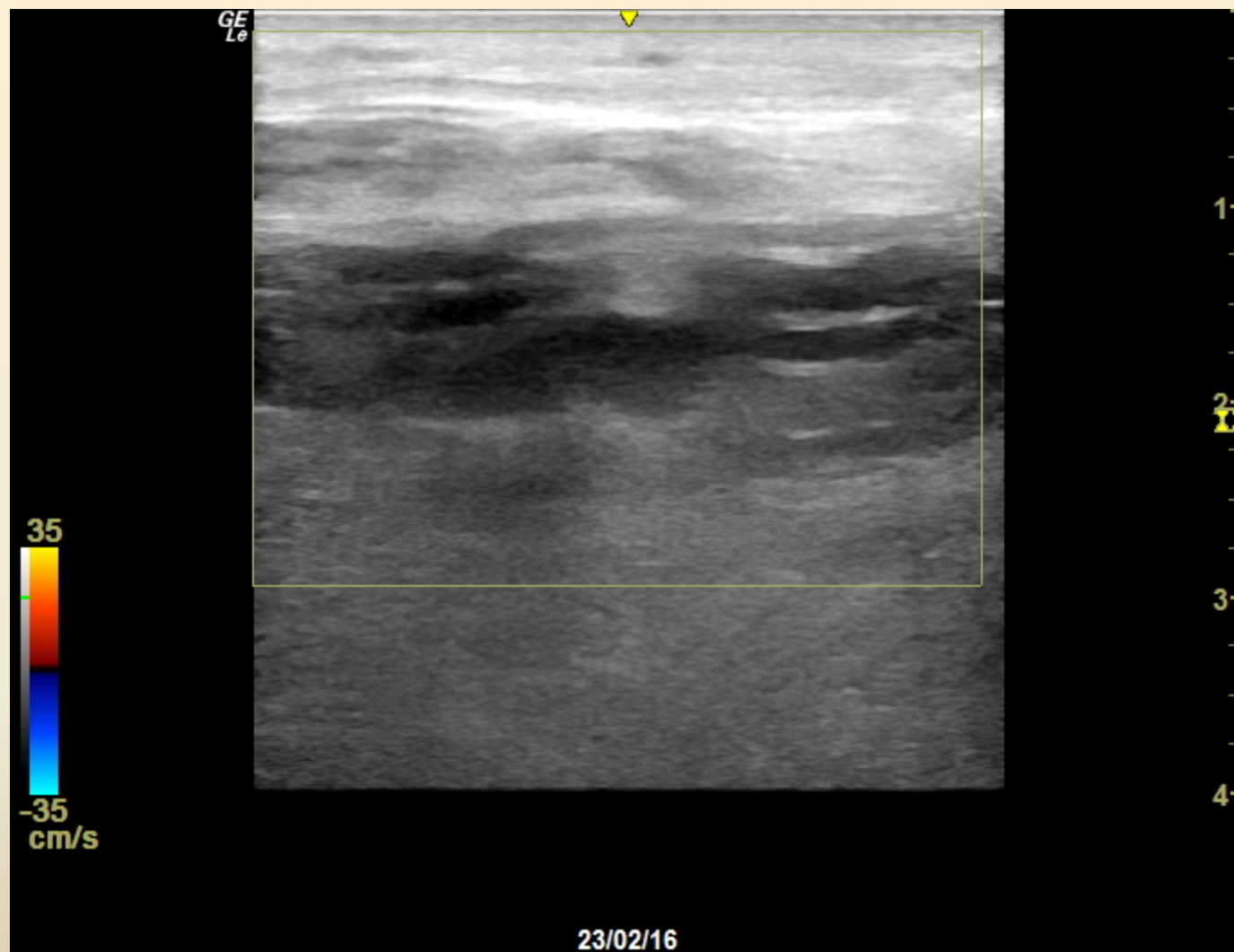
We have no experience of glue in the deep System , and it's not validated .

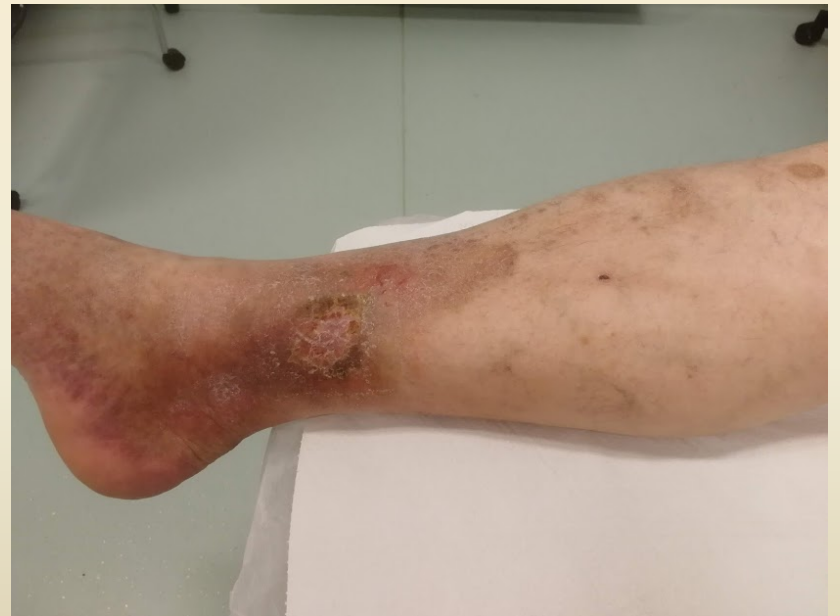
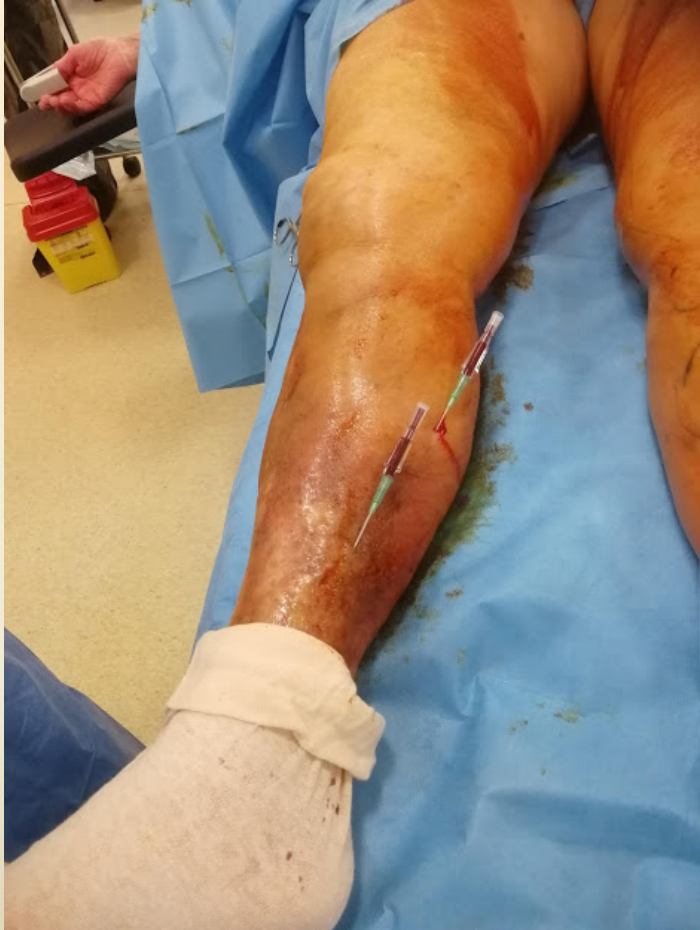










# Preliminary Results

- 6 patients treated 2016/2018
- All with post-thrombotic syndrom ,  
Ankle pressure index more than 0,8
- \* No diabetes .
- All ulcers healed in 3 to 10 weeks
- 1 recurrence at 2 years .

# Advantages

- All the perforators entering the Post Tibial vein directly or indirectly are closed .
- No puncture or incision close to the ulcer
- Orthostatic pressure is no more transmitted to the ulcer area .

# Conclusion

- In selected patients with recurrent chronic ulcers , ablation of a dilated Refluxing Posterior Tibial Vein may allow healing of the lesion .
- \* Long term follow up is not yet available .