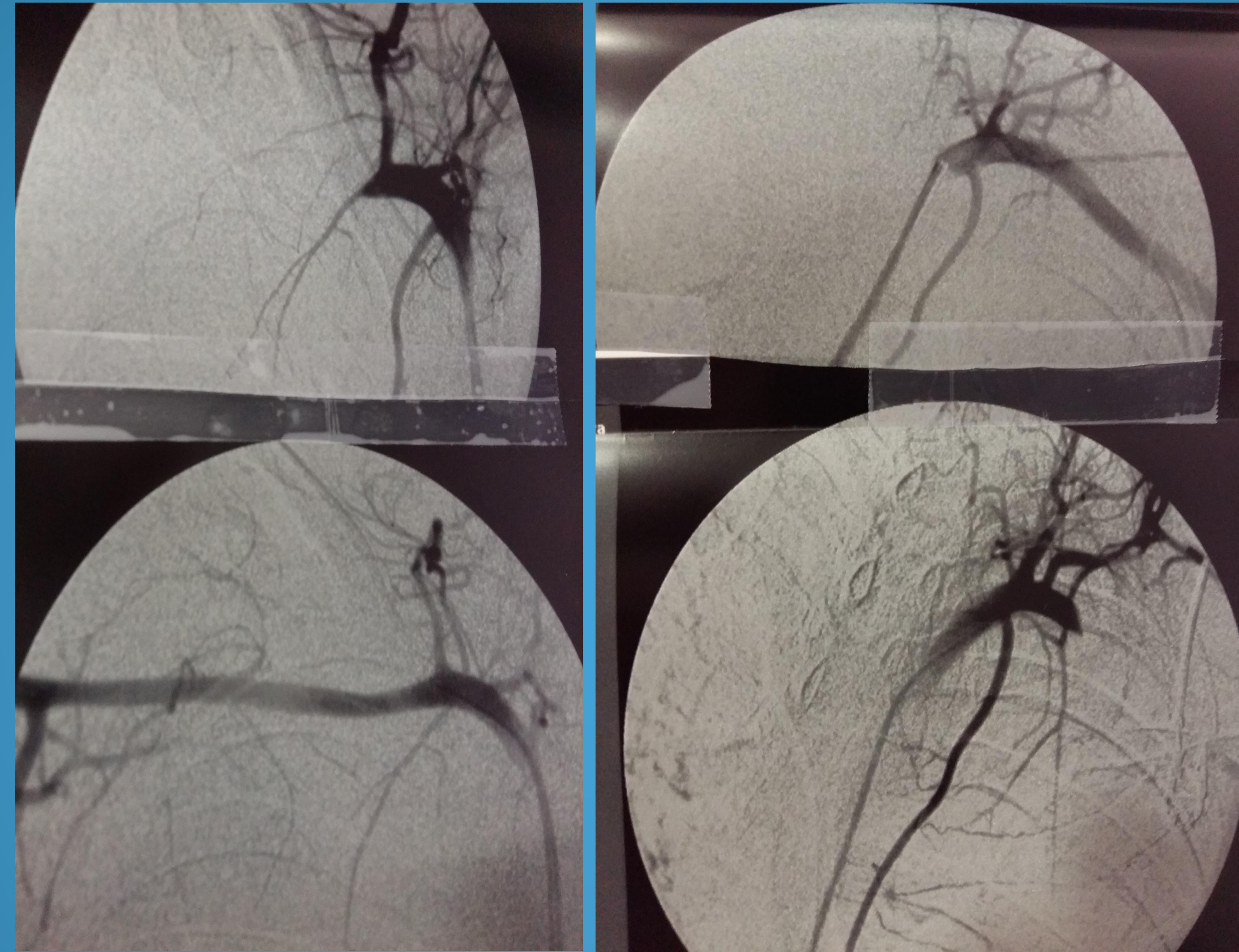


PERSONAL EXPERIENCE 73 CASES THORACO-BRACHIAL SYNDROME



Category of the population: Painter, clean glass, motocross, judo player, wearer, plaquistes...
Neurologic symp. 70%
Artrial signs and symp. 70%.
Veins signs 20% thrombophlebitis, edema
Composite signes 65%.
Dignostic plane: clinics , EMG, addison test, angioscanner
Neurologic syndrome is the most difficult to diagnose.
Specially angiodynamic exam see pictures
15 % patients had vascular complications, as art. dissection vinous thromboses, strong pains.
Indication: complicated cases and/or personnel or professional handicap.

Treatment: Axillary 1st rib resection.
Results: no died, or neurovascular injuries
4 pneumothorax drained by the same incision discharged 2 to 4 days.
Post operation: Painless sholder 70%, residual pain shoulder 30% with full recovery 2 weeks to 2 months.
re-education swimming.

Conclusion: think about it, good clinic and para clinic exam, my favorit is dynamic angiography exam.
Be sure of the dignostic specialy when neurologic syndrome.
Treat only when complicated cases, personal impairment or Professional handicap patients.