



SINUS-PRESERVING CAROTID ENDARTERECTOMY

Juan Antonio Celi de la Torre ¹, Roman V. Vinogradov ², Denis A. Skrypnik ²

¹ Faculty of Medicine, University of Heidelberg, Germany

² Regional Hospital N°1 of Krasnodar & Kuban State Medical University, Krasnodar, Russian Federation

Background

Blood pressure instability after carotid endarterectomy is a known risk factor for perioperative morbidity and mortality. The loss of the ipsilateral baroreceptor apparatus due to surgical incision during eversion carotid endarterectomy partly impairs the baroreflex response mechanism to elevated blood pressure, elevated heart rate and blood pressure variability. An affected baroreflex was linked to increased cardiovascular mortality. The sinus-preserving carotid endarterectomy is presented as a patch-free alternative to the classic eversion technique.

Objectives

To outline a sinus-preserving carotid endarterectomy surgical method, focusing on the operative technique and perioperative diagnostics, as well as to propose appropriate patient selection criteria.

Methods

Presentation of the patient selection criteria, perioperative diagnostics, as well as videographic and photographic step-by-step demonstration of the surgical technique.

Results

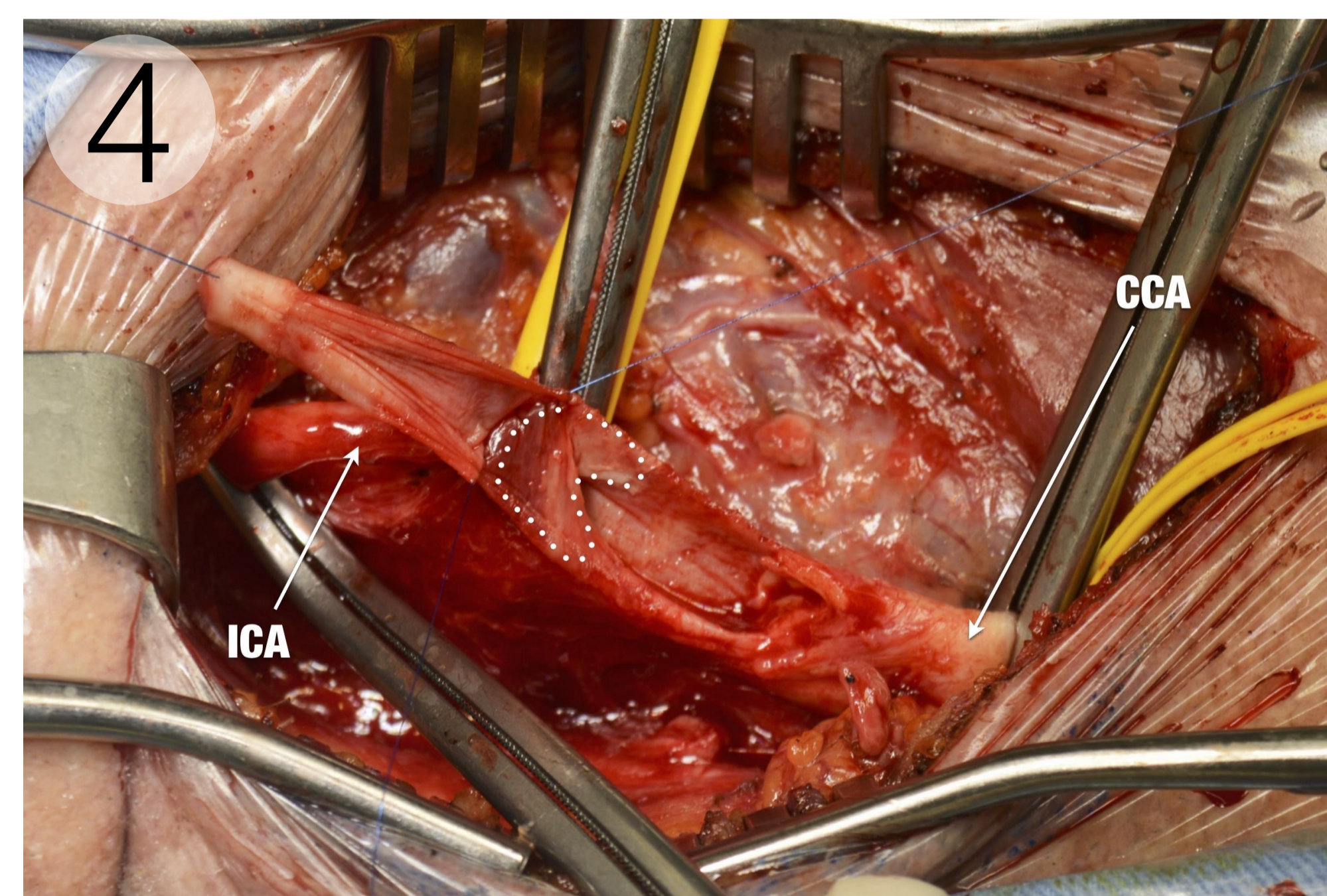
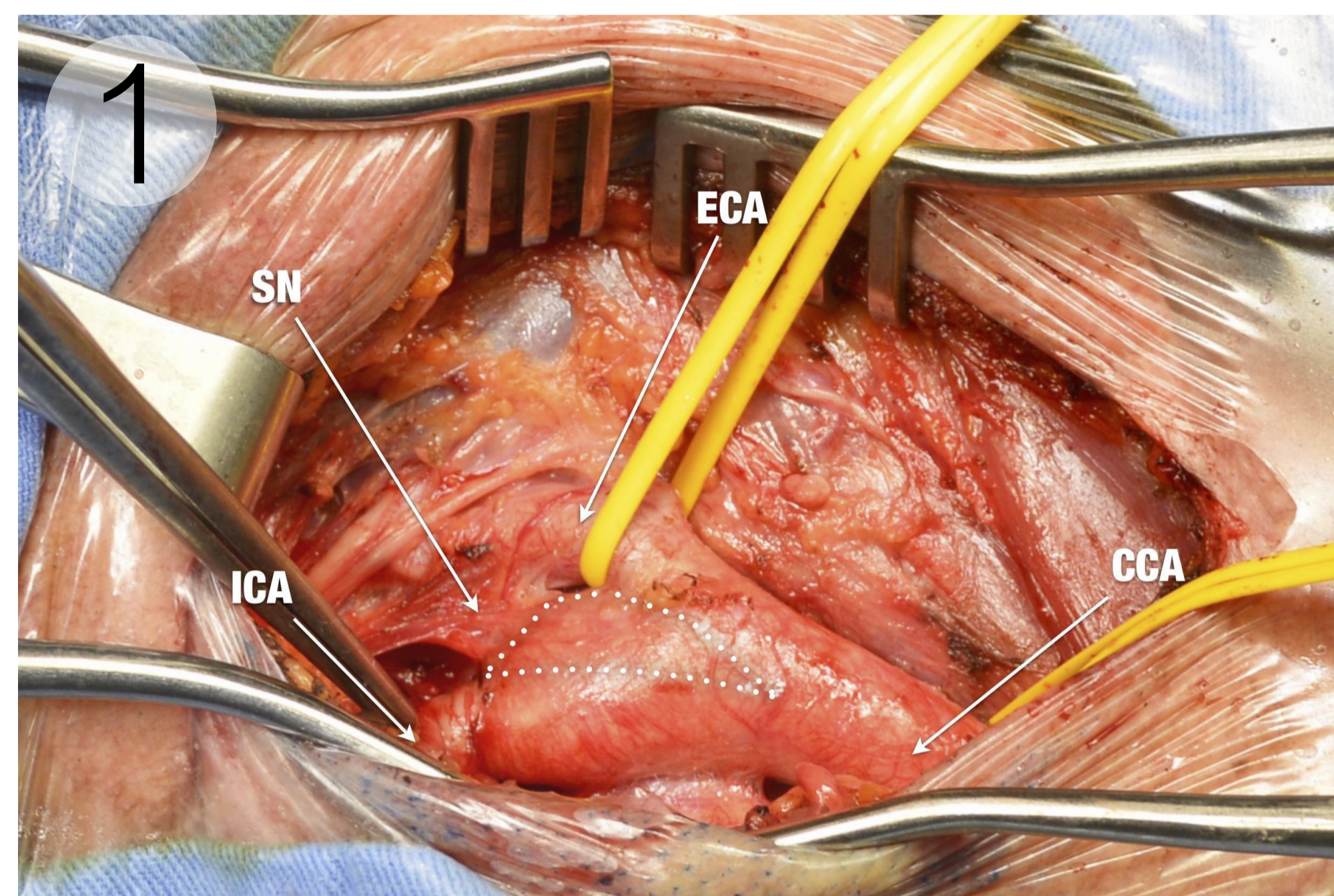
The presented sinus-preserving carotid endarterectomy technique is safe, feasible and routinely applicable in selected carotid surgery patients. The presented step-by-step explanation offers sufficient description of the technique as to make it replicable.

Conclusion

While diverse surgical approaches aiming to preserve the carotid sinus during carotid endarterectomy exist, the present method offers clear technical practicability, as well as appropriate patient selection criteria. Additionally, local sinus nerve preservation may benefit to the patient's overall baroreceptor homeostatic mechanism. Although various single centre evidence give insight into the cardiovascular advantages of the present technique, further studies are required to confirm that the sinus-preserving carotid endarterectomy as an occasional alternative to the classical eversion technique is as low-risk and patient-profitable as the well-established patch-plastic and eversion carotid endarterectomy techniques.

Preparation of the carotid bifurcation

During preparation, the sinus nerve of Hering bundle (SN) should not be manipulated unless necessary. The tissue web in which the nerve lies in should not be prepared, and as a whole left on the corresponding side of the external carotid artery (area within the dashed line).

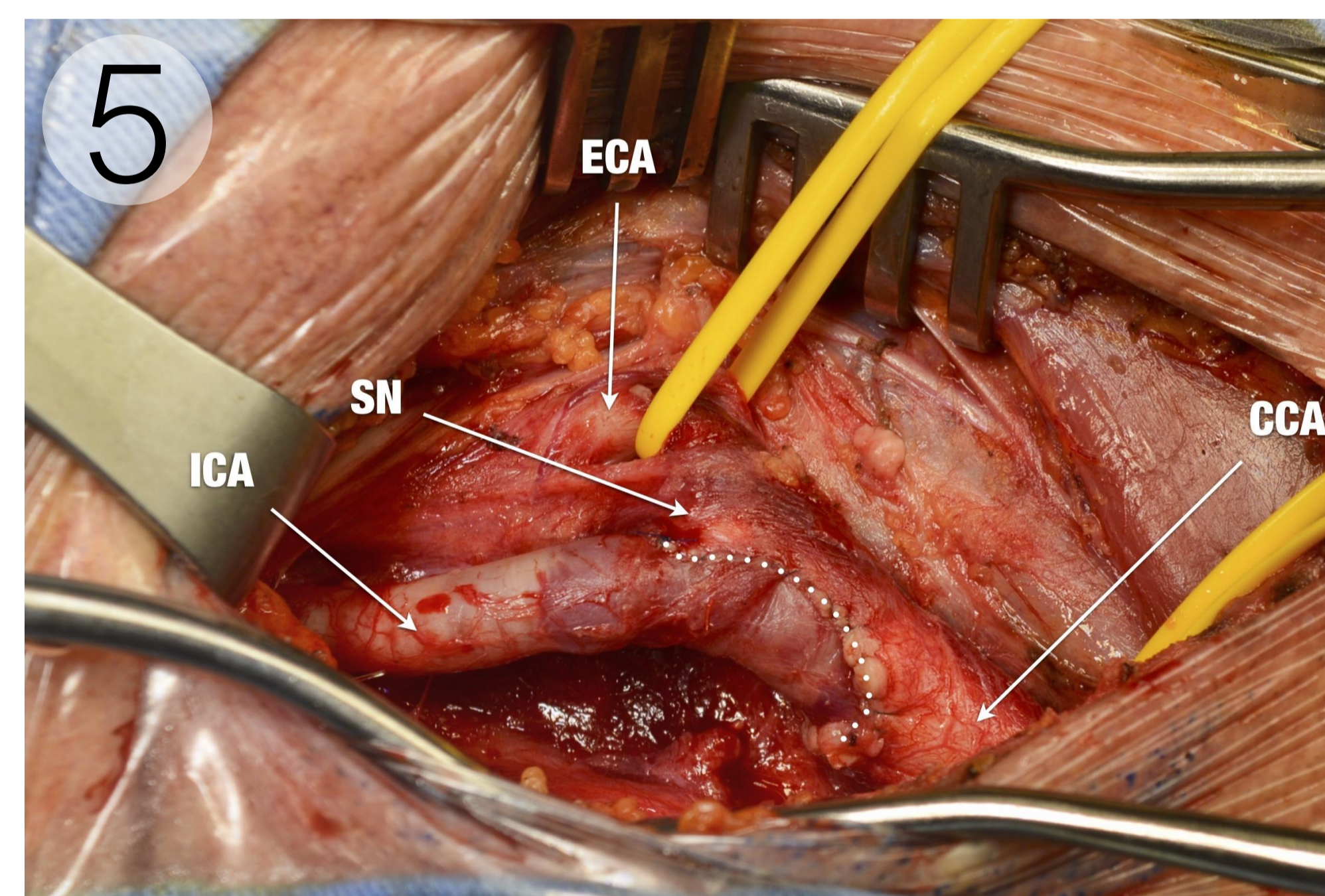
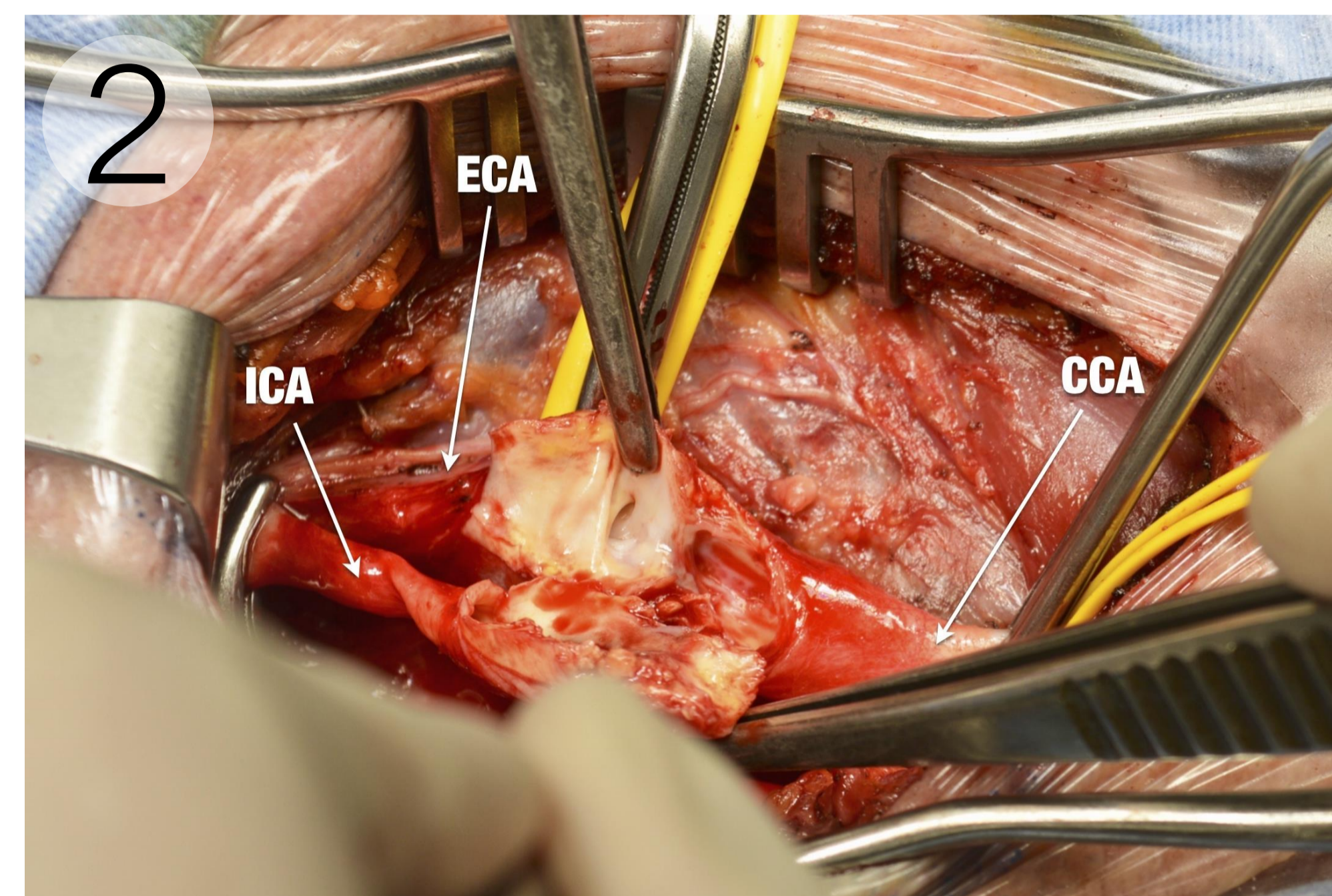


Initial step of the reconstruction of the carotid bifurcation

The sinus preserving approach creates a 'tissue-peninsula' between the cranial cut-off of the internal carotid artery and the point of entry of the sinus nerve within the carotid bifurcation (area within the dashed line). The intended preservation of a maximum of functional nerve endings should thus be achieved.

Sinus-preserving section of the internal carotid artery

After an initial longitudinal incision of the internal carotid artery, cranial and caudal cut-offs are performed, thus creating a "Z"-shaped section. After dissection of the internal carotid artery, a normal eversion of the internal carotid artery and a endarterectomy of the external and common carotid arteries can be performed without damaging the sinus nerve.



Reconstructed carotid bifurcation after sinus-preserving carotid endarterectomy

Through avoidance of preparation of the sinus nerve of Hering bundle and sparing of the point of entry area, a preservation of a maximum of functional nerve endings is probably achieved.

View of Internal & common carotid arteries after removal of atherosclerotic plaques

Both the "Z"-shaped cut of the internal carotid artery and the corresponding orifice on the common carotid artery enable to perform a thrombectomy lege artis.

