

# Implementation of new endovenous treatments of varicosis in the therapy of lateral embryonic veins in Klippel-Trenaunay Syndrome

U. Huegel, Department of Angiology, Inselspital, Bern University Hospital, University of Bern, Switzerland

The Klippel-Trenaunay syndrome is a sporadic malformation characterized by the clinical triad of **capillary malformation**, **soft tissue/bone hypertrophy** and an **abnormal development of deep/superficial veins** resulting in **varicose veins**, **deep vein malformations** and a **persistent lateral embryonic vein (marginal vein)**. The marginal vein consists of a large diameter and causes venous stasis and hypertension as a consequence of the absence of valves along its entire length. The extensive diameter of the vein impedes a successful treatment by sclerotherapy with polidocanol, sodium tetradecyl sulphate or alcohol. The surgical removal is considered technically challenging for potential severe blood loss due to the large perforators to the deep veins and because of the intradermal extension of the vein where it could tear easily and provoke serious bleedings. Therefore we tried to proof safety and efficiency of endovenous treatments of varicosis (laserablation, cyanoacrylate adhesive) in the treatment of lateral embryonic veins.

## Case 1

31-year old woman with KTS and a symptomatic marginal vein, max. diameter 1,4cm. After repeated unsuccessful ethanol injections we used a diode laser, wavelength 1470 nm at a setting of 10 Watt (VenaCure Laser 470, angiodynamics, Latham, NY) with a total of 13900 J over 76 cm (180J/cm). The puncture of the vein was realized under ultrasound guidance supramalleolar using a 14 G peripheral iv catheter. After introduction of the laser fibre (NeverTouch Direct, angiodynamic, Latham, USA) and advancing it over the complete subcutaneous length of the vein. Tumescence anesthesia was applied before the laser was activated and gradually withdrawn. An ultrasound control after 34 months revealed a continuous success with a complete closure of the treated vein segments. Heaviness, swelling and pain in the left lower limb could be reduced.

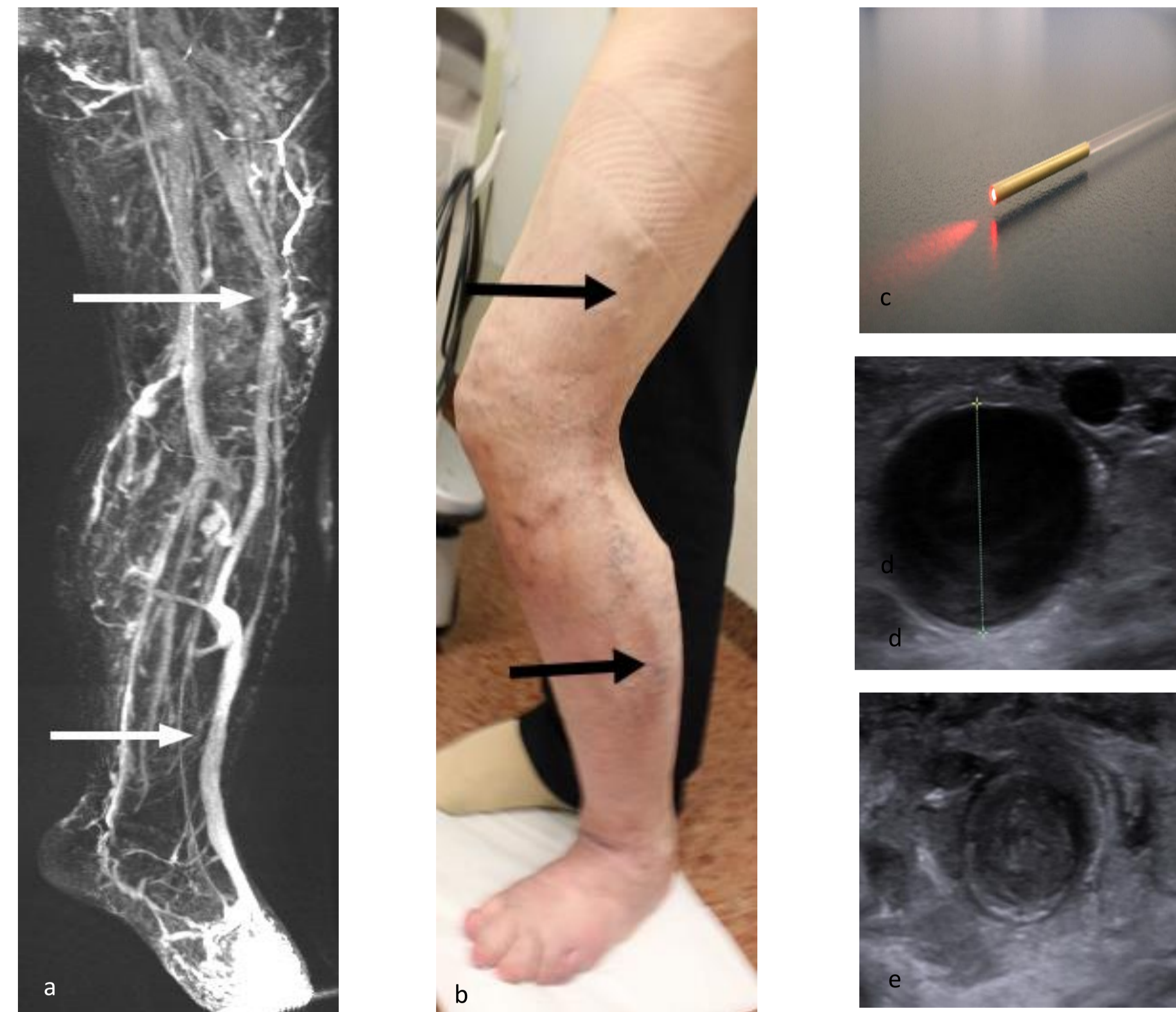


Fig. 1 MRI before laser treatment showing the ectatic marginal vein (white arrows) in the lateral aspect of the left lower limb (a). Clinical aspect 20 months after EVLT indicating a discrete brown stain at the former course of the marginal vein (black arrows) (b). Tip of the laser fibre (c). Transverse sonographic image of the marginal vein before EVLT (d) and 1 day after EVLT (e)

## Case 2

A 47-year old woman with a painful lateral embryonic vein, with a max. diameter of 8mm and multiple tributaries was treated with 9 ml N-butyl-cyanoacrylate, VenaSeal™ (Medtronic, Minneapolis, MN). The adhesive was injected through 18- and 20-gauge peripheral iv catheters. Due to an antiphospholipid syndrome the patient receives oral anticoagulation, which had to be stopped for the procedure. Ultrasound after 26 months indicated a therapeutic success with a complete closure of the treated vein segments. Clinically a reduction of swelling/pain was achieved.

## Case 3

A 16-year-old man with an incomplete KTS was suffering from swelling and was disturbed by a large marginal vein (diameter 10mm) and multiple protruding tributaries of the left leg. Two treatment sessions were necessary, in each session 4,5ml were applied. The ultrasound controls after 28 months confirmed complete closure of the treated vein segments. Beside reduction of swelling the patient profited from the decrease of the cosmetically disturbing veins.

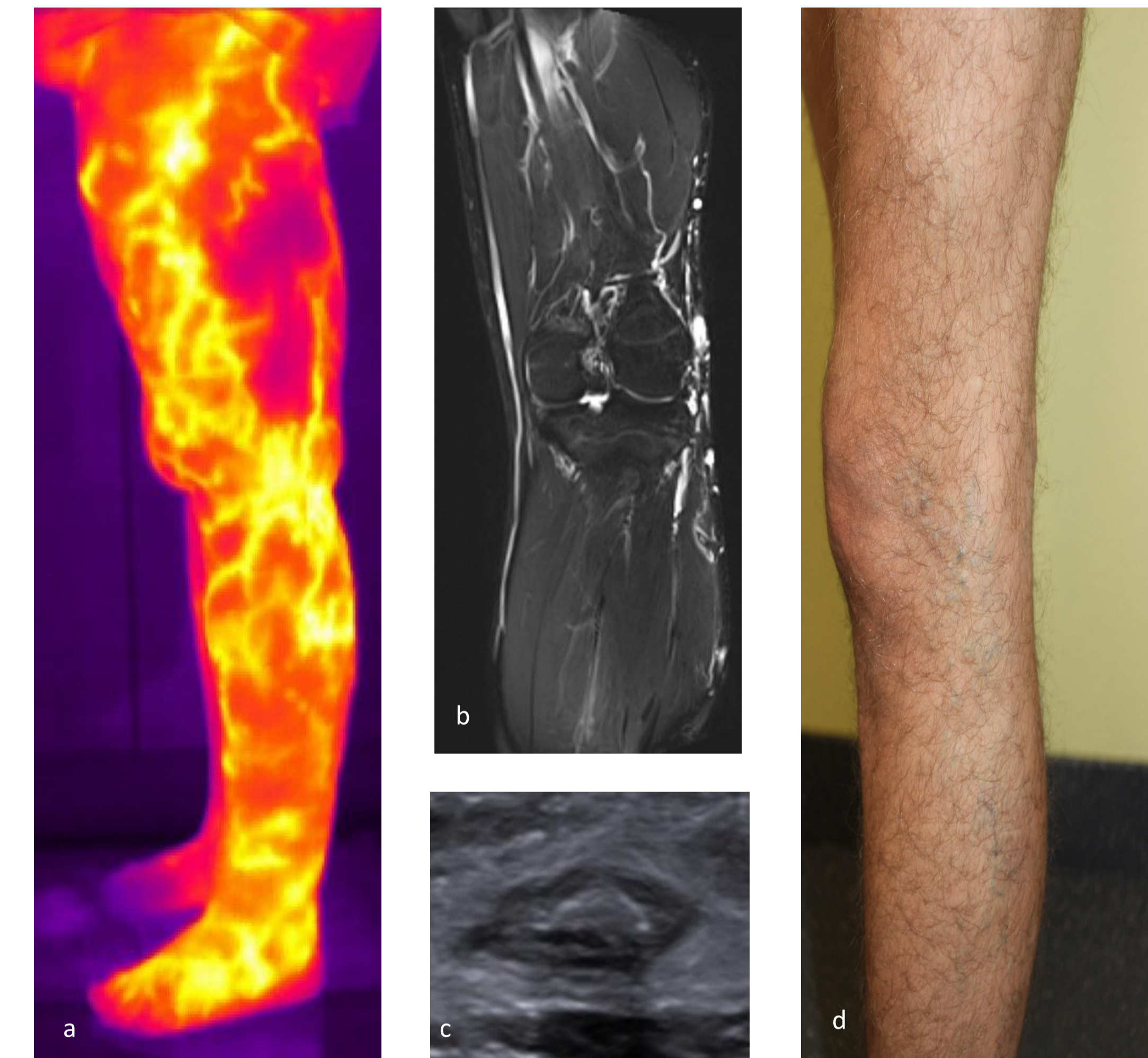

Fig. 2 Thermography of the left lower limb depicting venous malformation (a). MRI before treatment (b). Transverse sonographic image of the marginal vein 3 weeks after treatment with cyanoacrylate. Clinical aspect 28 months after treatment (d)

## Results

In all cases we saw good results with complete closure of the marginal vein confirmed by ultrasound. In all patients a significant reduction of swelling and heaviness of the treated legs was achieved. No thrombosis or pulmonary embolism occurred.

## Conclusion

Endovenous laser ablation as well as the medical adhesive cyanoacrylate are safe and effective in the treatment of lateral embryonic veins during short term follow-up.