

# ELECTRA

5-6 DÉCEMBRE 2024

HOTEL VILLA MASSALIA,  
MARSEILLE | FRANCE

  
Centre hospitalier  
du Pays d'Aix

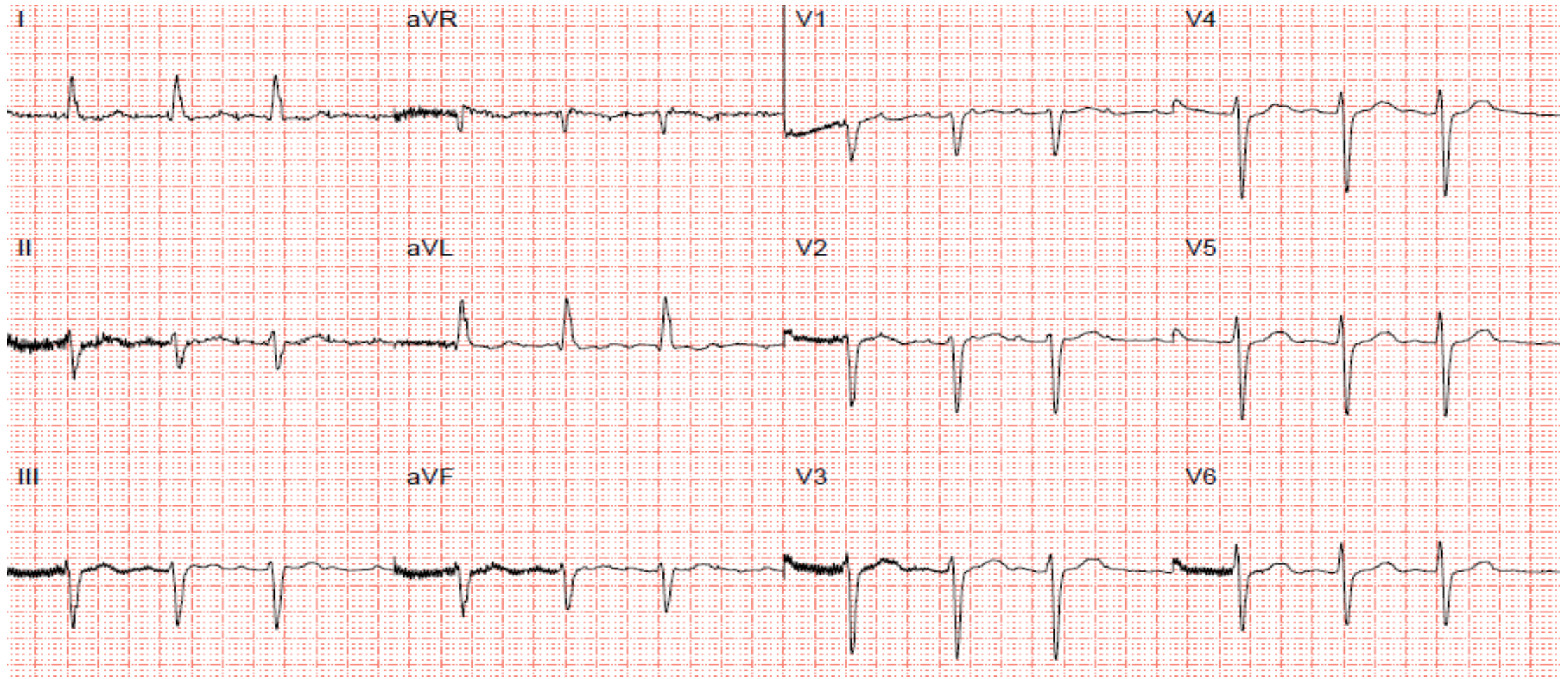
**Dr BOUET Jérôme**  
*Centre hospitalier Aix en Provence*

# Présentation clinique :

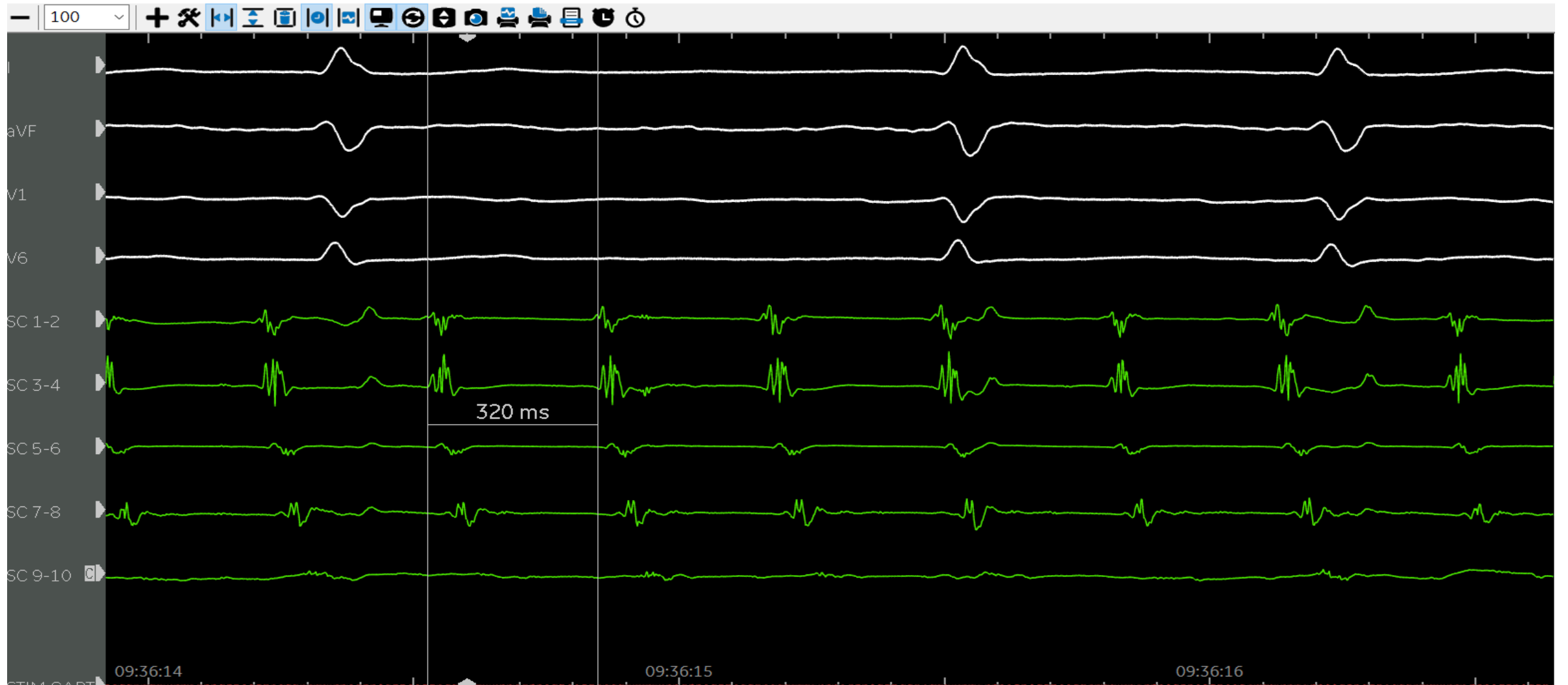
---

- Patient 83 ans
- CEE en 2021
- Ttt : xarelto + cordarone
- Octobre 2024 : récurrence sous forme de flutter

# Présentation clinique :

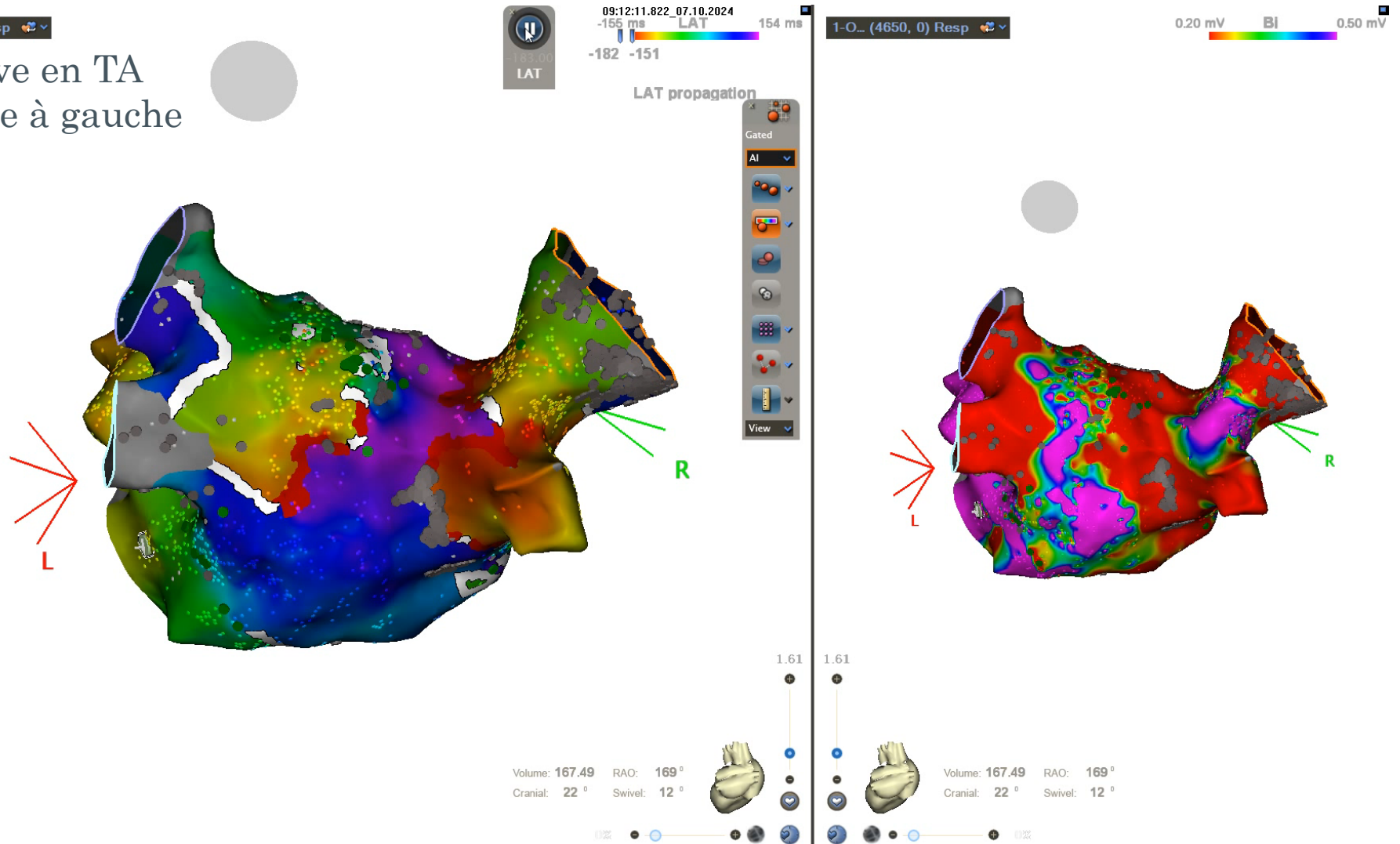


# Flutter G



# Flutter G

Patient de 83 ans - Arrive en TA  
Primo procédure → carte à gauche  
pour commencer



Que feriez-vous ?

# Flutter G

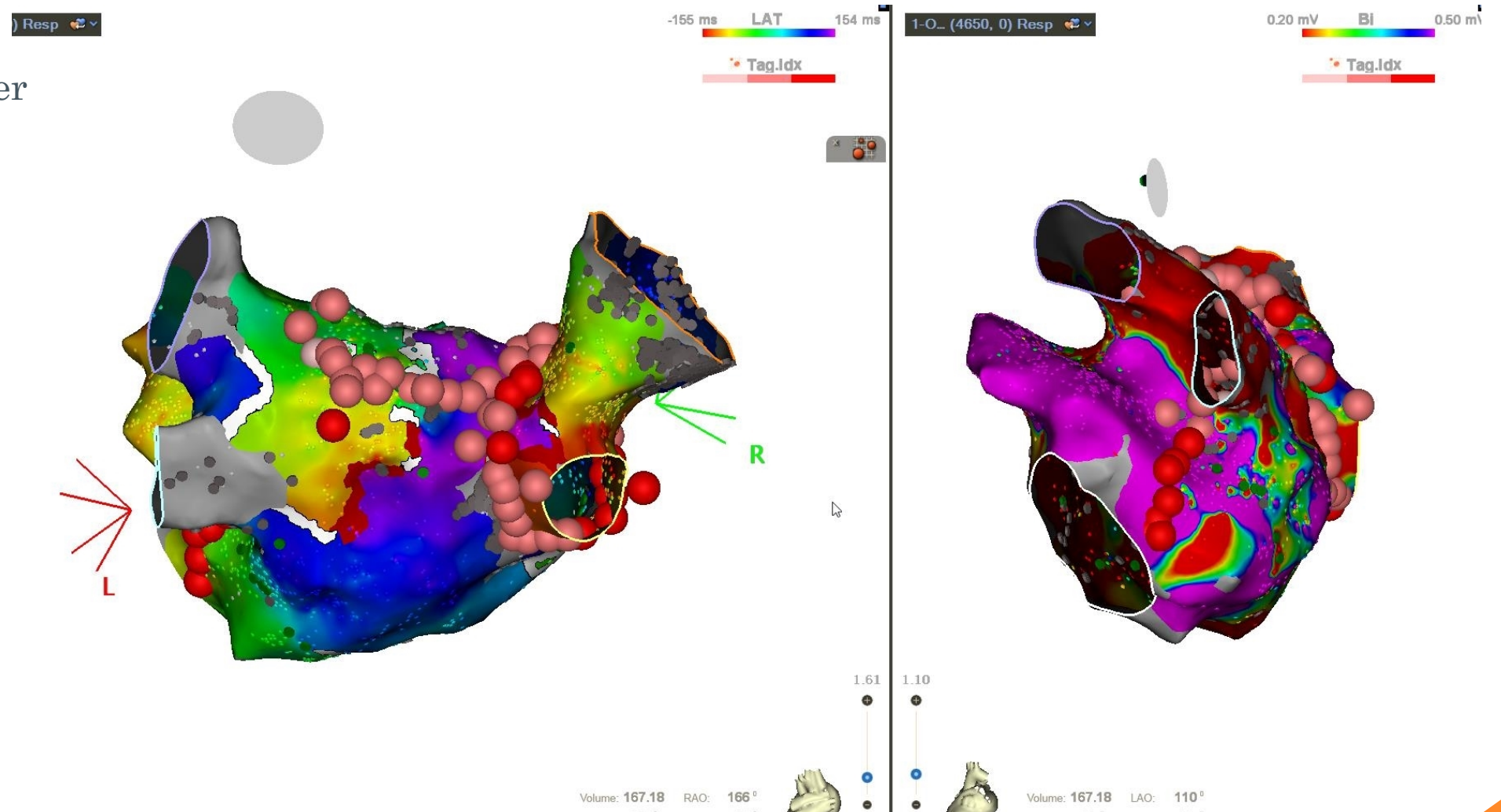
---

Que feriez-vous ?

- PVI ?
- Ablation isthme(s) critique ?
- Carte OD ?
- Plan Marshall (PVI + ligne toit+isthme mitral (OH) ?
- Autres ?

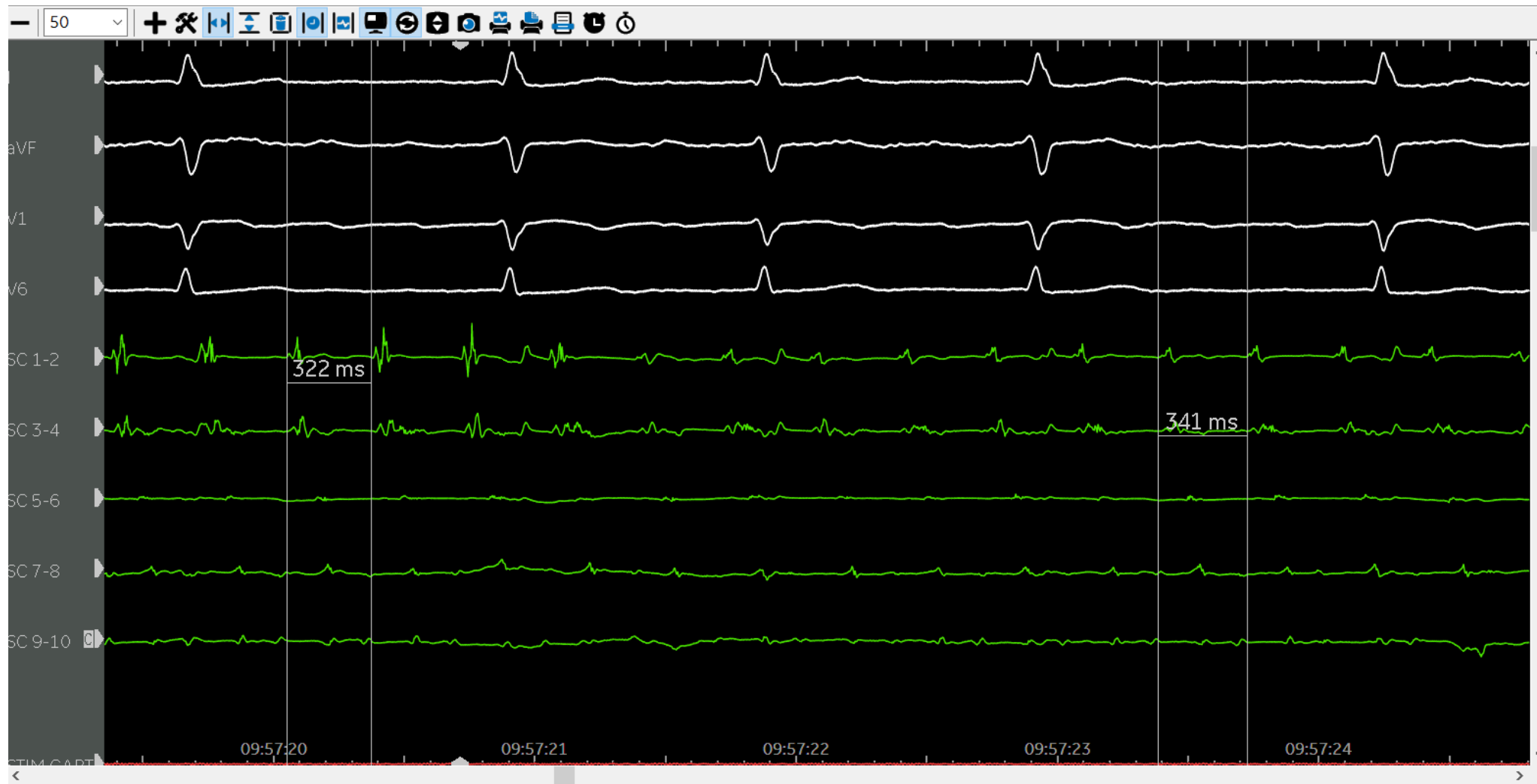
# Flutter G

→ Décide de commencer par plan Marshall



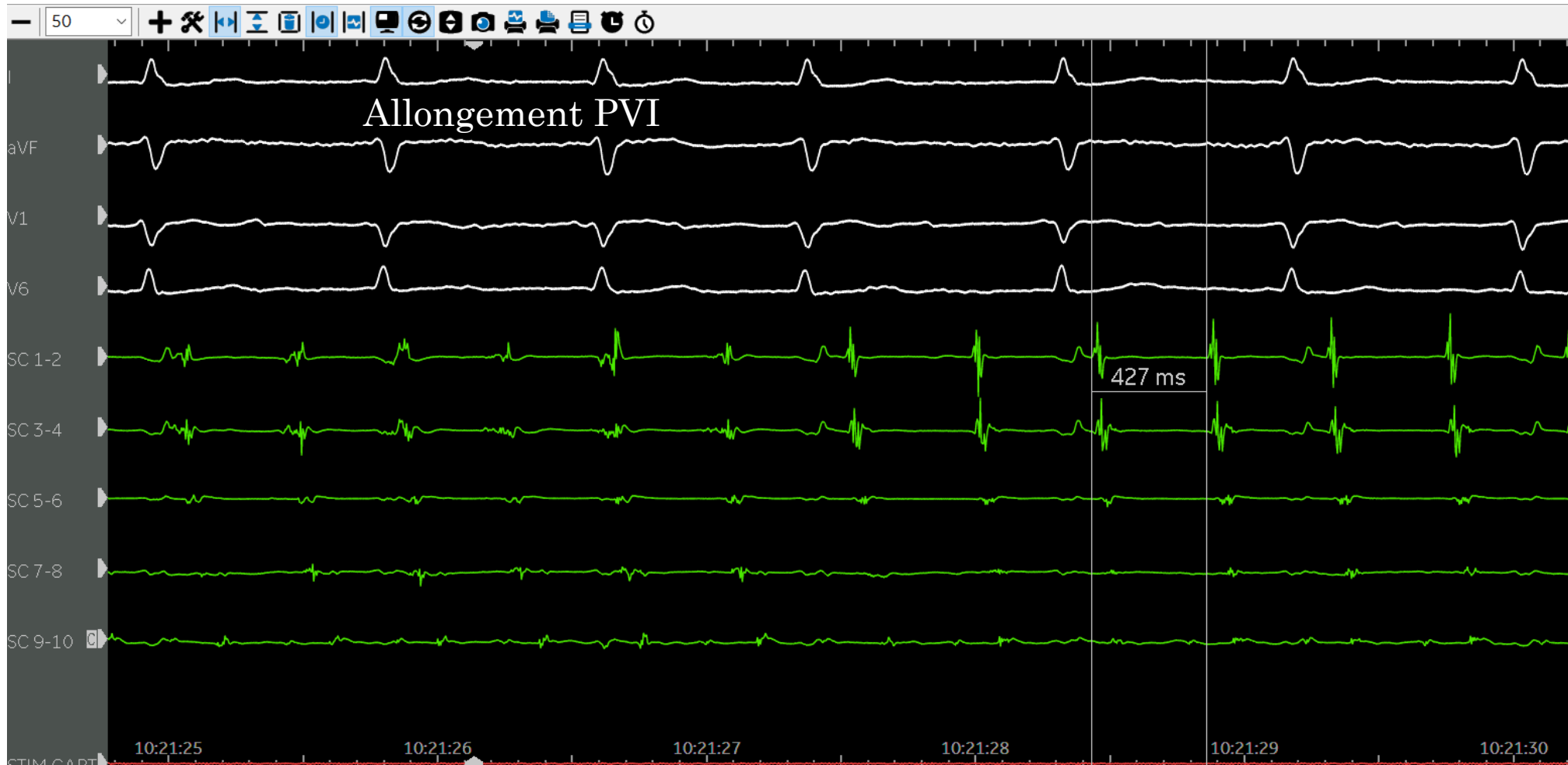
# Flutter G Durant alcoolisation du Marshall, allongement du cycle

1<sup>ère</sup>  
injection  
OH

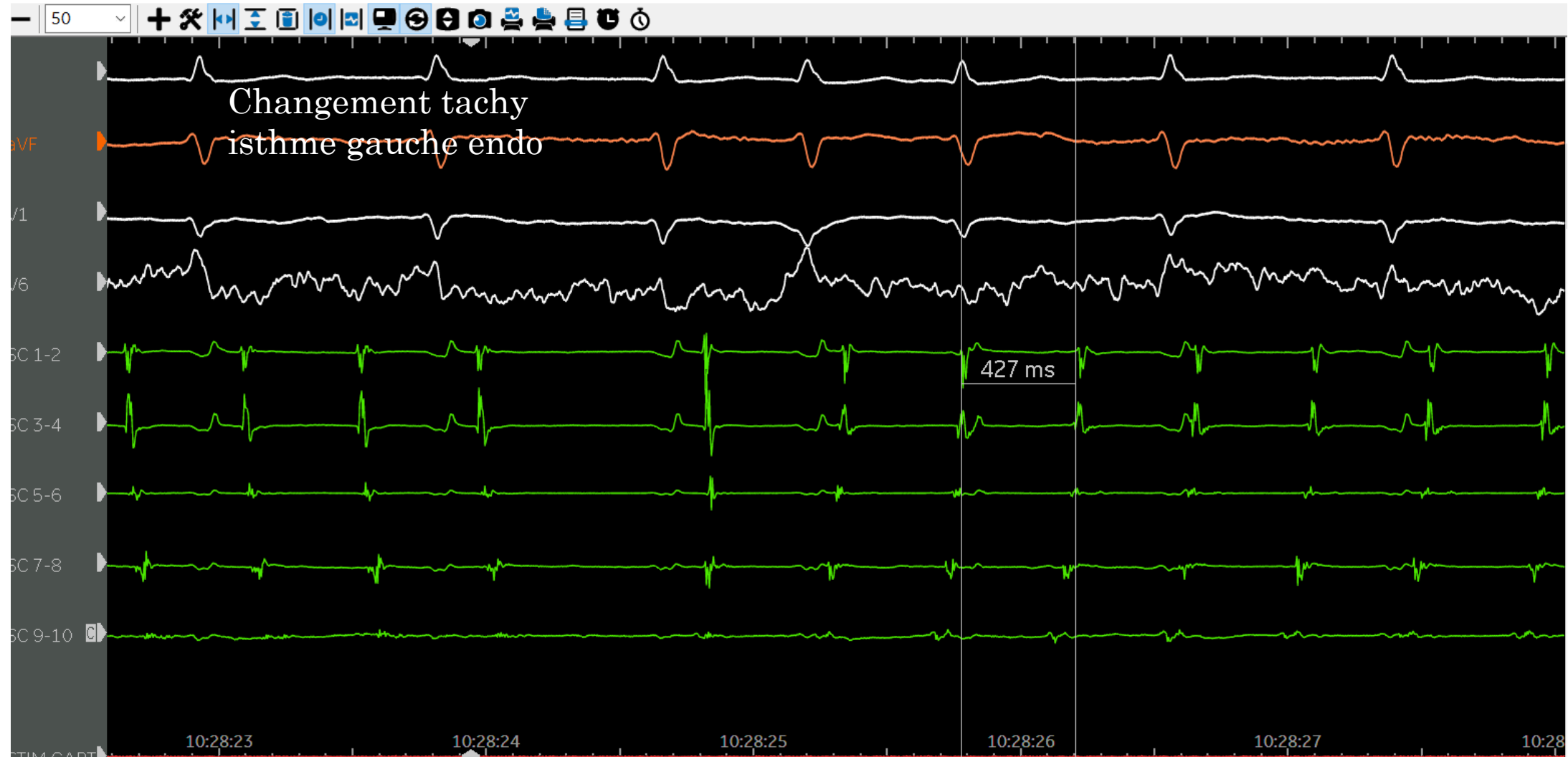




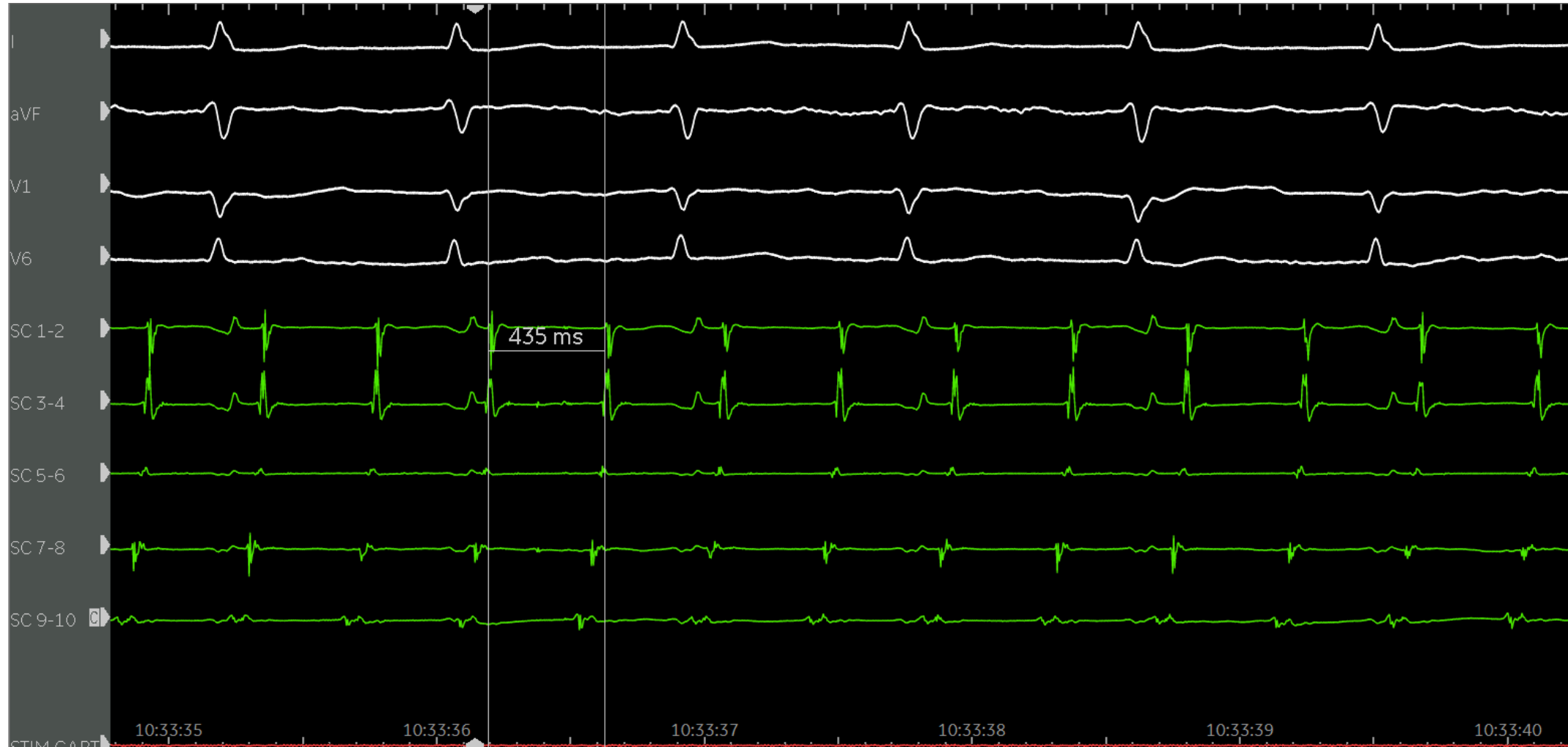
# Flutter G



# Flutter G

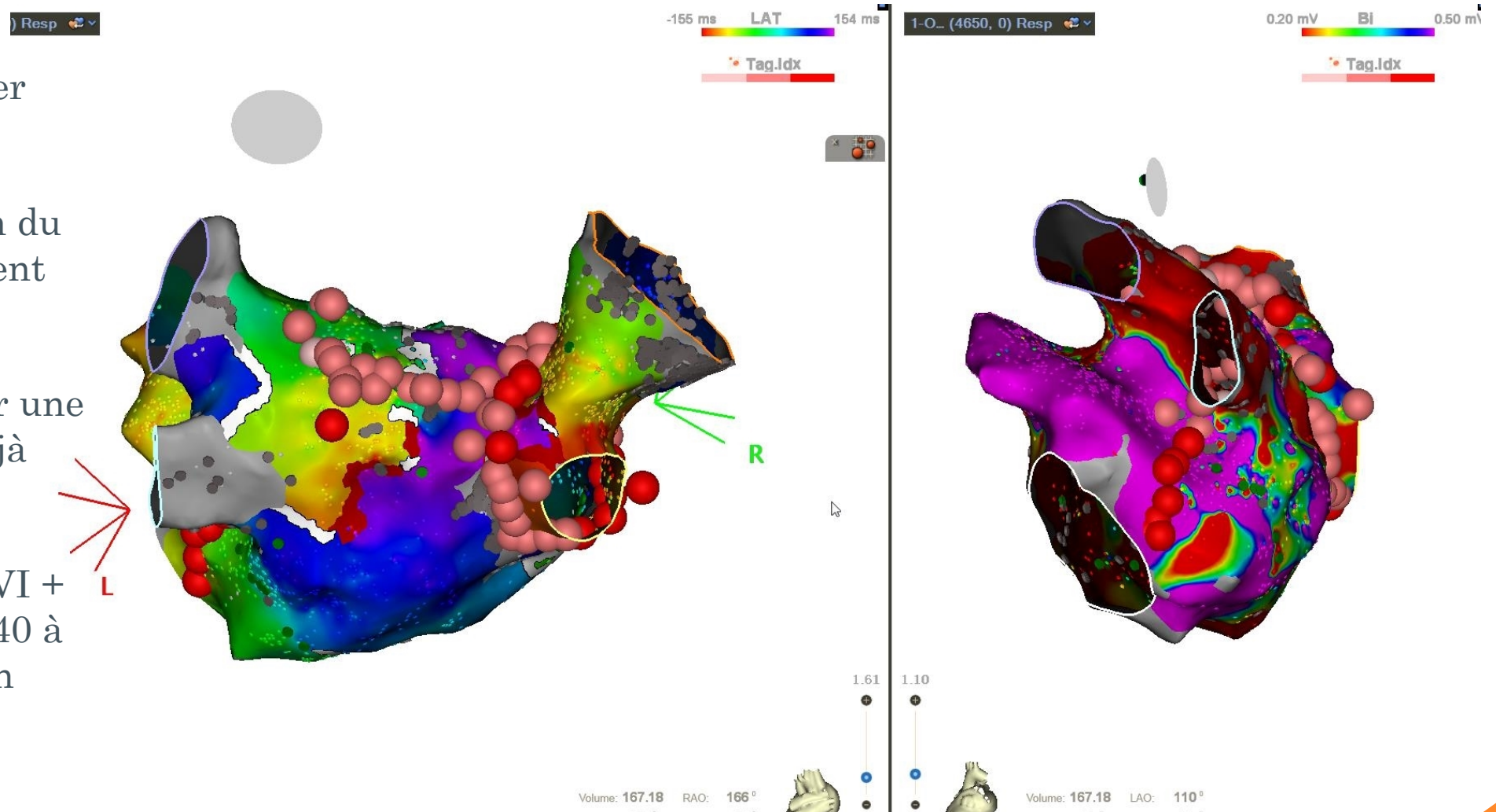


# Flutter G



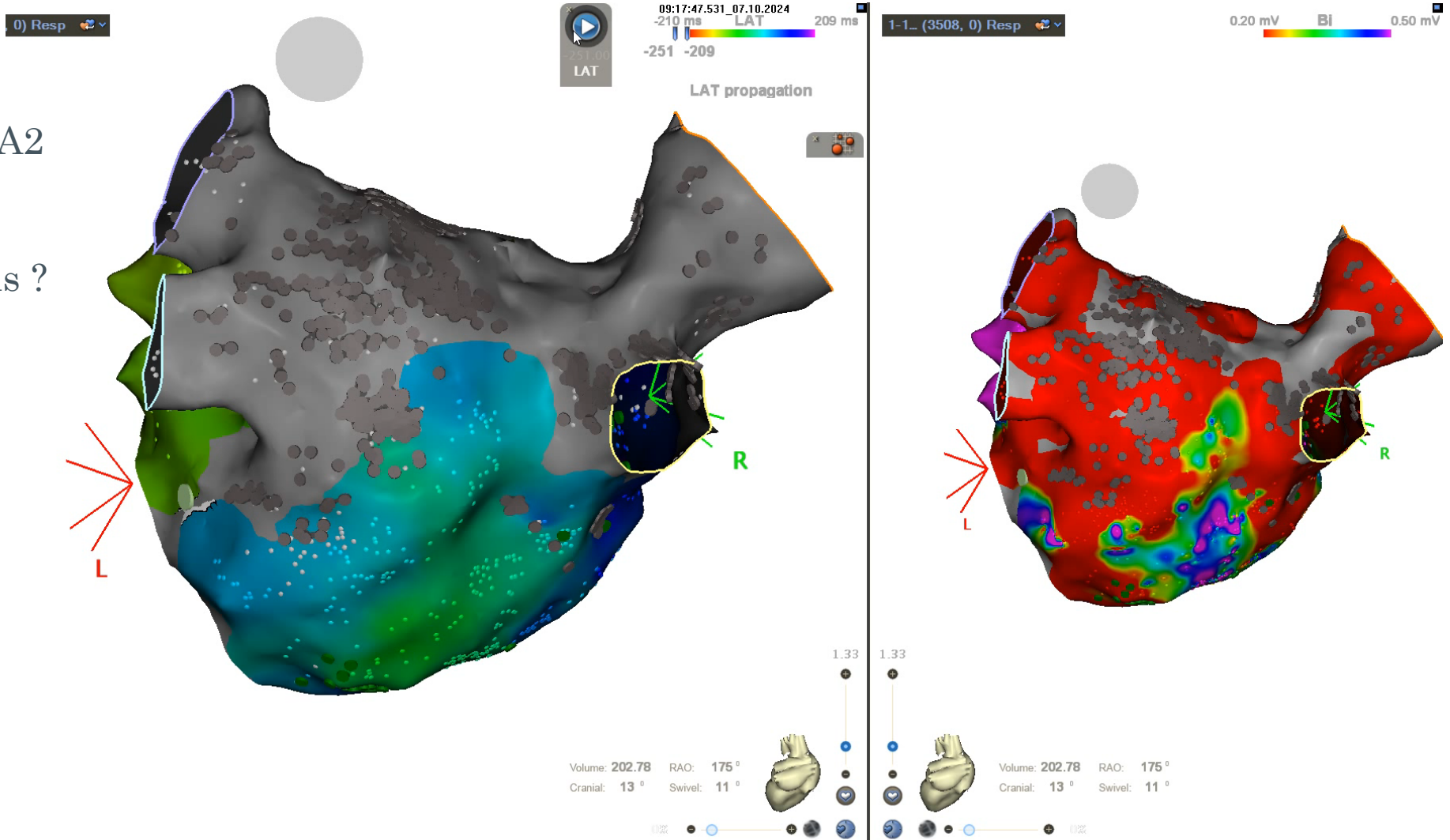
# Flutter G

- Décide de commencer par plan Marshall
- Durant alcoolisation du Marshall, allongement du cycle
- PVI segmentaire car une partie des veines déjà isolées
- Avec complément PVI + lignes → passe de 340 à 430 ms (modification activation)
- Remap



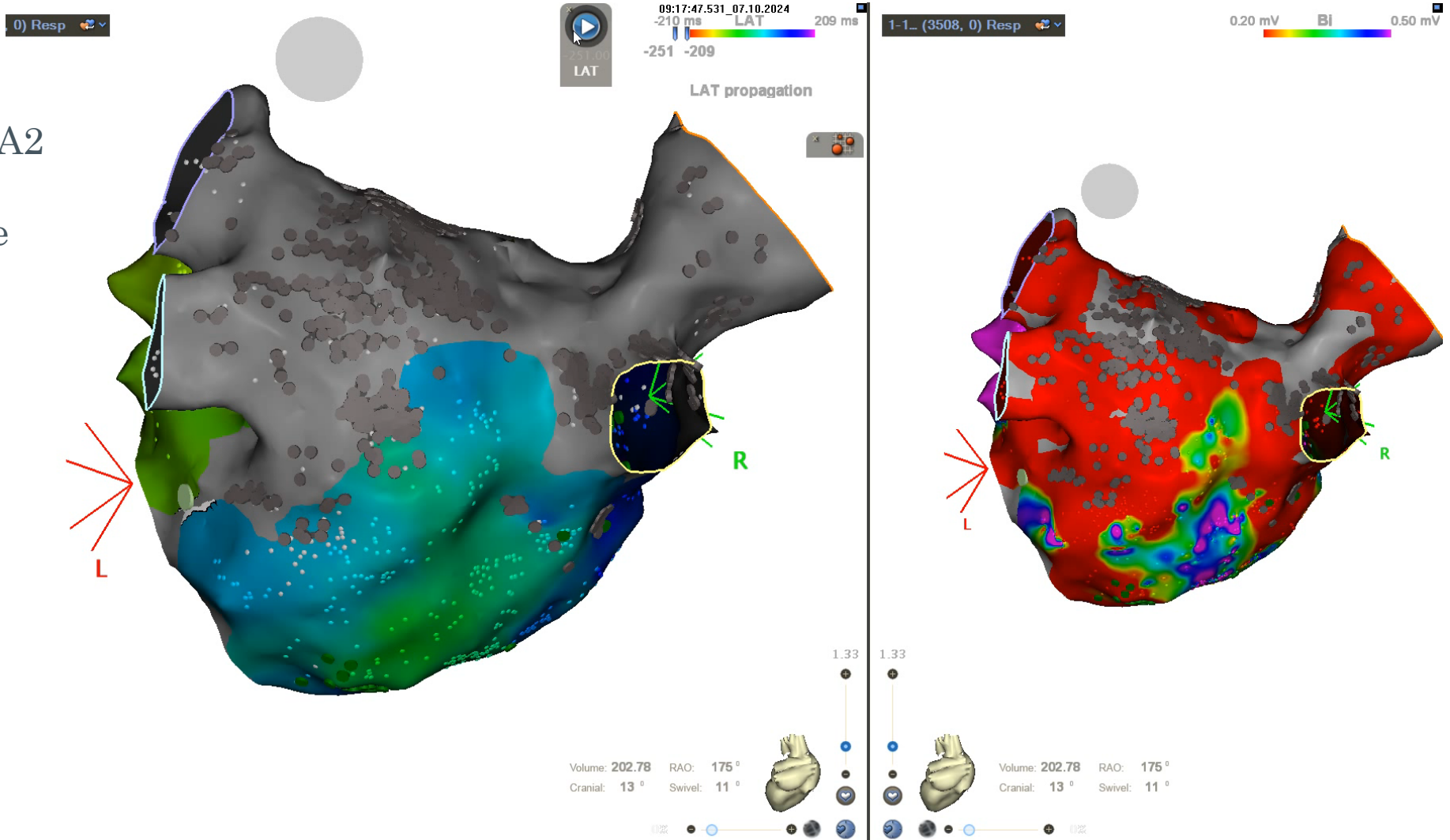
# Flutter G

- Propagation TA2 à 430ms
- Que feriez-vous ?



# Flutter G

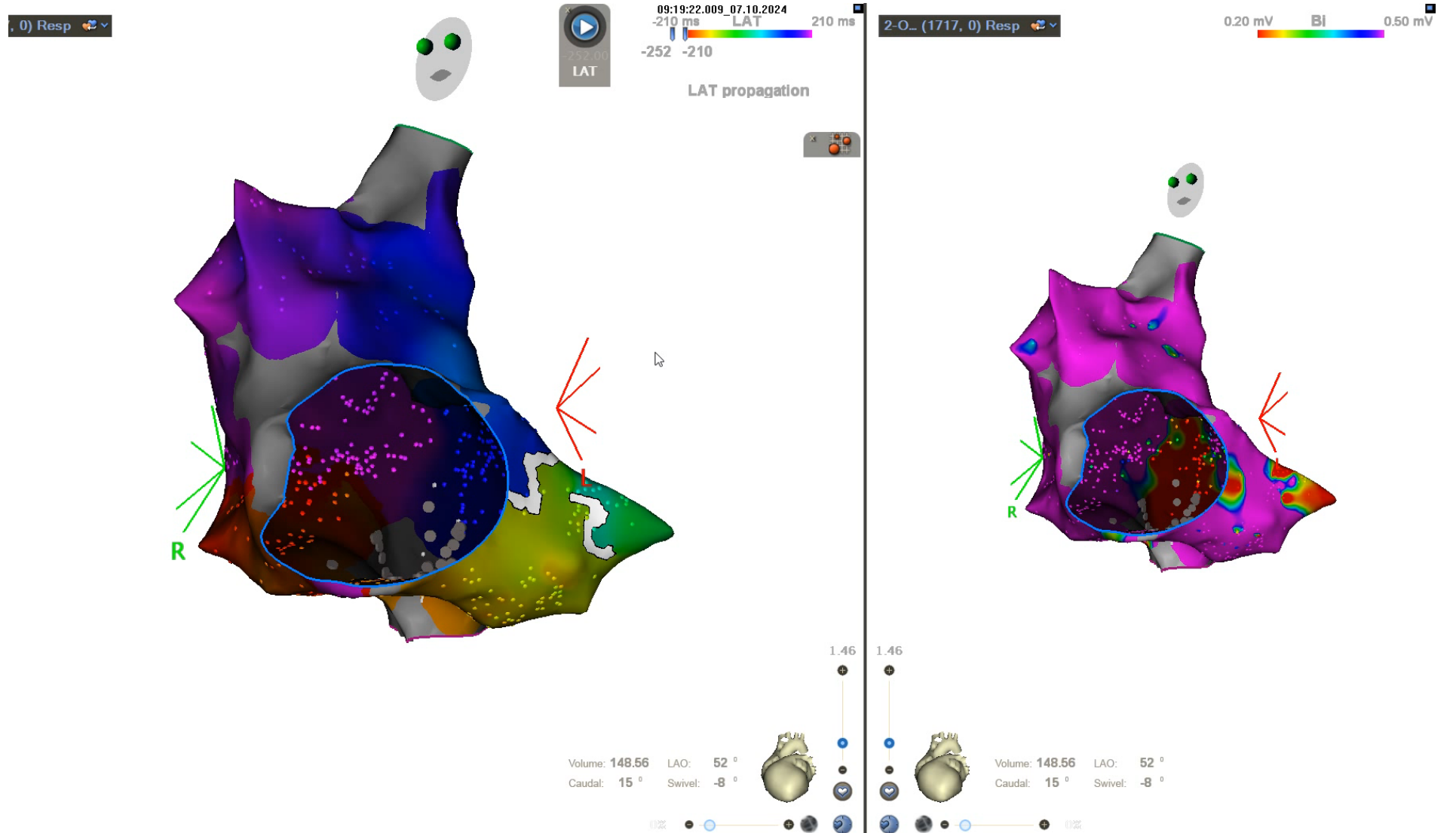
- Propagation TA2 à 430ms
- Décide de faire carte OD



# Flutter G

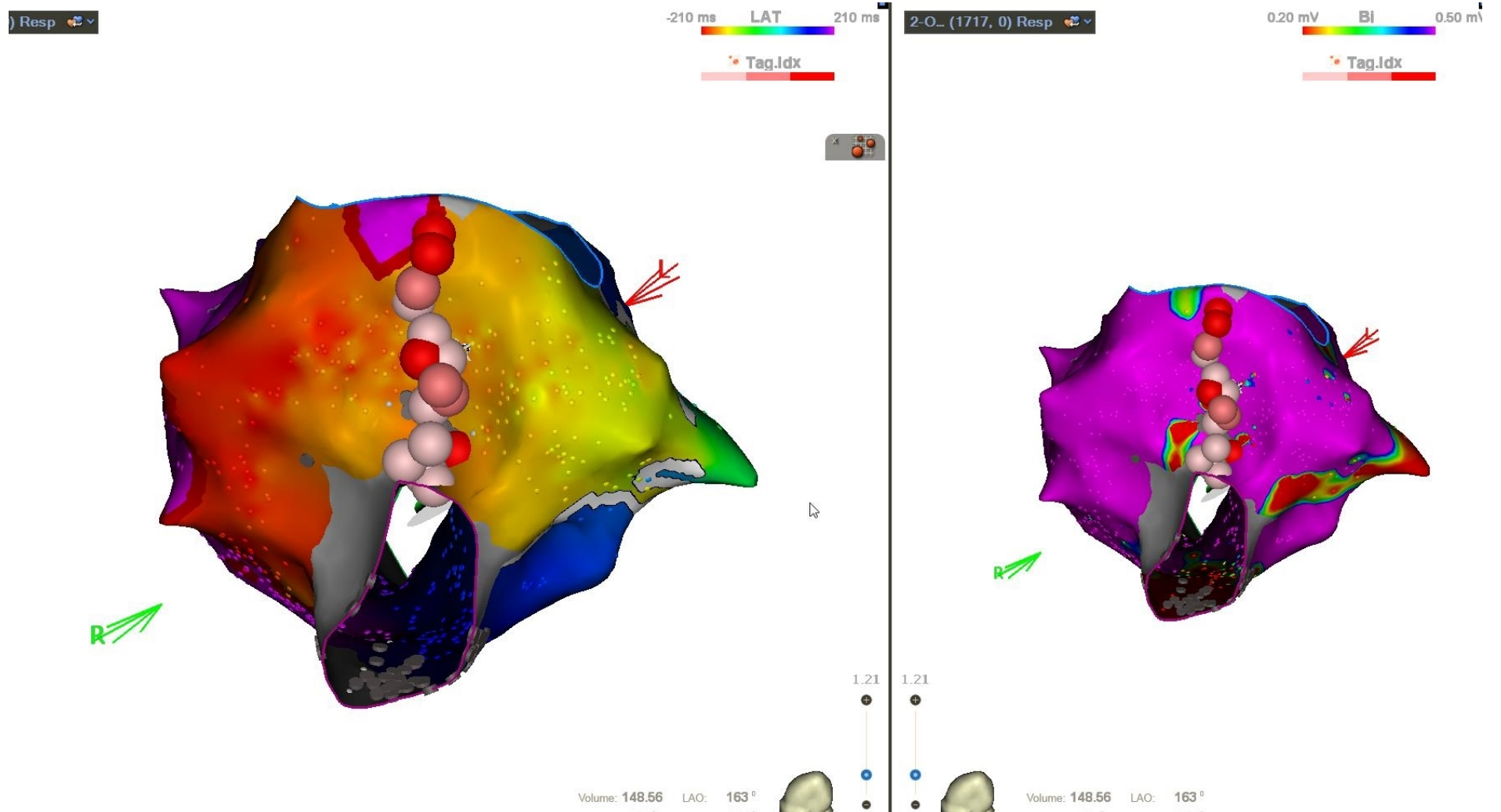
→ Carto OD TA2

→ Que feriez-vous ?



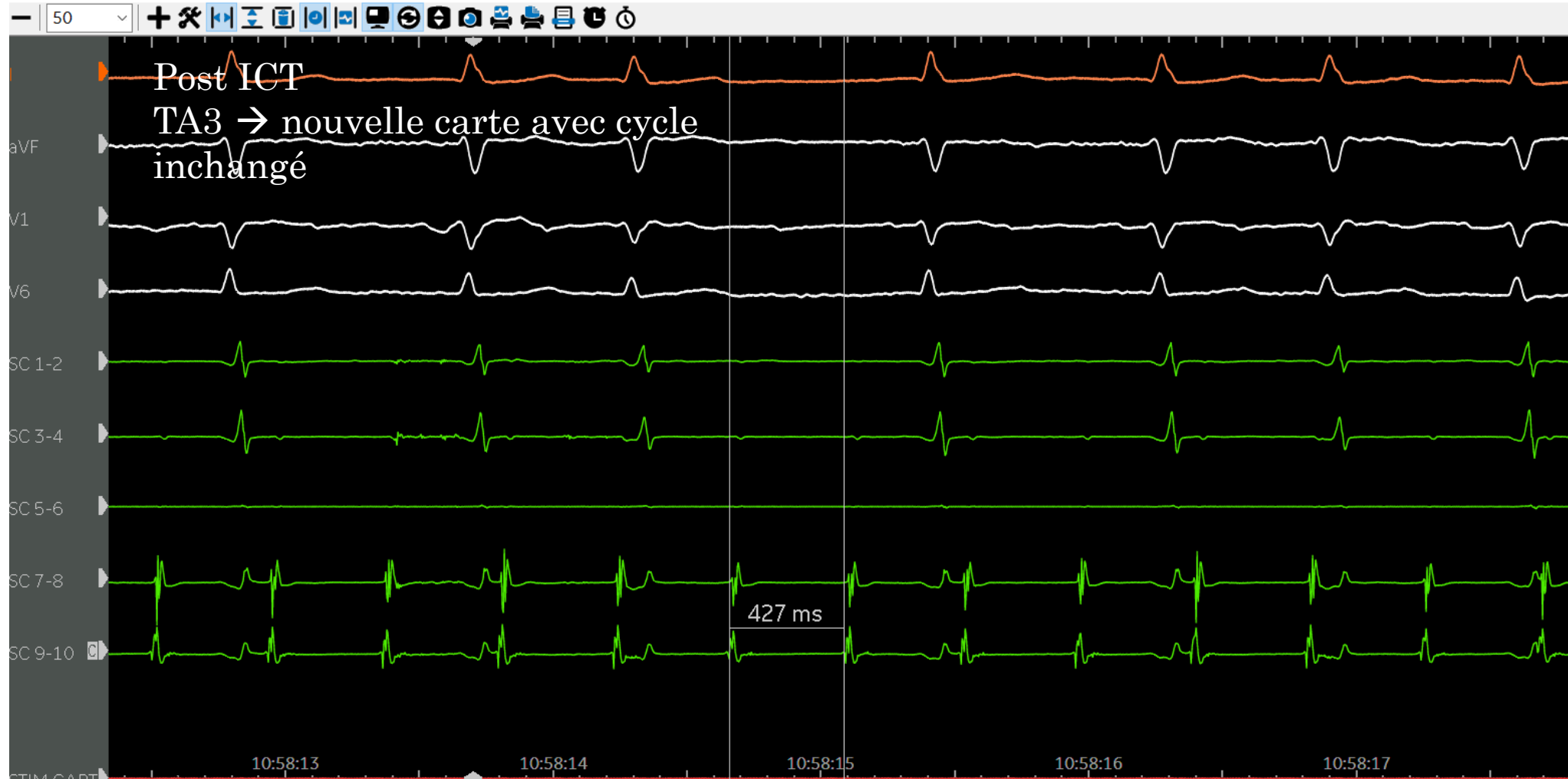
# Flutter G

- Ablation ICT
- Tjs en tachy



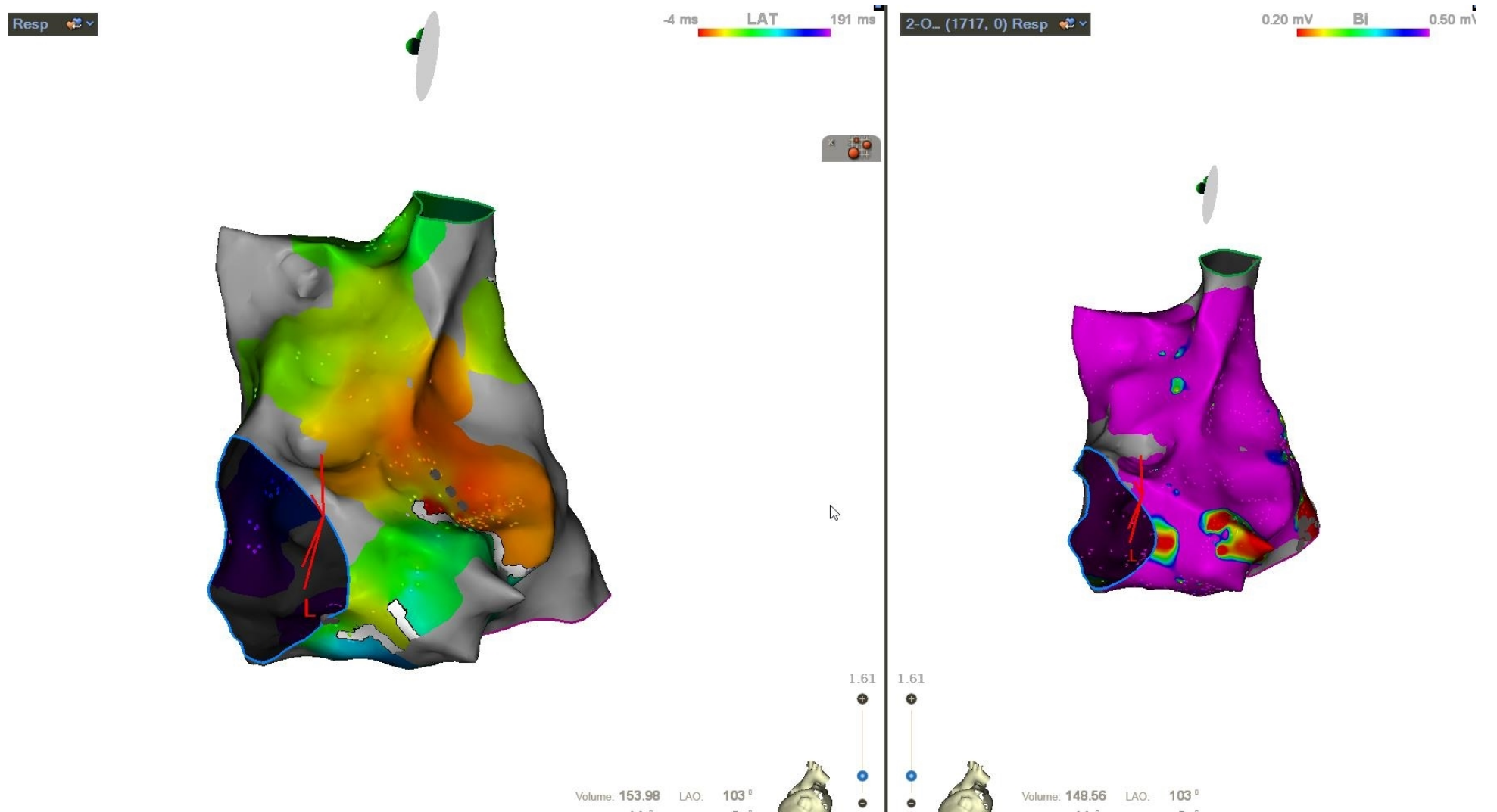


# Flutter G



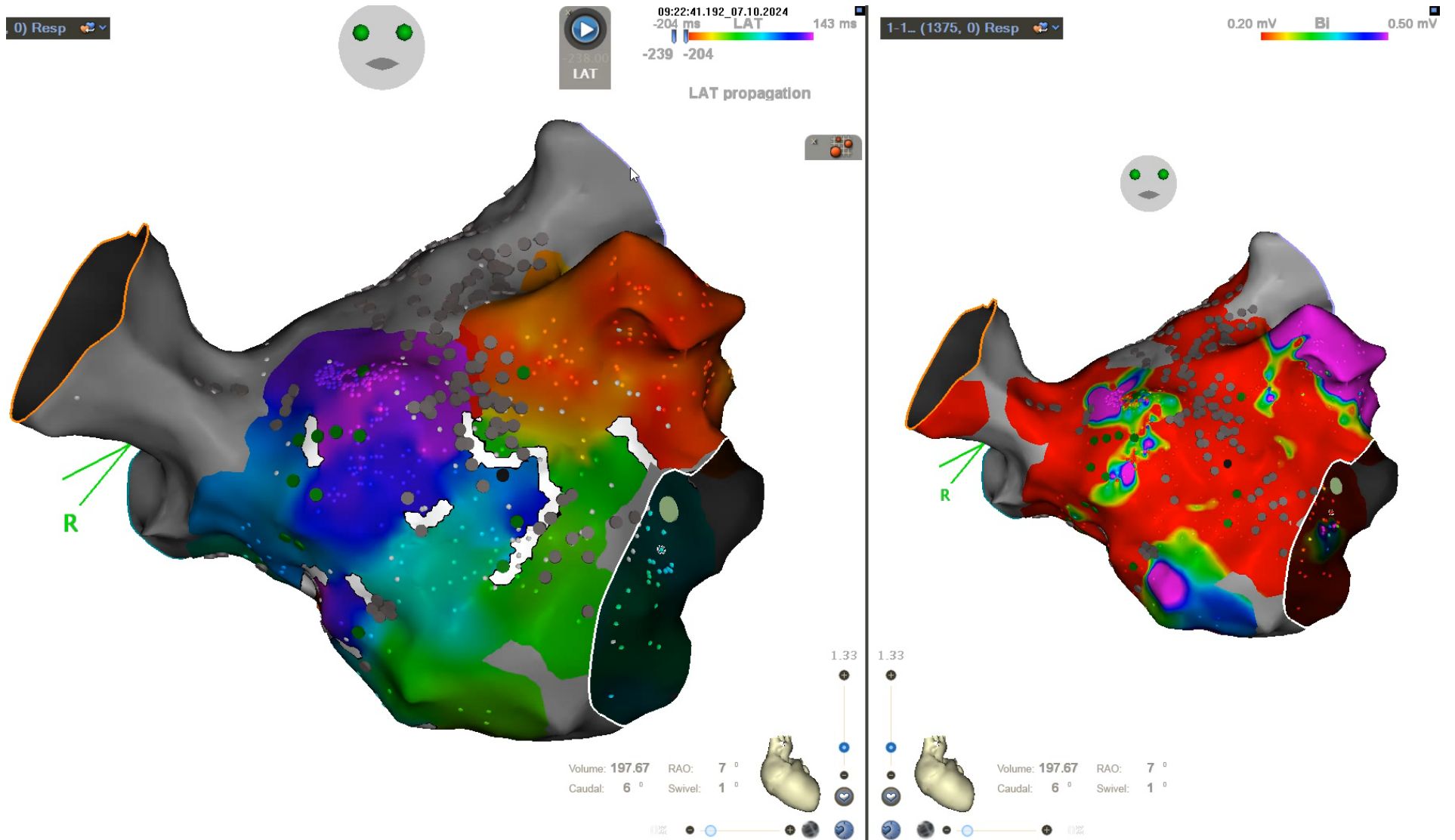
# Flutter G

- Propag TA3  
OD même  
cycle
- Sortie septale
- Carte OG



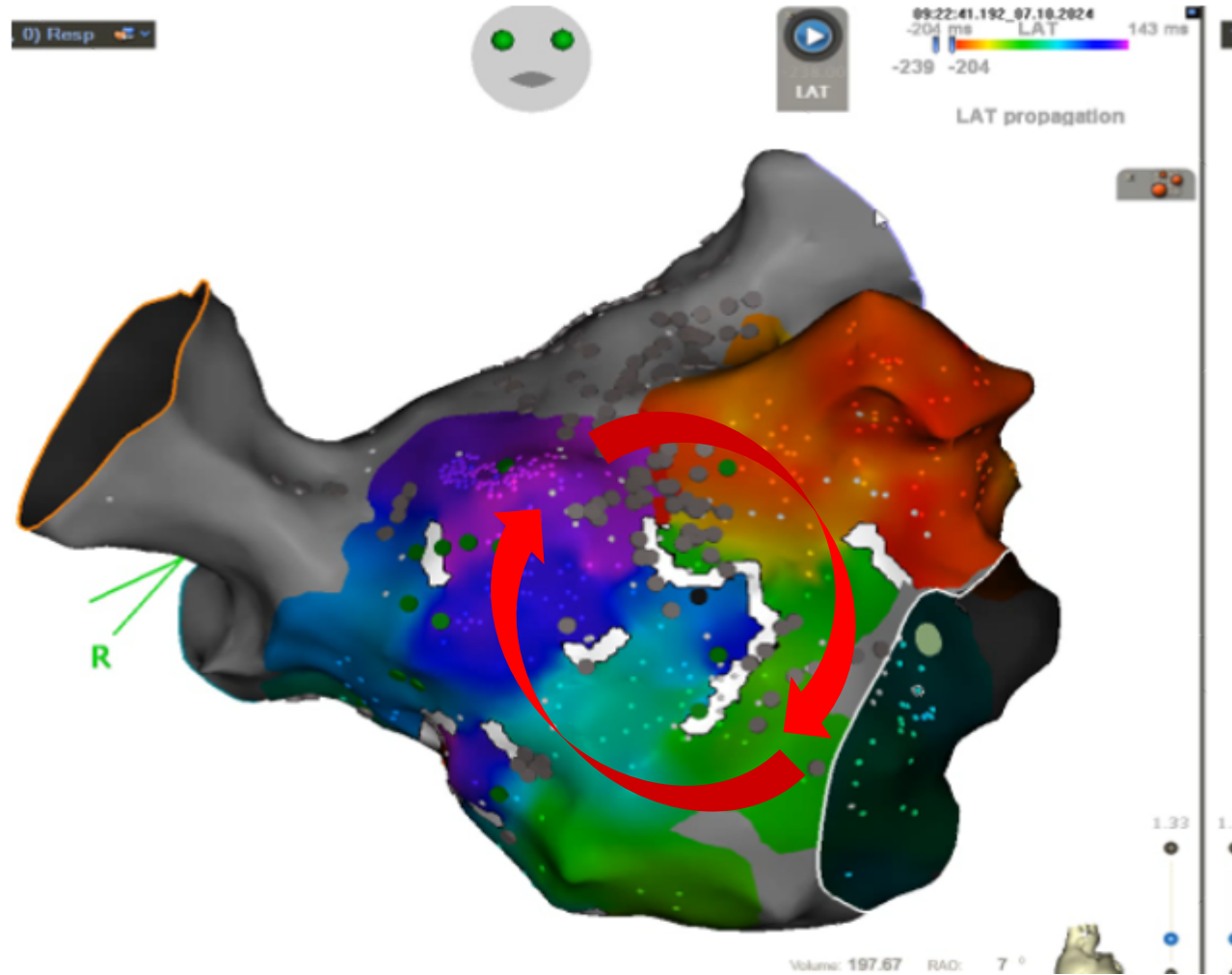
# Flutter G

→ Propag TA3  
OG même  
cycle



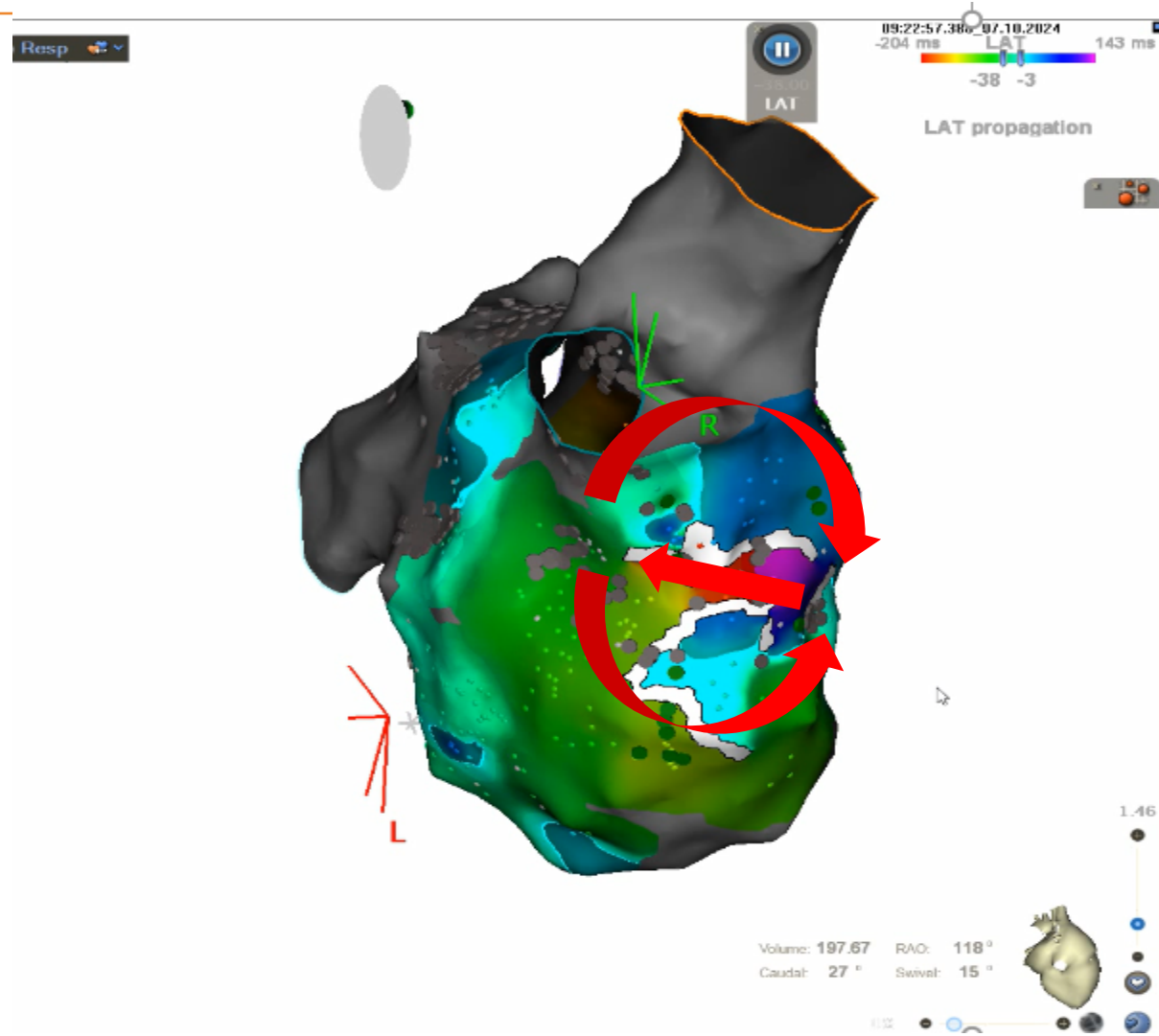
# Flutter G

→ Propag TA3  
OG même  
cycle



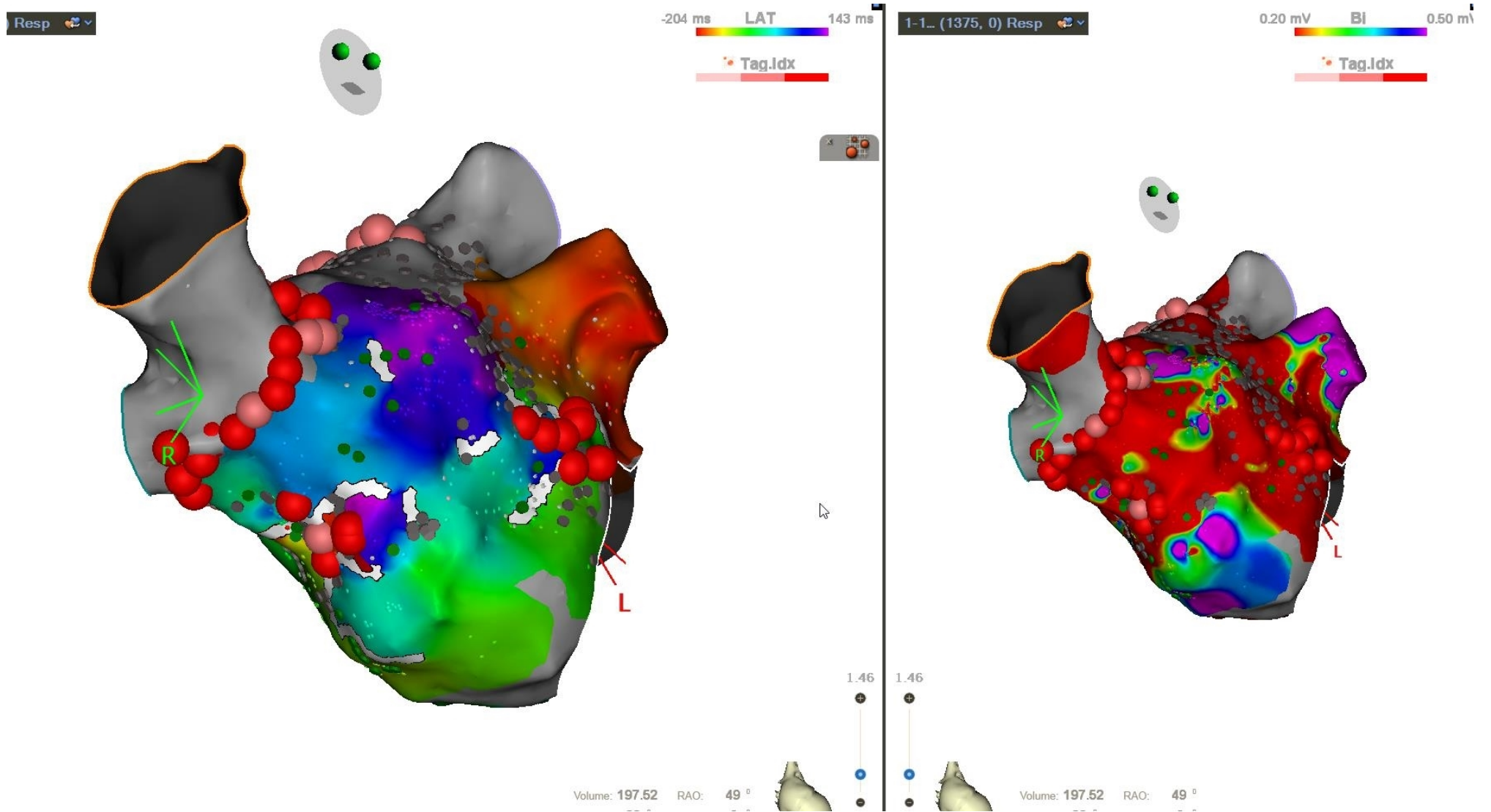
# Flutter G

→ Propag TA3  
OG même  
cycle

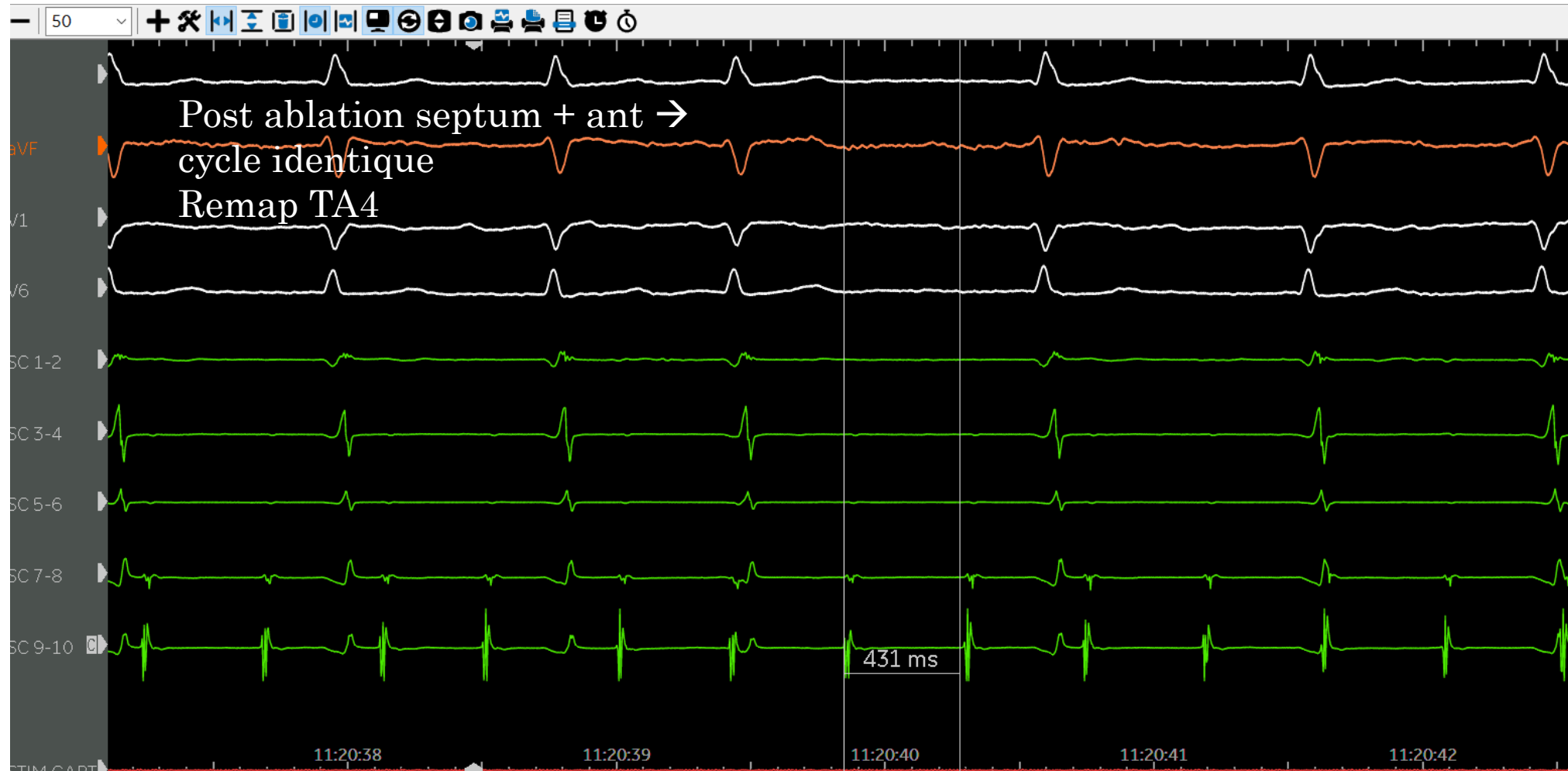


# Flutter G

- Ablation partie ant + septum
- Tjs en tachy
- Remap 3



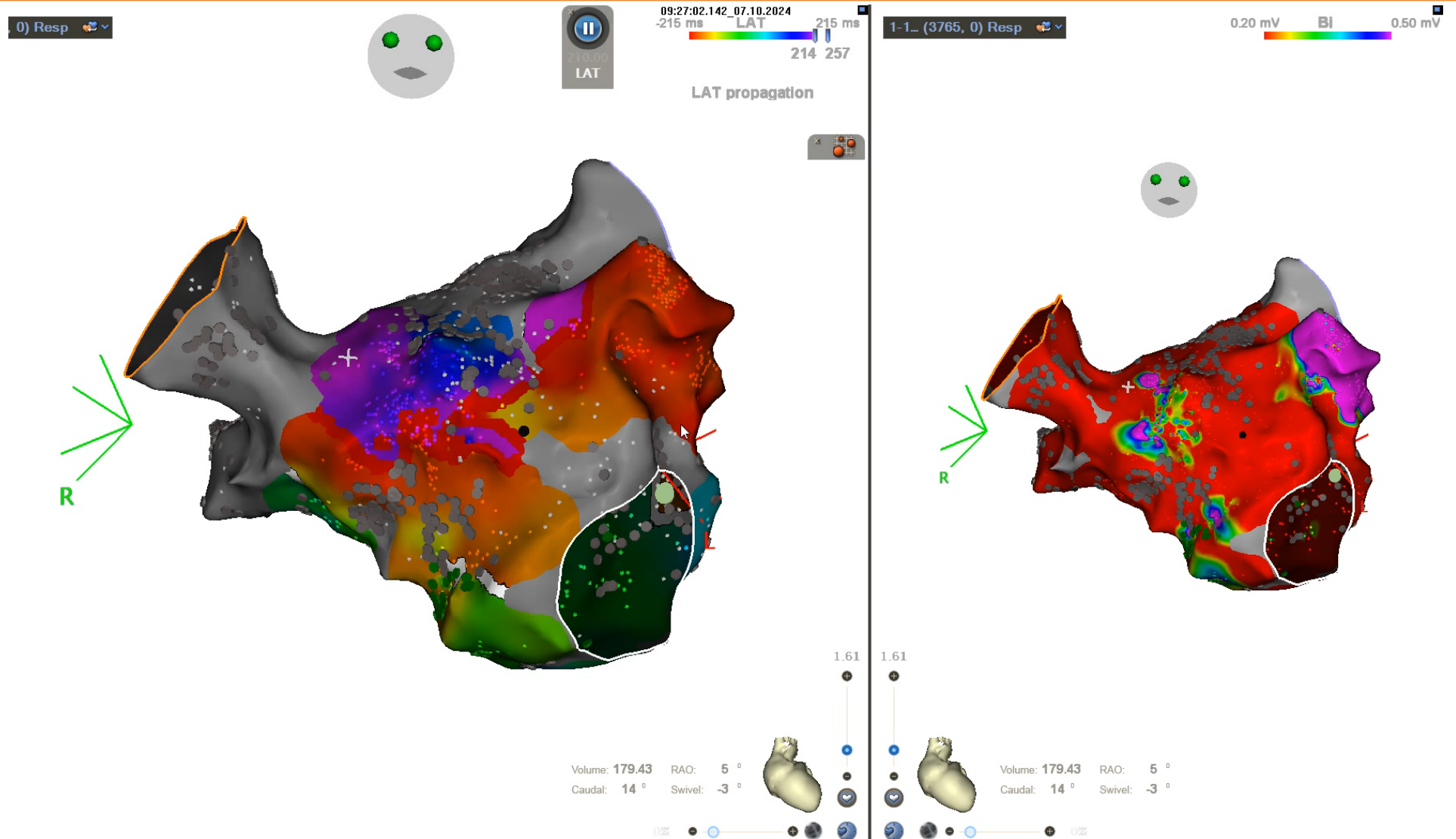
# Flutter G



# Flutter G

→ OG tachy 4

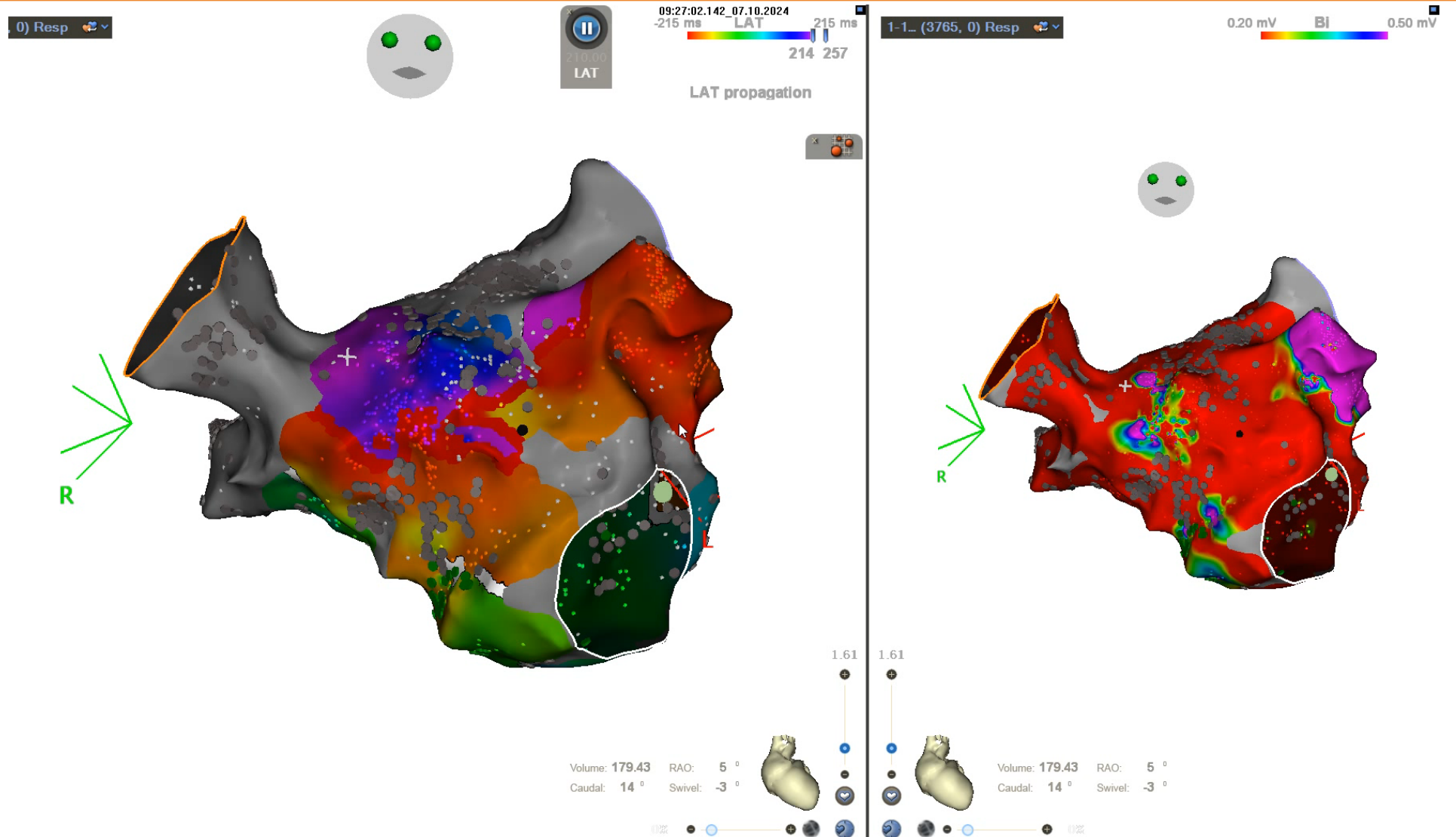
→ Que feriez-vous ?





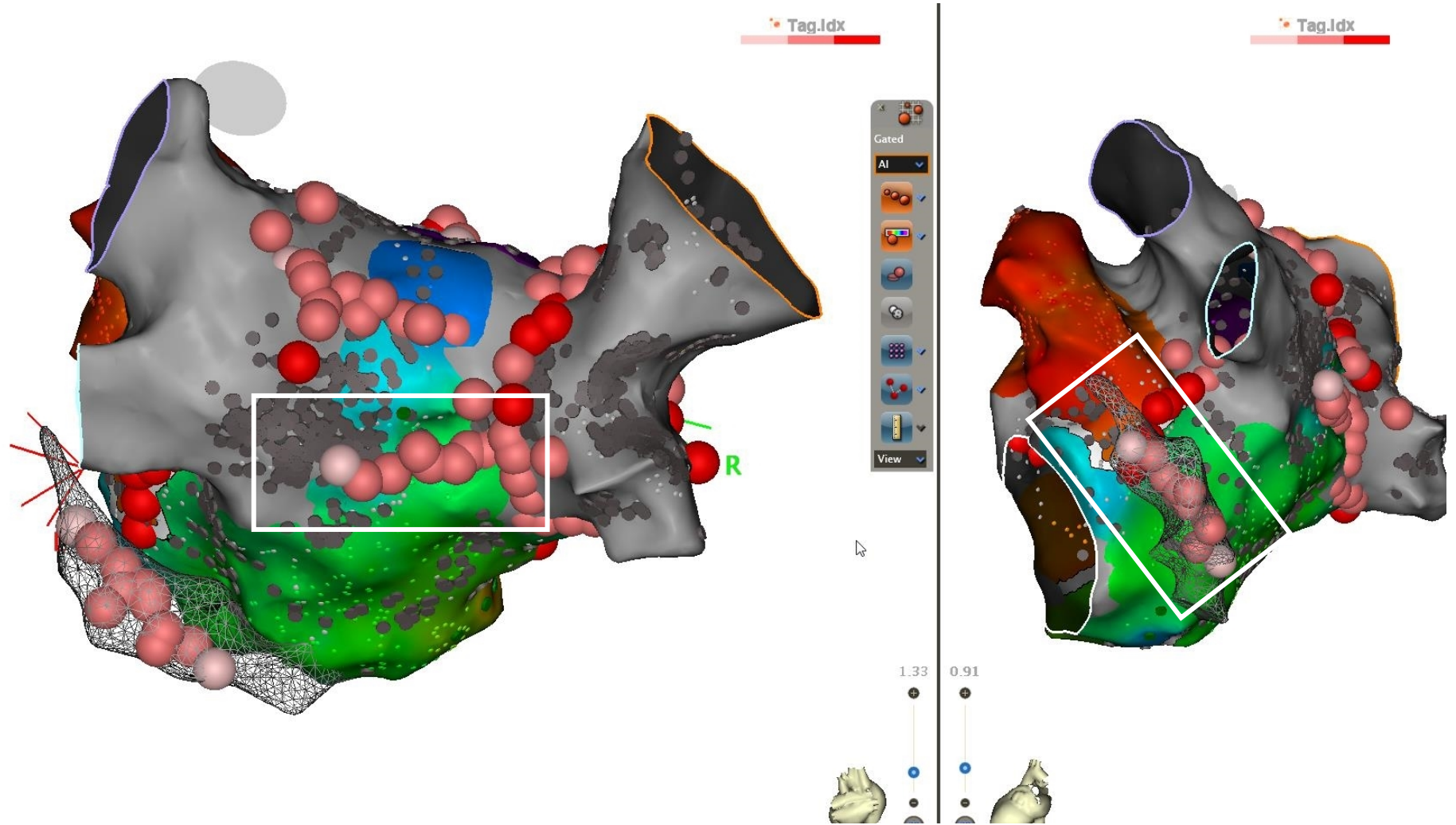
# Flutter G

- OG tachy 4
- Votre avis ?
- Décide de faire complément box + ablation épi CS



# Flutter G

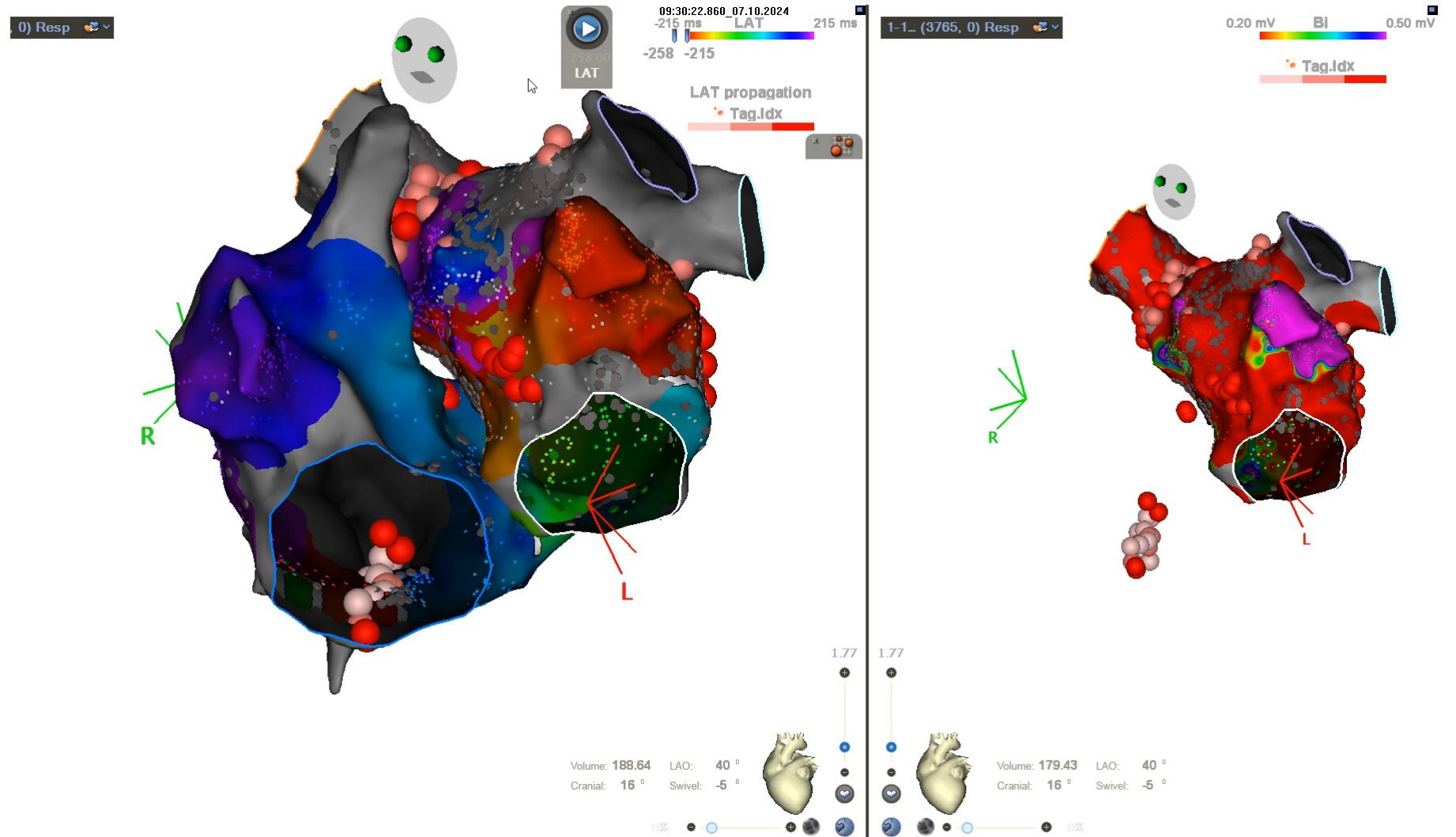
- OG tachy 4
- Tachy toujours identique
- Carte OD



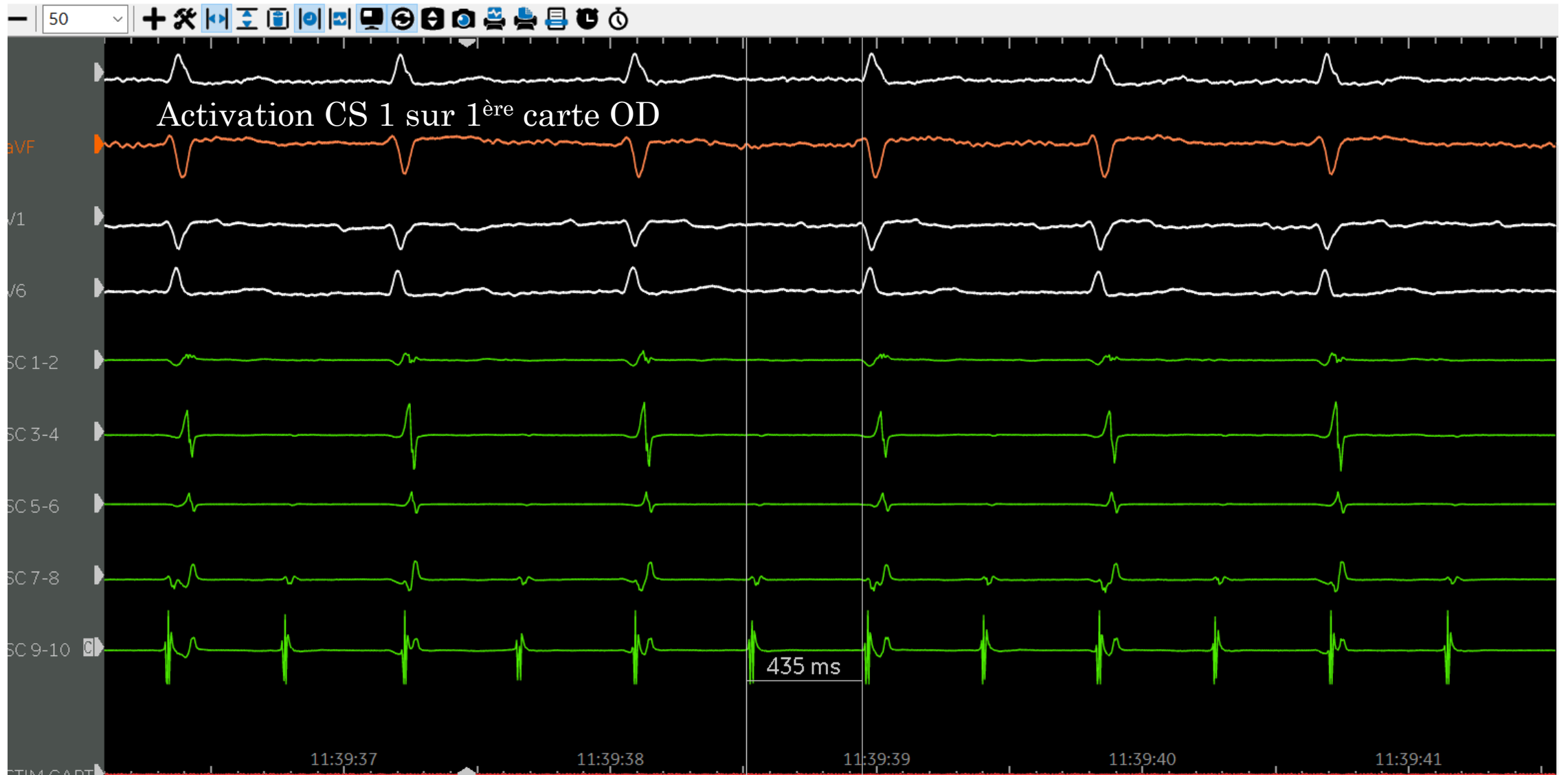
# Flutter G

→ Problème tachy change à droite (même cycle et morphe mais quand revient dans zone déjà mappée, front d'activation change

→ Carte biatriale avec la première TA à droite



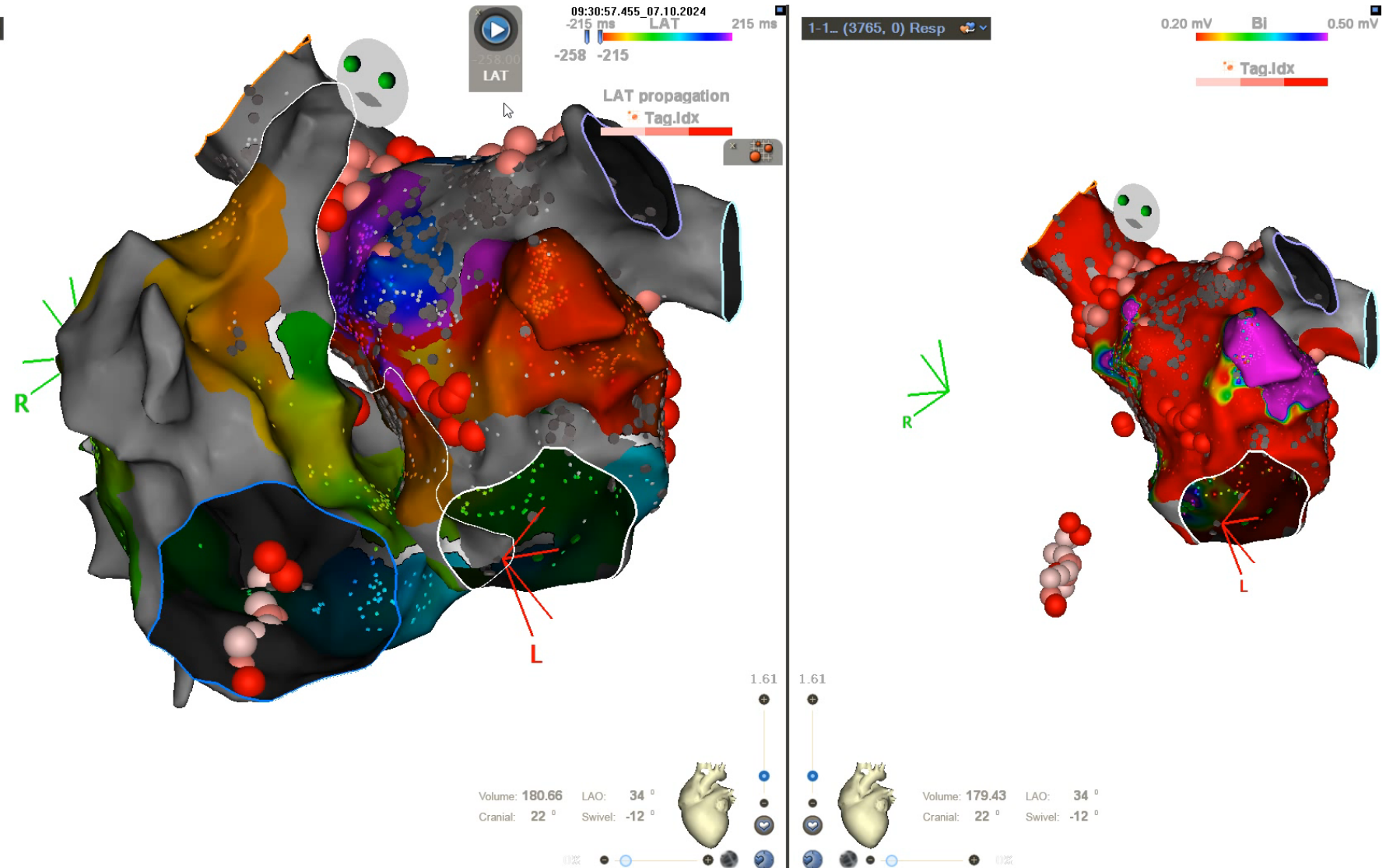
# Flutter G



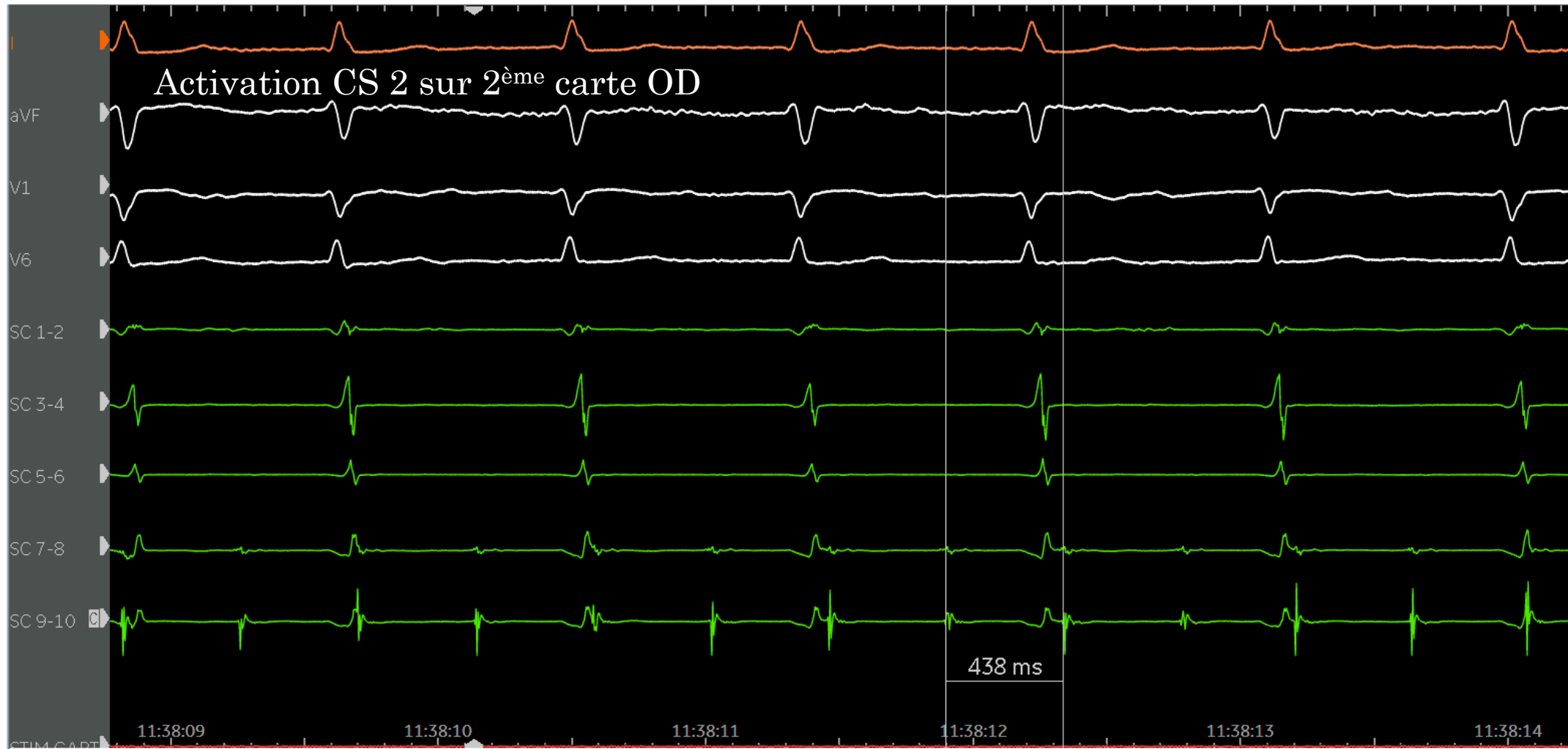
# Flutter G

→ Carte biatriale avec la 2<sup>ème</sup> TA à droite

→ Votre avis ?



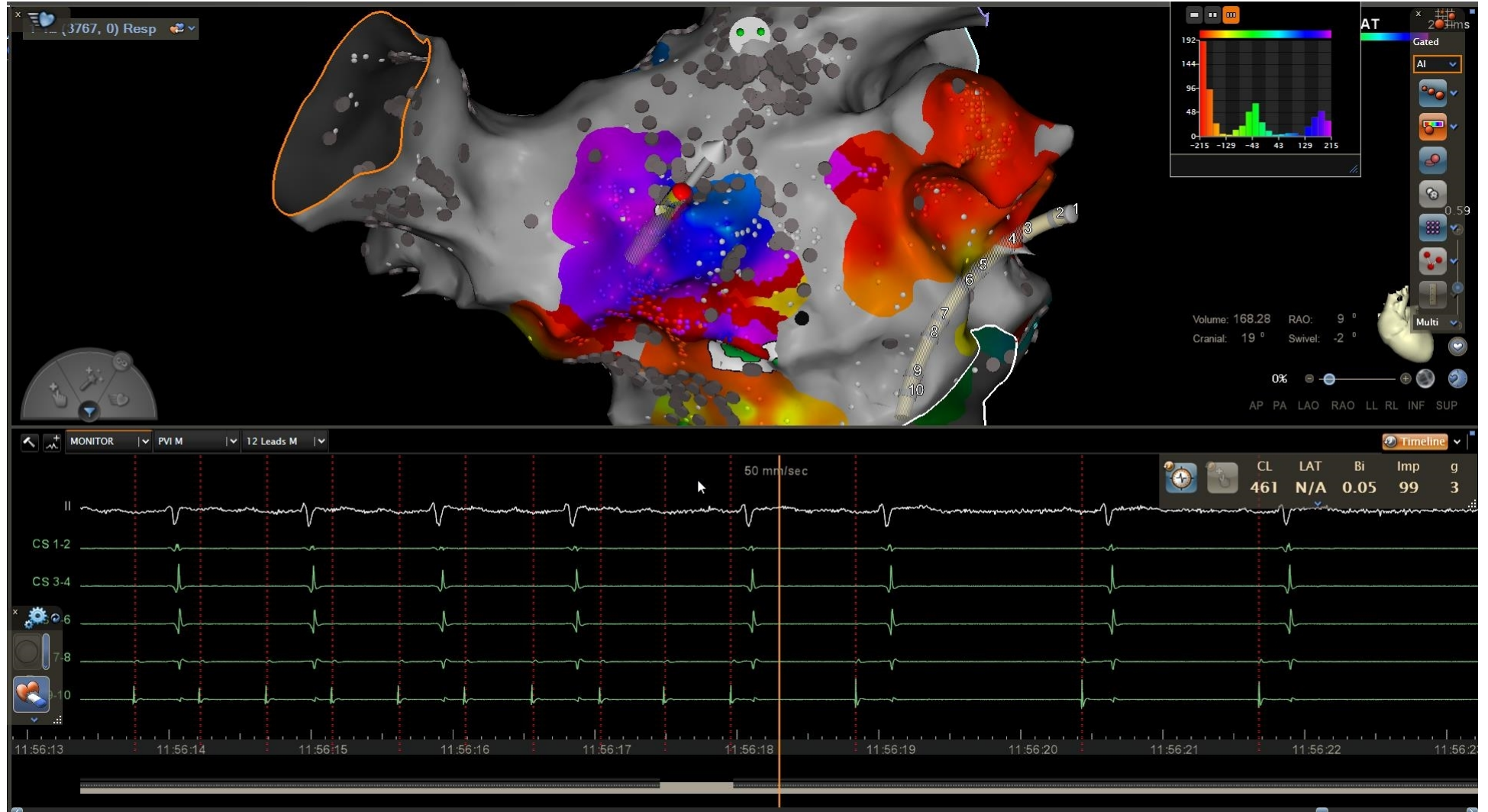
# Flutter G



# Flutter G

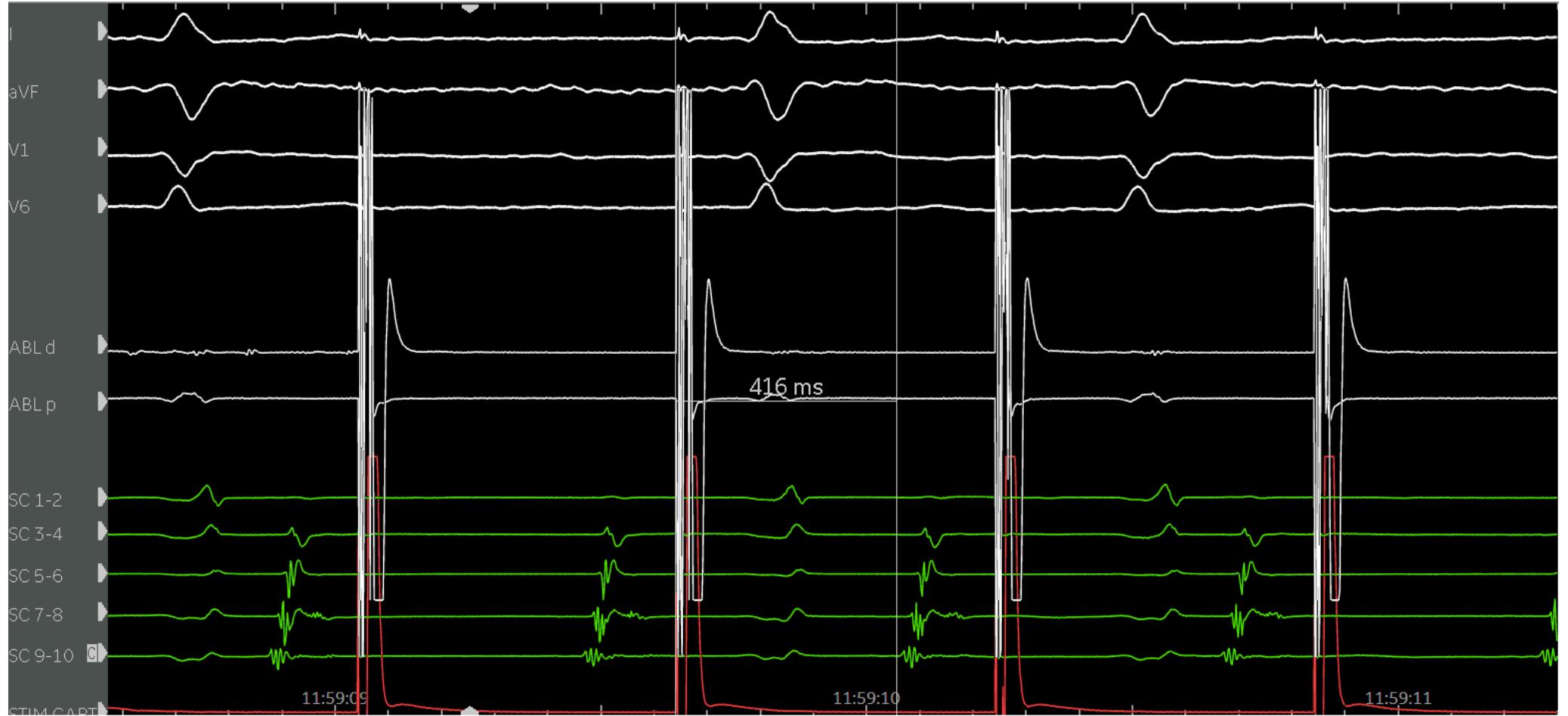→ Ablation sur zone d'émergence en antérieure

→ Retour RS



# Flutter G

- Vérification isthme gauche stim auricule
- Délai de 410 ms et activation prox→dist





# Flutter G

---

→ Merci pour votre attention !