


# Debate Proposition

*That this House believes MVP SCD relates to diffuse myocardial fibrosis*

Greg Mellor MA MD(Res) MRCP

Cardiac Electrophysiologist

Royal Papworth Hospital

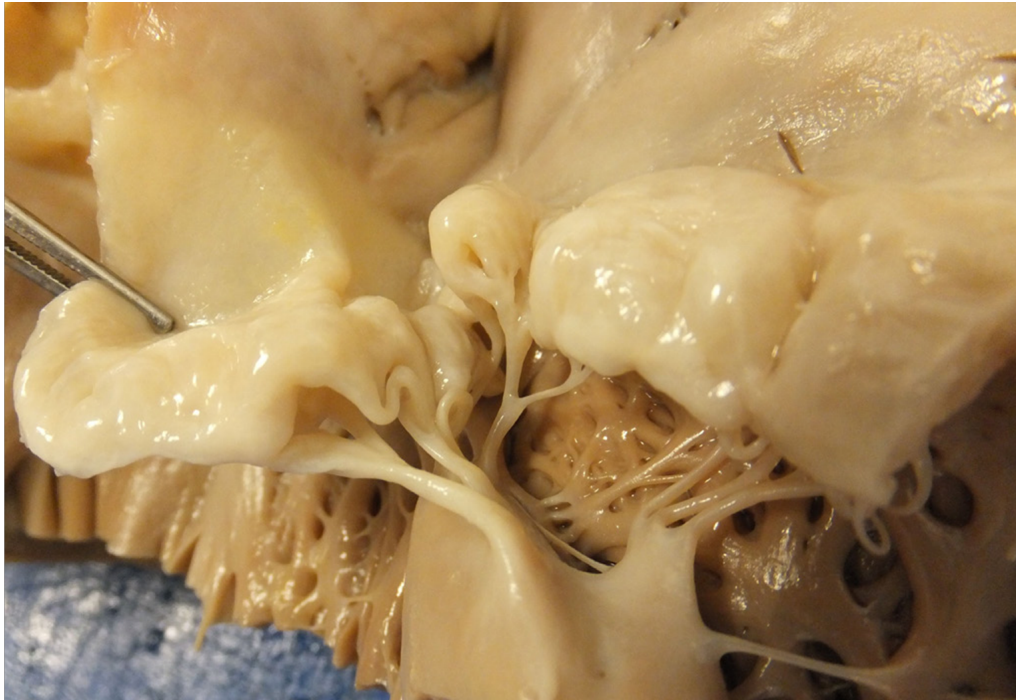

# **Malignant Bileaflet Mitral Valve Prolapse Syndrome in Patients With Otherwise Idiopathic Out-of-Hospital Cardiac Arrest**

Chenni S. Sriram, MBBS,\* Faisal F. Syed, MBChB,† M. Eric Ferguson, MD,\*  
Jonathan N. Johnson, MD,\* Maurice Enriquez-Sarano, MD,† Frank Cetta, MD,\*†  
Bryan C. Cannon, MD,\* Samuel J. Asirvatham, MD,\*† Michael J. Ackerman, MD, PhD\*†‡  
*Rochester, Minnesota*

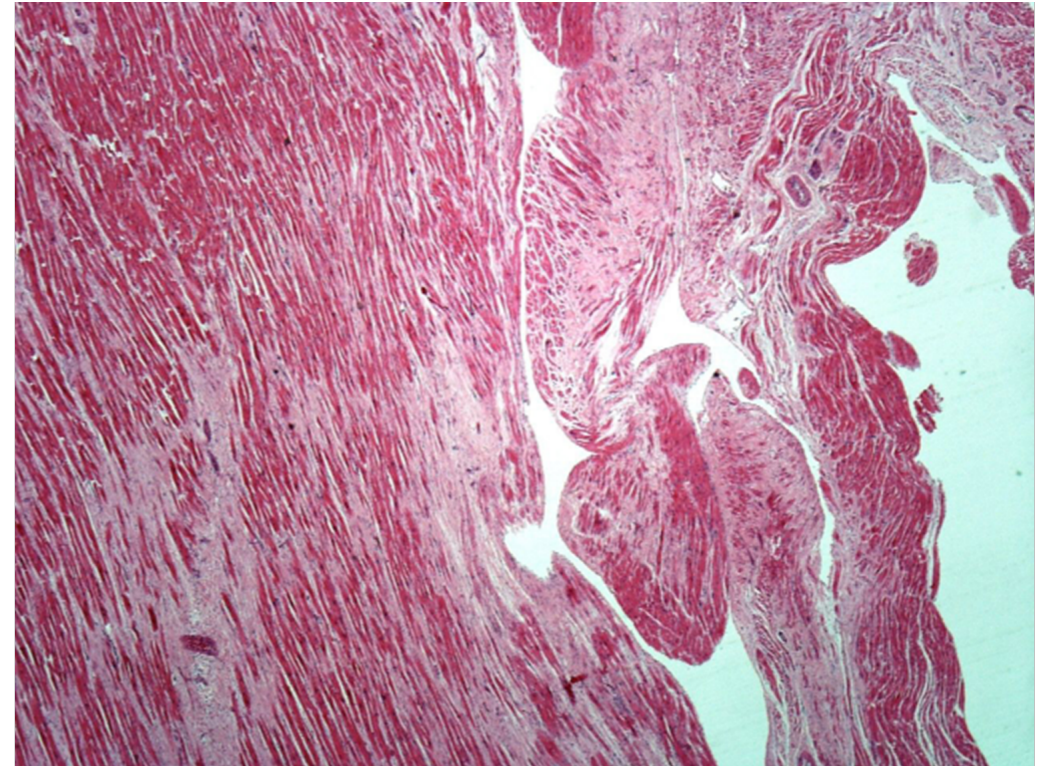
# Mitral valve and left ventricular features in malignant mitral valve prolapse

Madalina Garbi,<sup>1</sup> Patrizio Lancellotti,<sup>2,3</sup> Mary N Sheppard<sup>4</sup>



**Figure 1** Barlow mitral valve with thickening and ballooning of the leaflets in between the chords and thickening and elongation of the chords.

N=68 sudden death, no other cause

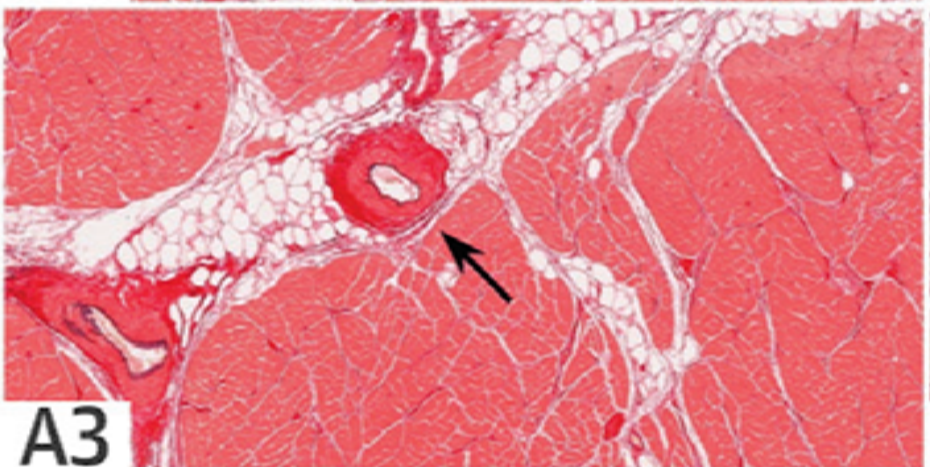


**Figure 2** Ventricular fibrosis in Barlow disease.

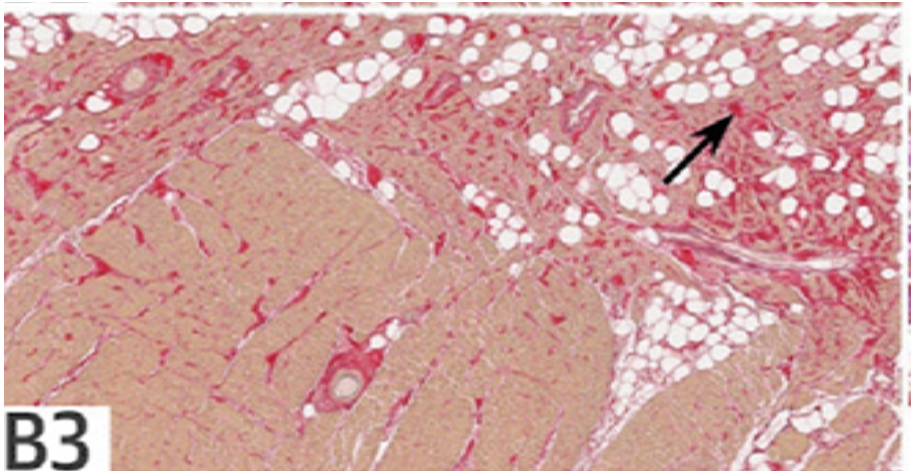
# Fibrosis, Connexin-43, and Conduction Abnormalities in the Brugada Syndrome



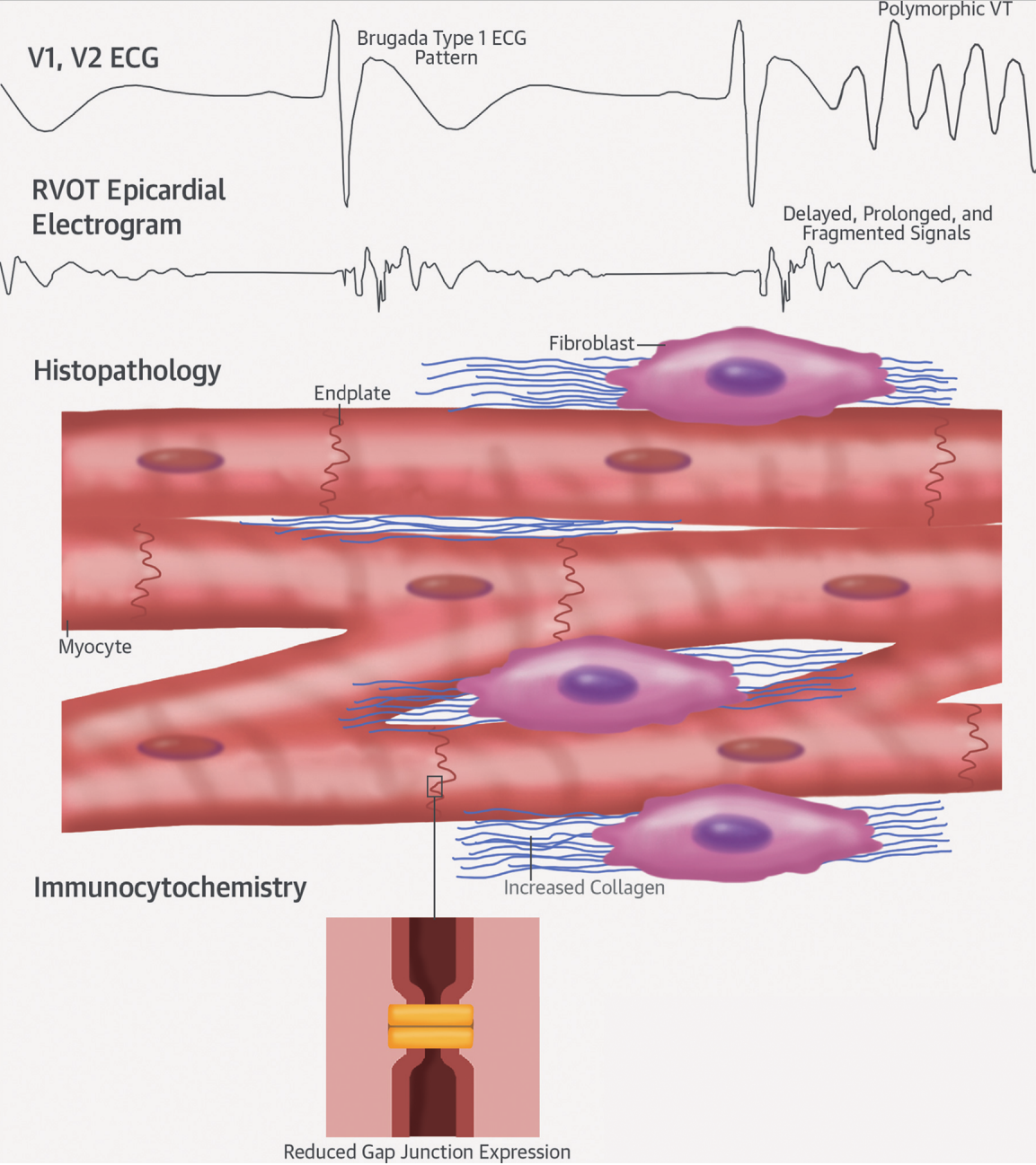
Koonlawee Nademanee, MD,\* Hariharan Raju, PhD,† Sofia V. de Noronha, PhD,† Michael Papadakis, MD,† Laurence Robinson, MBBS,† Stephen Rothery, BSc,† Naomasa Makita, MD,§ Shinya Kowase, MD,|| Nakorn Boonmee, MD,¶ Vorapot Vitayakitsirikul, MD,¶ Samrerng Ratanarapee, MD,# Sanjay Sharma, MD,† Allard C. van der Wal, MD,\*\* Michael Christiansen, MD,†† Hanno L. Tan, MD,\*\* Arthur A. Wilde, MD,\*\*‡‡ Akihiko Nogami, MD,§§ Mary N. Sheppard, MD,† Gumpant Veerakul, MD,¶ Elijah R. Behr, MD†

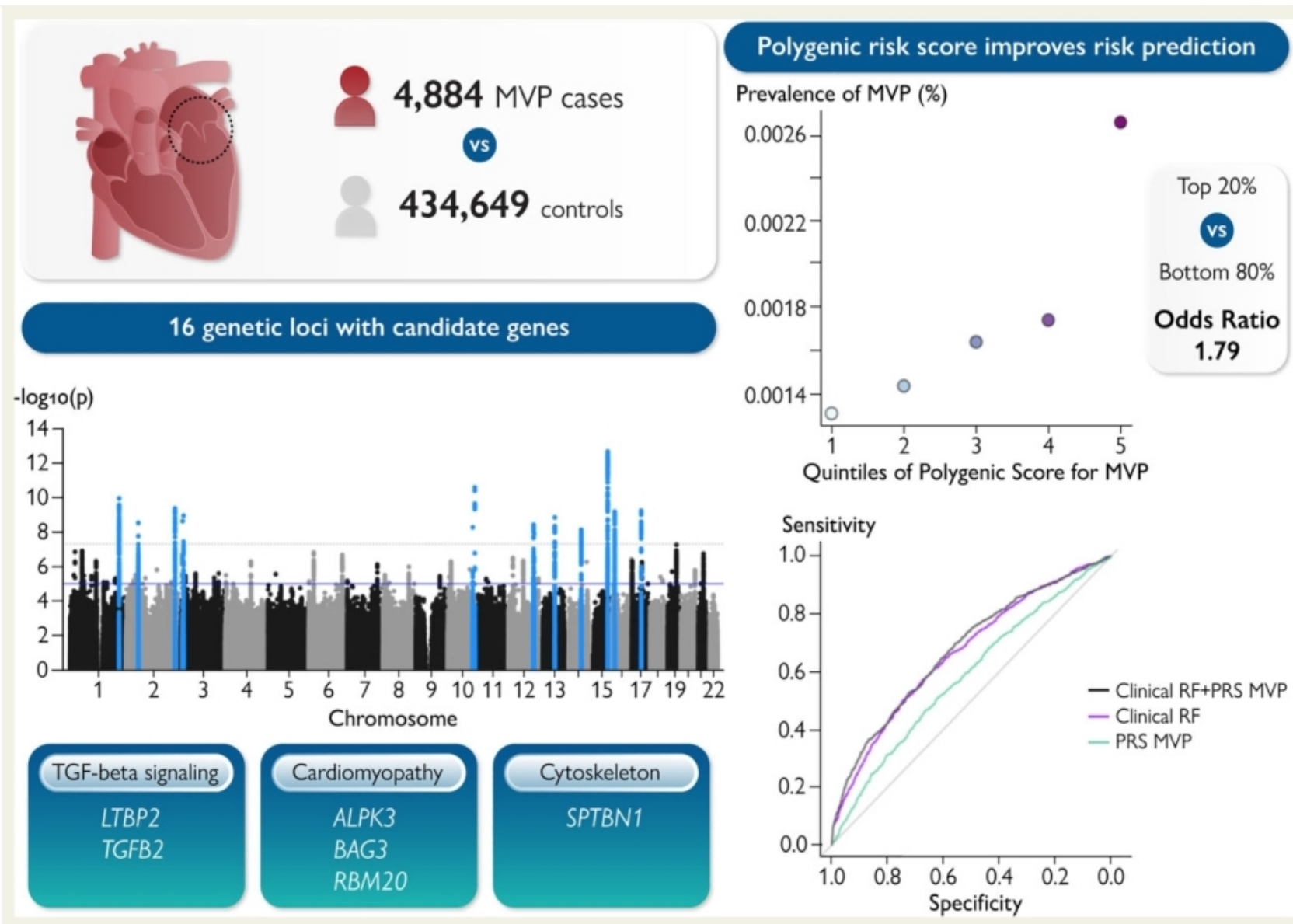


control



Brugada





# TGF-Beta signalling pathway: "central mediator of fibrogenesis"

