

Multiple valve disease and staged interventional management: a high-risk patient with a bioprosthetic aortic valve dysfunction and mitral regurgitation

Vlatka Reskovic Luksic^{1*}, Sandra Jaksic Jurinjak¹, Josko Bulum¹, Martina Lovric Bencic¹, Blanka Glavas Konja¹, Marija Brestovac¹, Zvonimir Ostojic¹, Ivica Safradin², Kristina Krzelj², Karlo Gjuras³, Hrvoje Gasparovic², Jadranka Separovic Hanzevacki¹

¹Department of Cardiovascular Diseases, School of Medicine, University Hospital Centre Zagreb, Kispaticeva 12, 10000, Zagreb, Croatia, ²Department of Cardiovascular Surgery, School of Medicine, University Hospital Centre Zagreb, Kispaticeva 12, 10000, Zagreb, Croatia, ³School of Medicine, University of Zagreb, Salata 2, 10000, Zagreb, Croatia

Background. In patients with multiple valve disease (MVD) and high surgical risk, sequential interventional approach is often reasonable (1): transcatheter aortic valve-in-valve implantation (TAVI ViV) is an option for treating degenerated bioprosthetic heart valves (BHV), and in patients who are not eligible candidates for transcatheter edge-to-edge repair (TEER), transcatheter mitral valve replacement (TMVR) is a viable option (2,3).

Case report. 65y old male was referred to UHC Zagreb in 8/2022 due to heart failure (HF) with reduced left ventricular ejection fraction (LVEF 30%), aortic BHV degeneration (severe aortic stenosis with mild paravalvular and moderate valvular aortic regurgitation (AR)) and severe mitral and tricuspid regurgitation. The patient also had multiple comorbidities: end-stage renal disease (on peritoneal dialysis since 2019), COPD, toxic liver lesion. Previously he underwent BHV implantation in 2017 due to endocarditis with destruction of the bicuspid aortic valve (AV), AR and HF.

At the time, due to prohibitive surgical risk, re-do surgery was denied. After hemodynamic stabilization and volume optimization (hemodialysis), the decision of the Heart team was to perform TAVI ViV. Clinical improvement after TAVI was significant, despite patient-prosthesis mismatch and severe complex MR (degenerative mitral valve disease with the component of the secondary MR - EROA 0,3 cm², RVol 65 ml). Intervention on the MV was proposed by the Heart team - the patient was not the candidate for TEER because of the pronounced calcification of the MV leaflets, so he was scheduled for TMVR in 7/2023. The procedure underwent without complications (MPG 6-7mmHg with the trace of the paravalvular MR, Figure 1) and the patient was doing well in 1-month follow up.

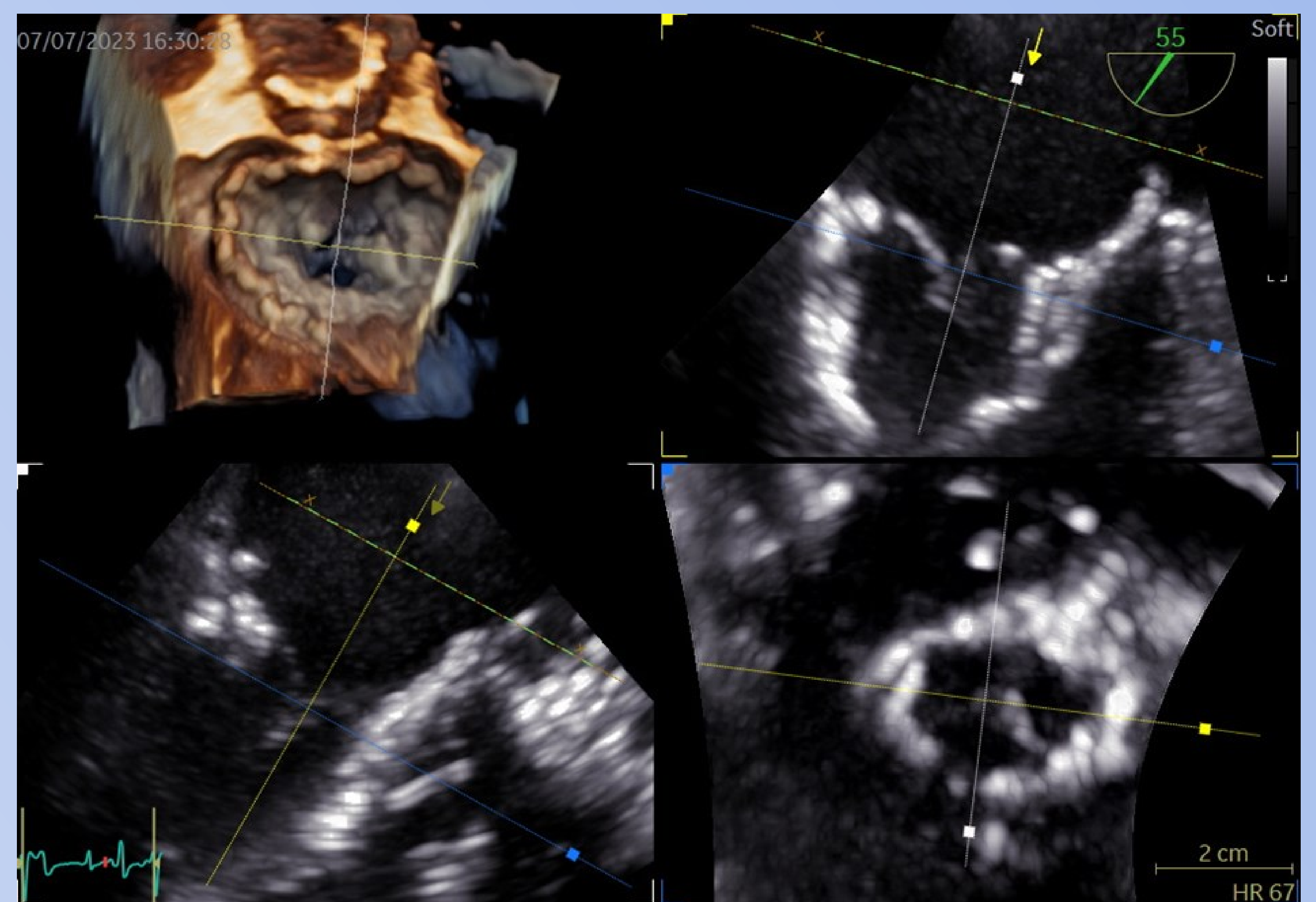


Figure 1. 3D transesophageal echocardiography recorded during TMVR, showing a good position of the valve after deployment.

Conclusion. Interventional options allow individualized and staged approach in patients with comorbidities and high operative risk. Long-term durability of TMVR is yet to be determined (2).

Literature:

1. Vahanian A, Beyersdorf F, Praz F et al. 2021 ESC/EACTS Guidelines for the management of valvular heart disease: Developed by the Task Force for the management of valvular heart disease of the European Society of Cardiology (ESC) and the European Association for Cardio-Thoracic Surgery (EACTS). *Eur Heart J.* 2022 Feb 14;43(7):561-632.
2. Muller DWM, Sorajja P, Duncan A et al. 2-Year Outcomes of Transcatheter Mitral Valve Replacement in Patients With Severe Symptomatic Mitral Regurgitation. *J Am Coll Cardiol.* 2021 Nov 9;78(19):1847-1859. doi: 10.1016/j.jacc.2021.08.060.
3. Niikura H, Gössl M, Sorajja P. Transcatheter Mitral Valve Replacement with Tendyne. *Interv Cardiol Clin.* 2019 Jul;8(3):295-300. doi: 10.1016/j.iccl.2019.02.003. Epub 2019 Apr 6. PMID: 31078185.