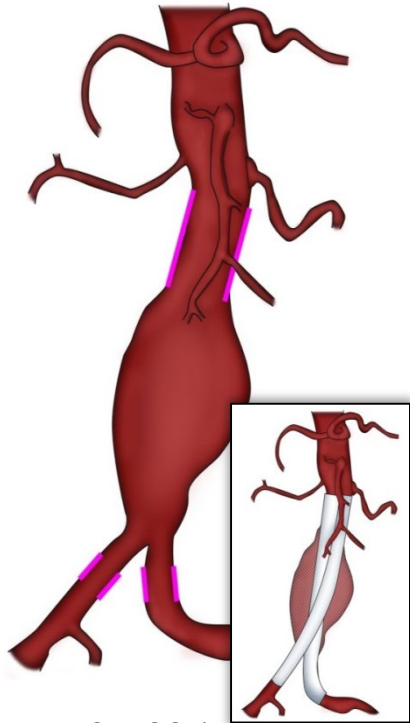


UNE IMPASSE AORTIQUE ?

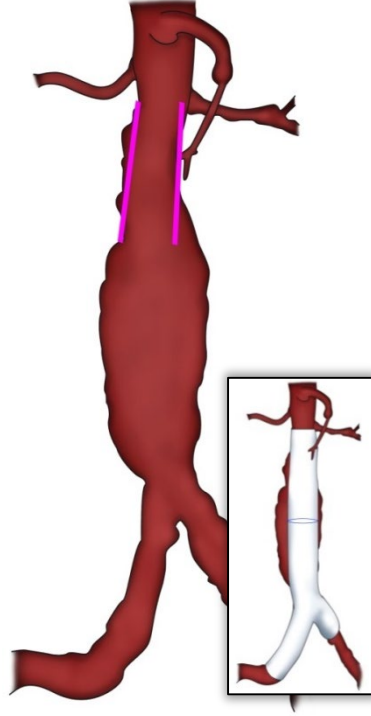
Claude MIALHE,
Monaco



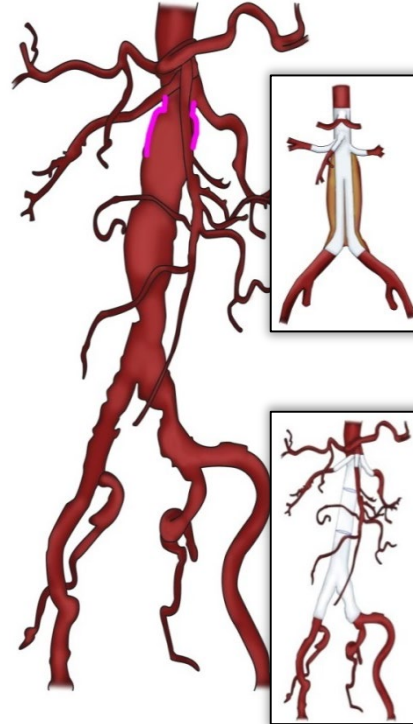
EVOLUTION RELATED CLASSIFICATION OF AAAS



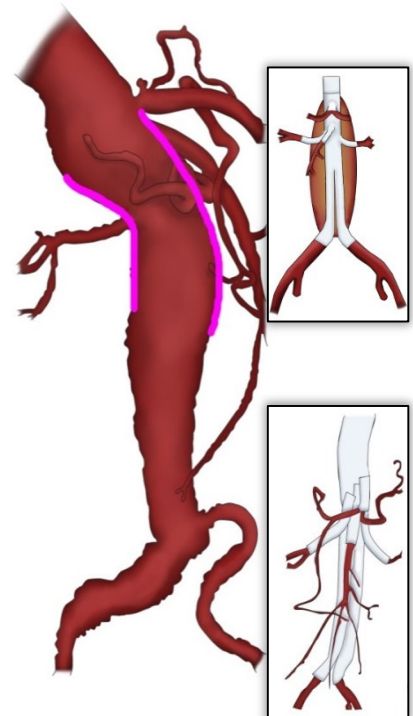
CLASS 1



CLASS 2



CLASS 3



CLASS 4

Options to achieve proximal sealing zone during endovascular repair of abdominal aortic aneurysm and correlated classification

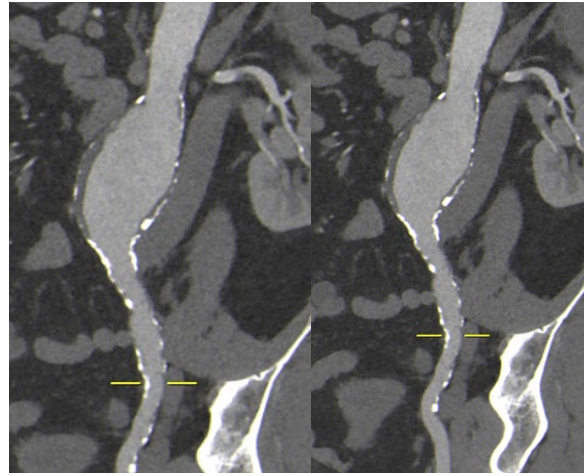
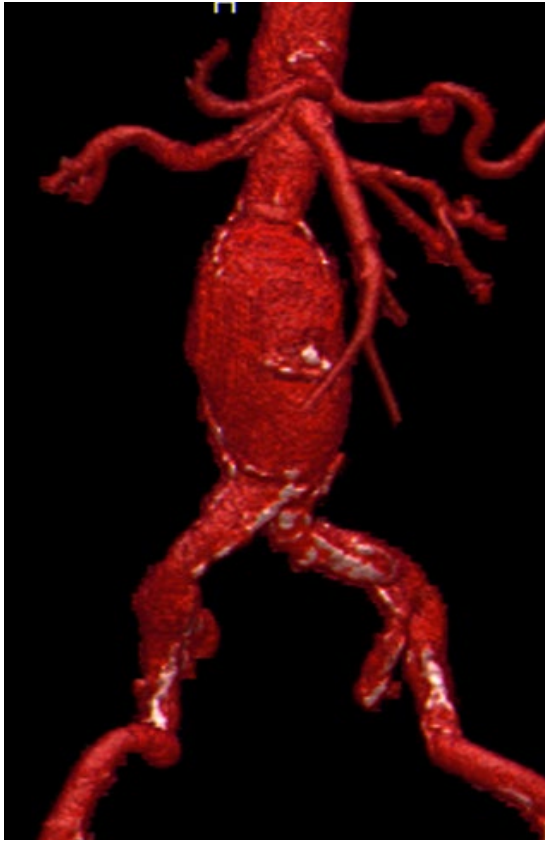Claude Mialhe, Fabien Lareyre¹, Juliette Raffort

First Published July 23, 2019 | Article Commentary |

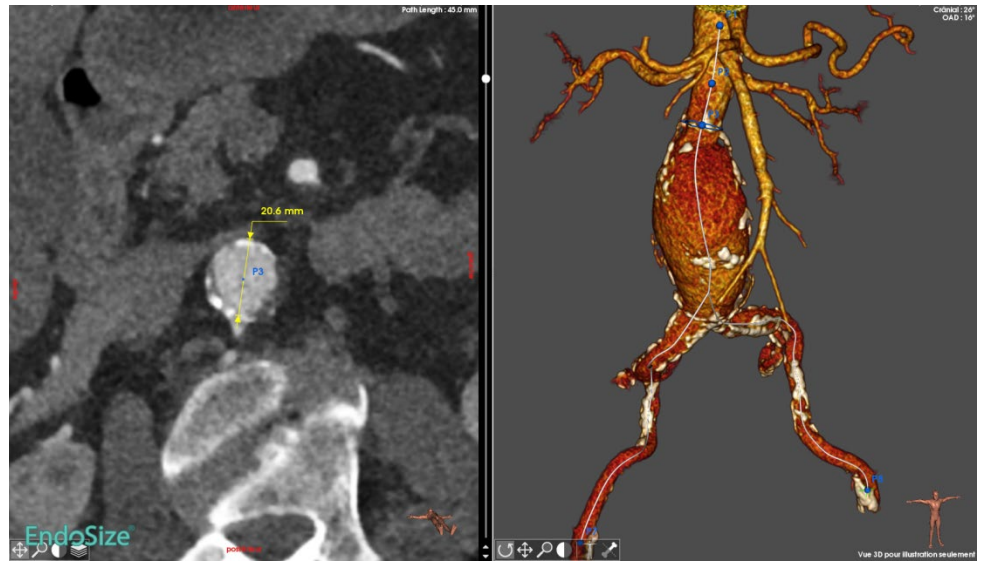


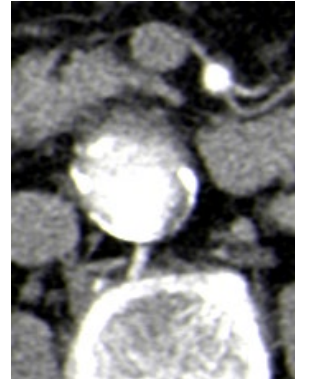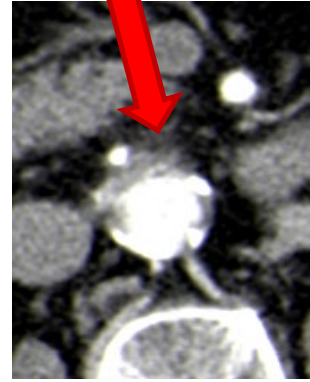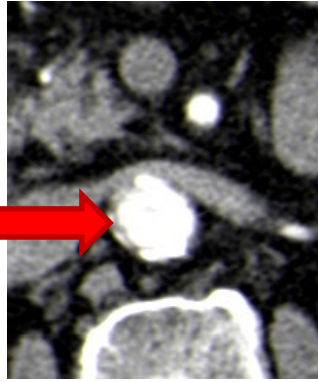
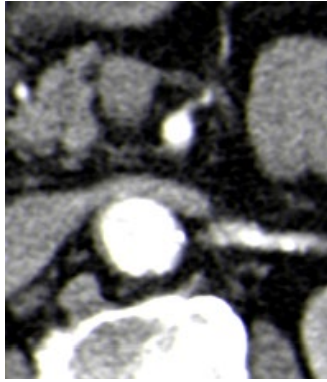
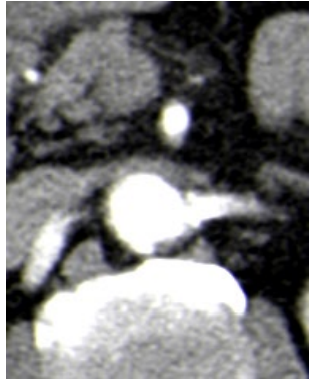Vascular and
Endovascular Surgery

<https://doi.org/10.1177/1708538119864740>

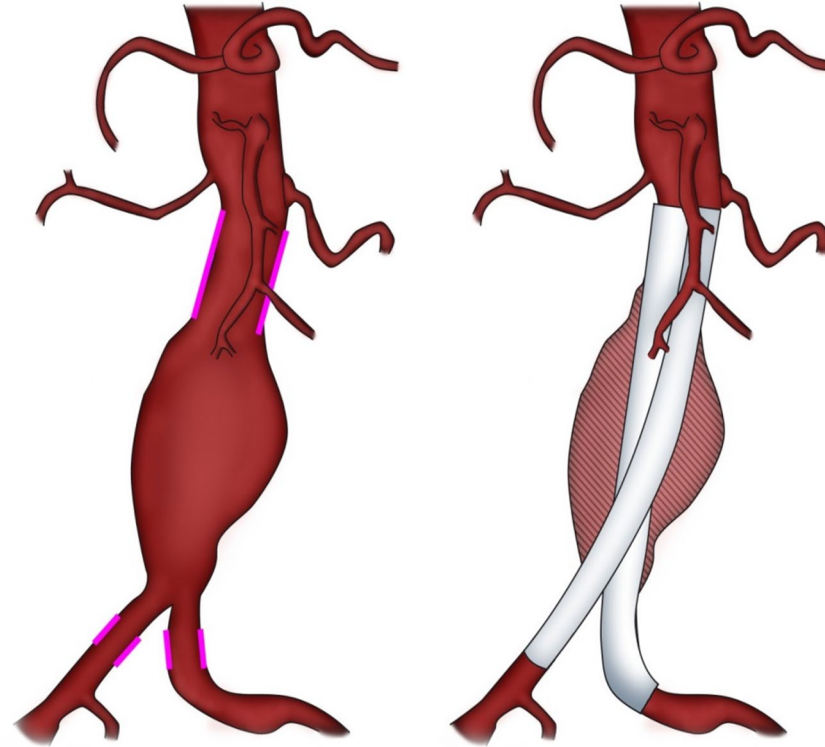


Male
68 ans



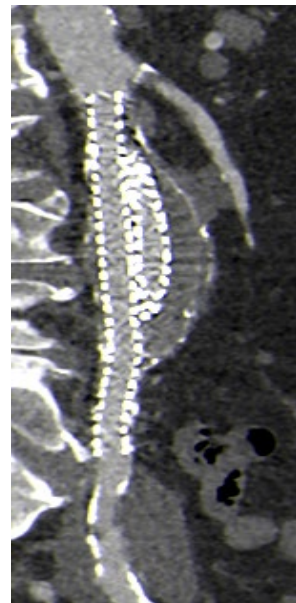
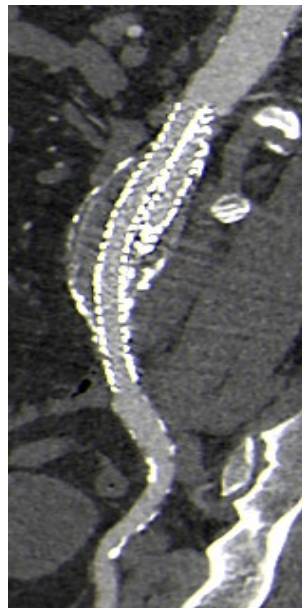
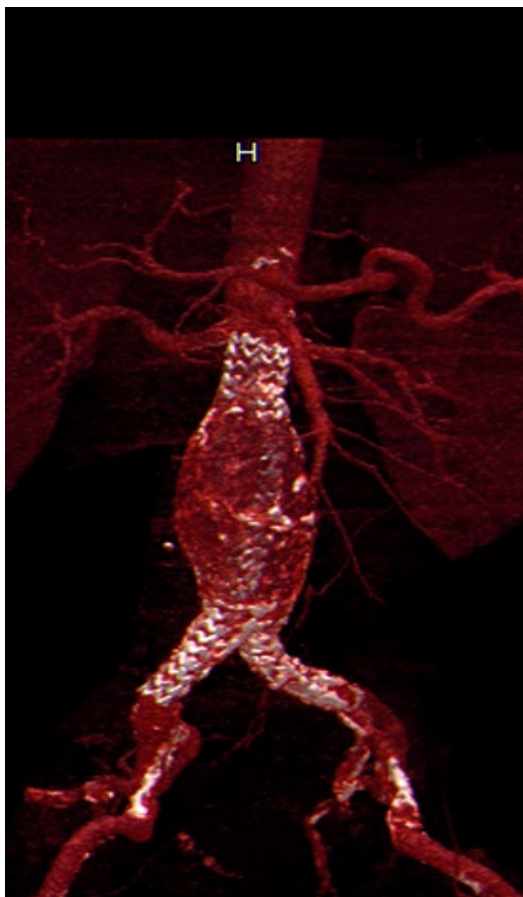


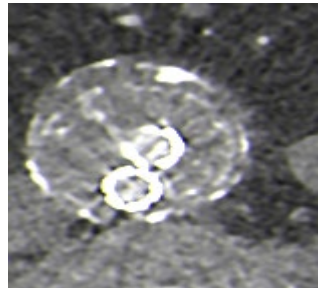
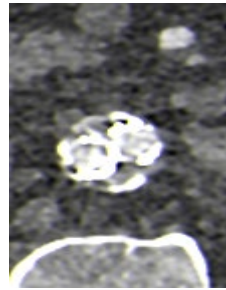
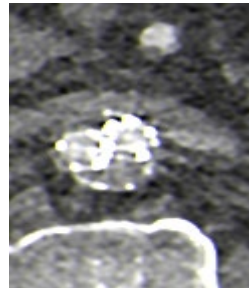
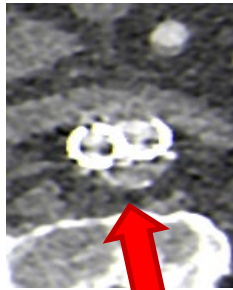
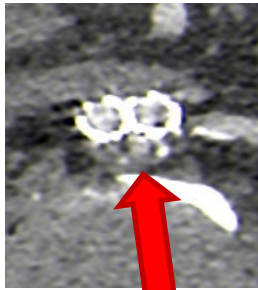
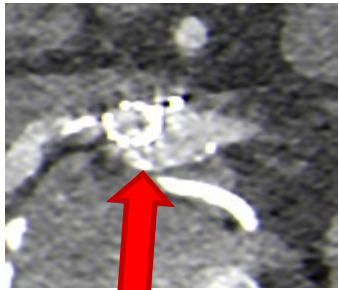
EVOLUTION RELATED CLASSIFICATION OF AAAS



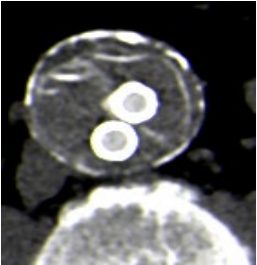
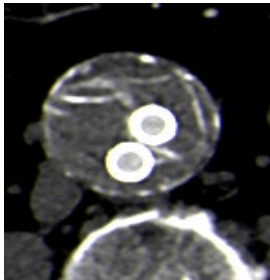
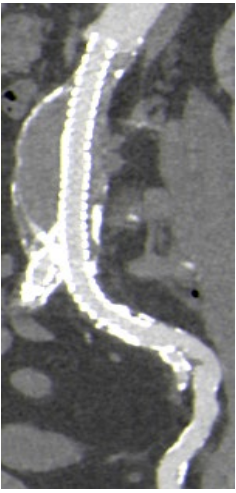
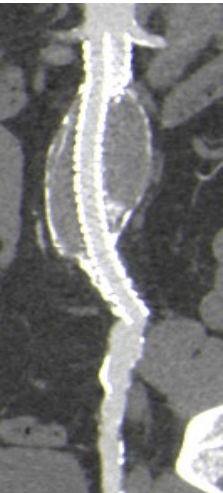
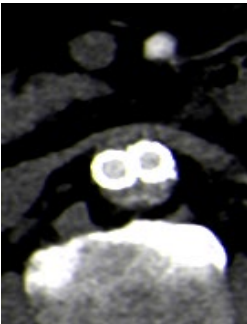
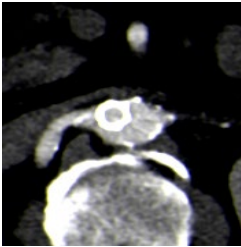
CLASS 1

1 an

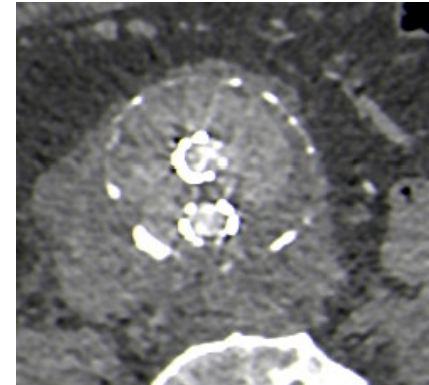
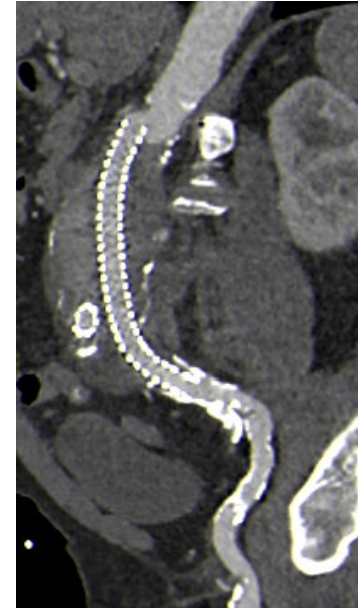
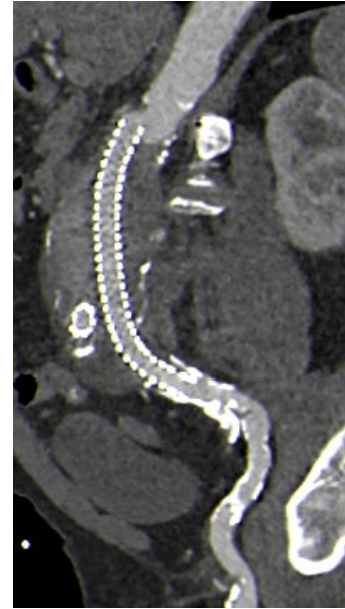
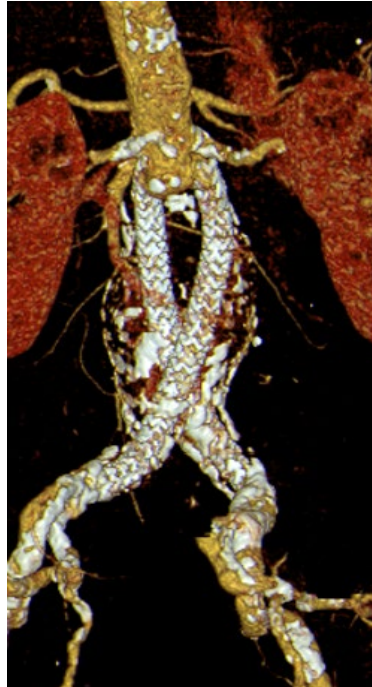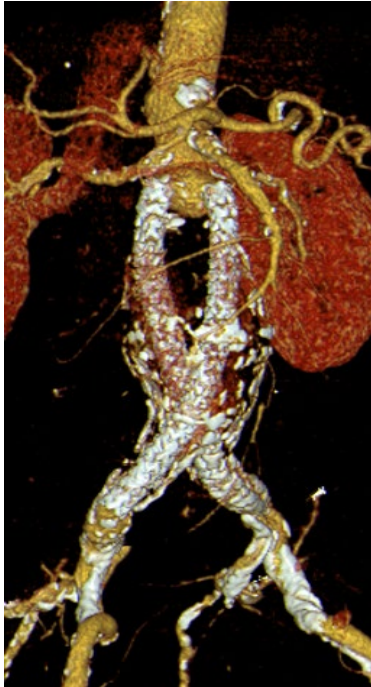




1,5 an



6 ans



Myelodysplasie

Thrombopénie: 43000

Leucopénie

Merci de noter que Nellix ne sera disponible que pour un usage dans le cadre d'un protocole clinique qui respecte les indications actuelles.

De ce fait, nous aurions besoin, au plus tôt possible, du Scan CT pour qu'un conseil de médecins puisse l'examiner et déterminer si Nellix est bien l'option endovasculaire convenable au précédent Nellix échoué.

Si le cas est jugé approprié, nous allons procéder à l'usage compassionnel, Mr T. va confirmer et effectuer une recherche concernant le processus spécifique pour Monaco.

Pour l'utilisation compassionnelle, nous aurions besoin de recueillir les éléments suivants:

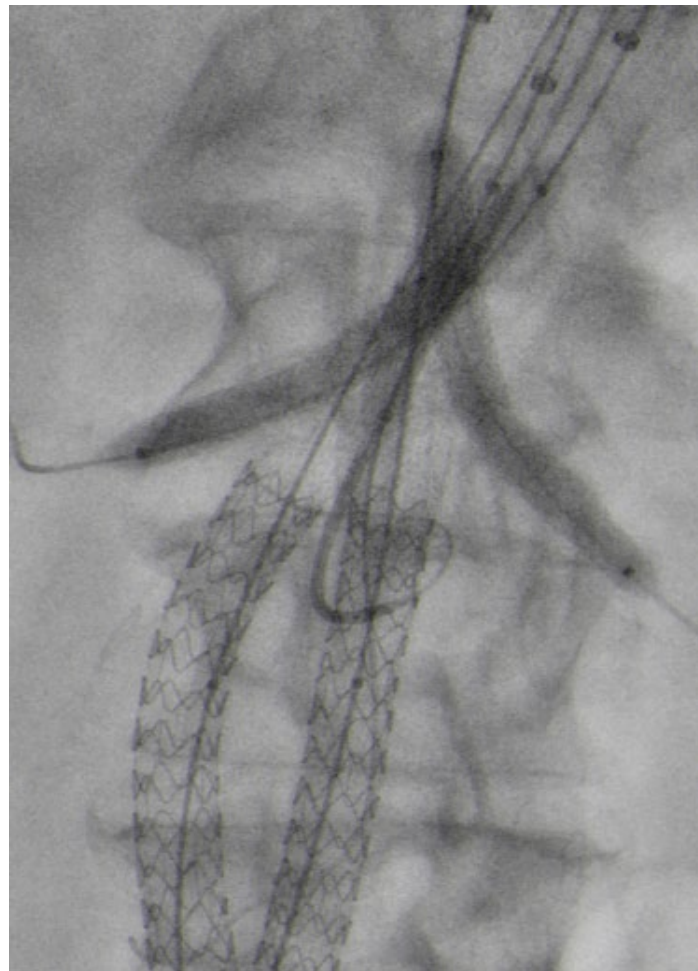
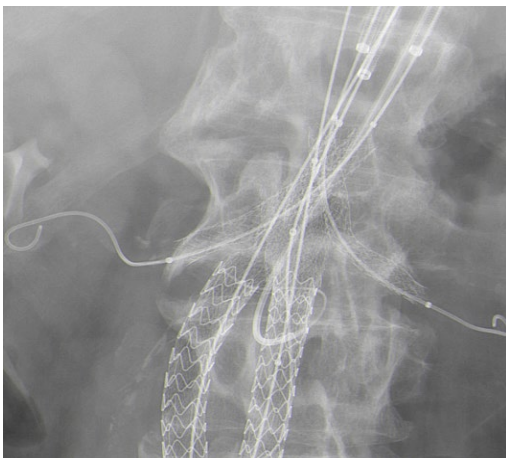
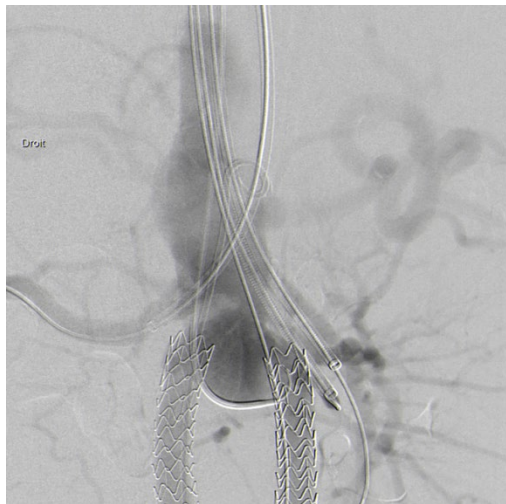o Tarification de l'implant

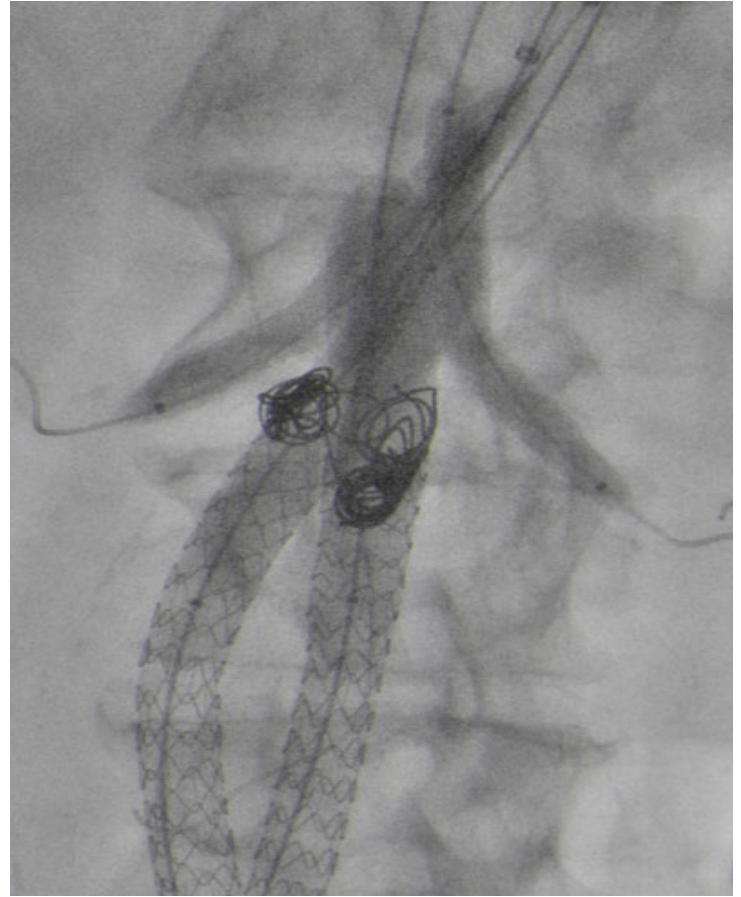
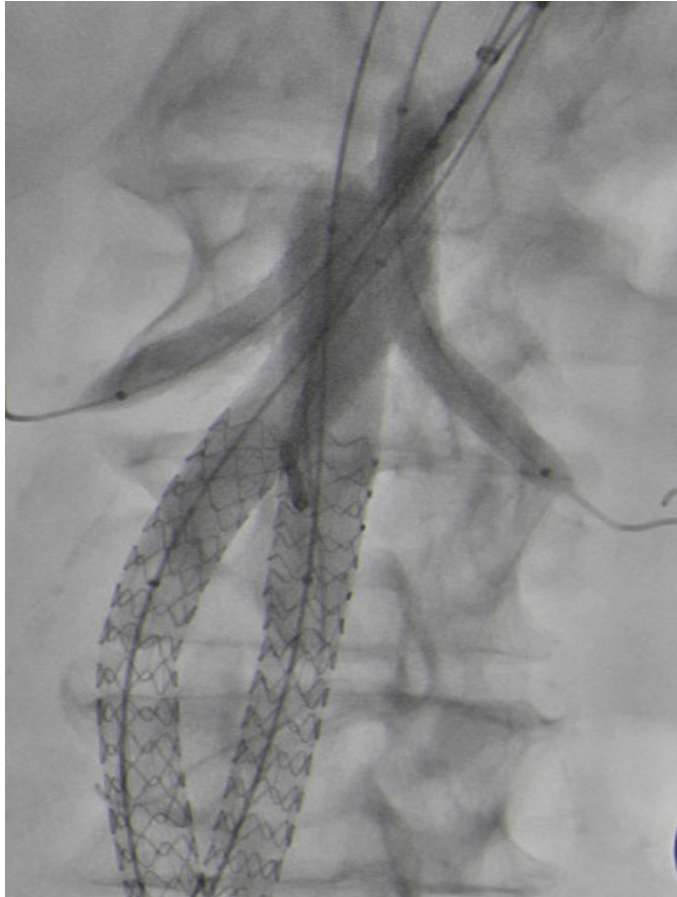
o Lettre du médecin demandant Nellix pour un patient ayant déjà une Nellix échouée.

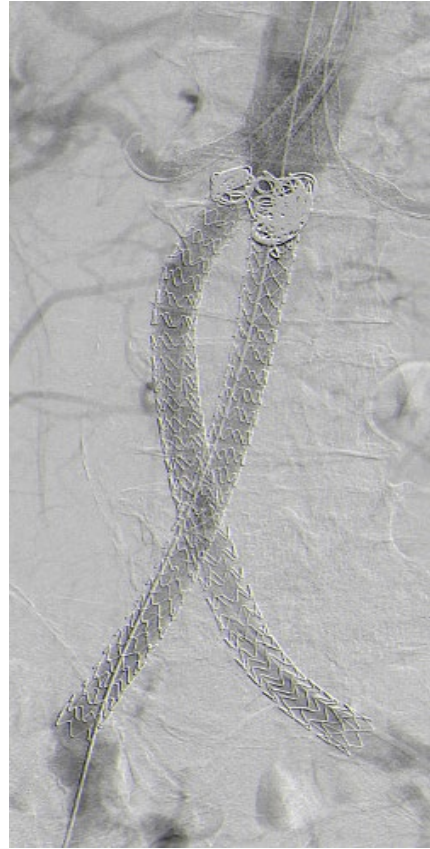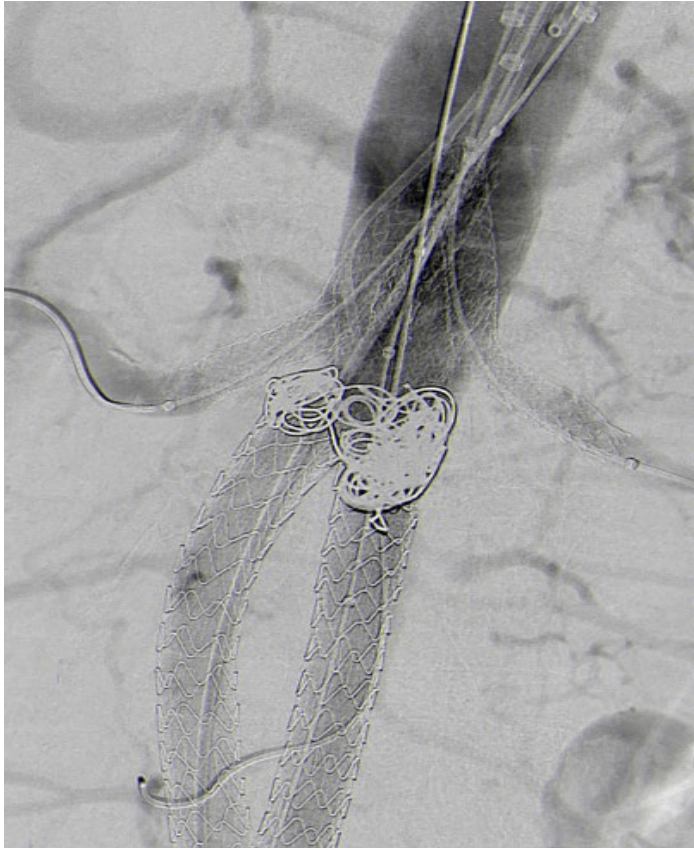o Formulaire d'accusé de réception du médecin hors IFU (v) daté et signé

Extensions:
Viabhan

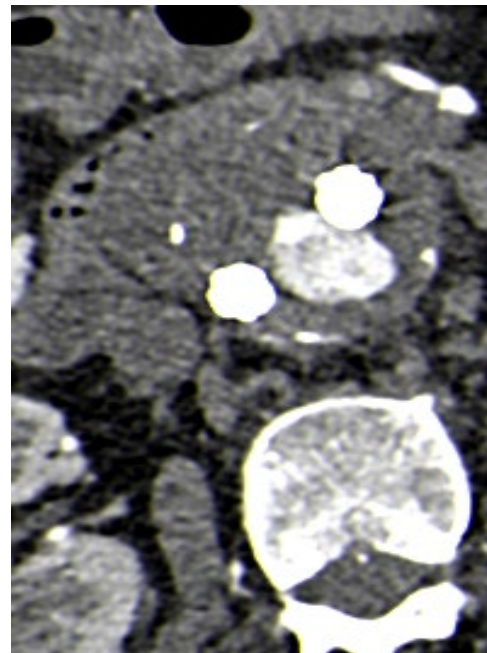
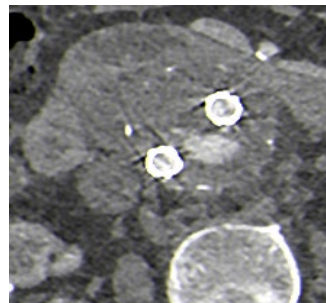
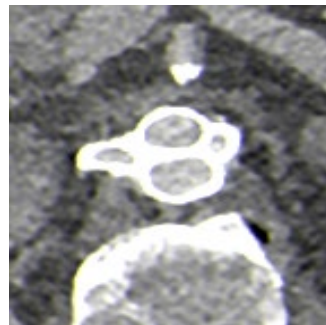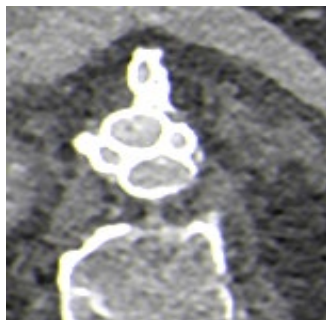
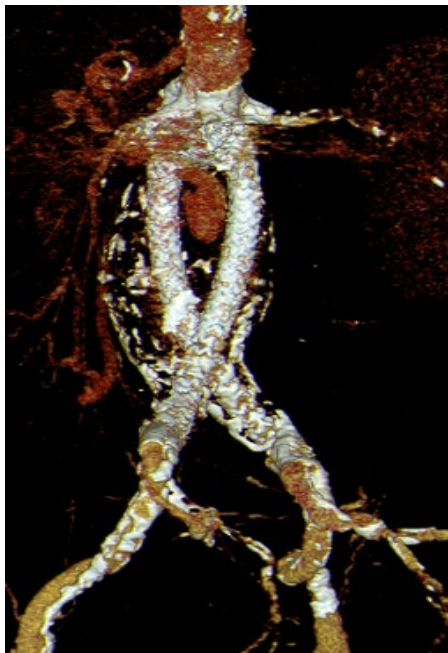
Cheminées:
Bentley



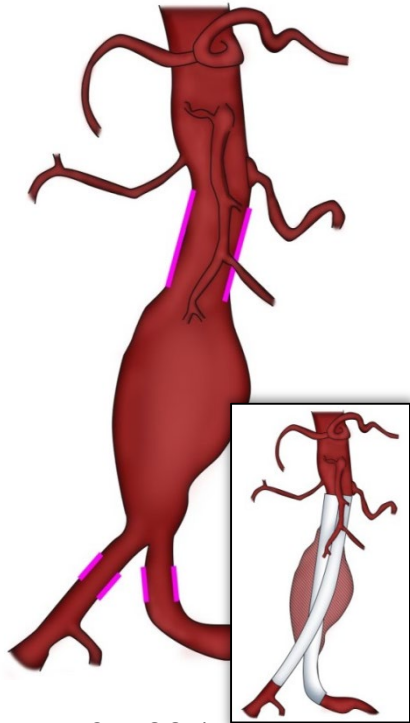




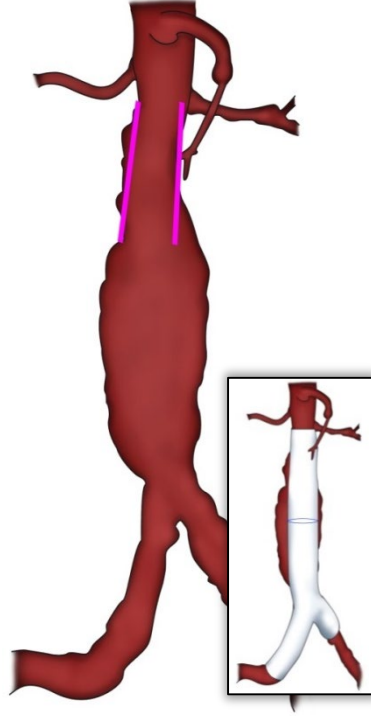
1 MOIS POST CHEMINEE



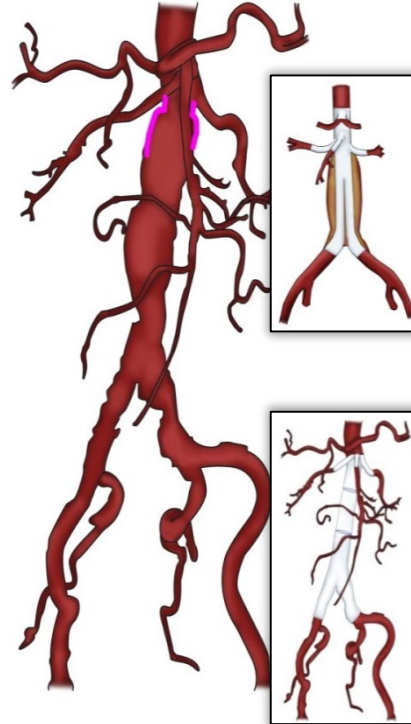
EVOLUTION RELATED CLASSIFICATION OF AAAS



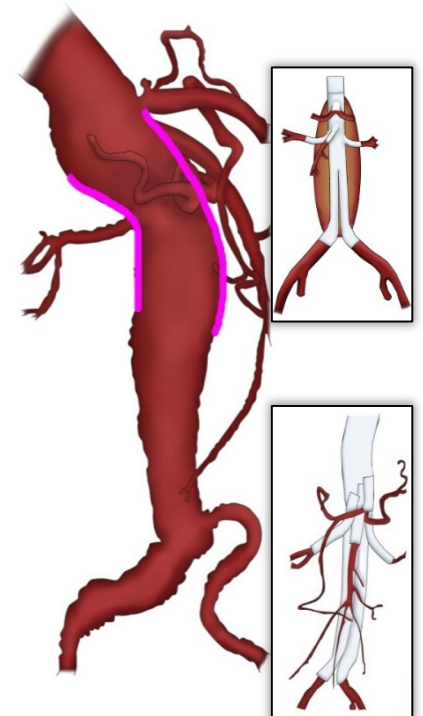
CLASS 1



CLASS 2



CLASS 3



CLASS 4

Options to achieve proximal sealing zone during endovascular repair of abdominal aortic aneurysm and correlated classification

Claude Mialhe, Fabien Lareyre¹⁰, Juliette Raffort

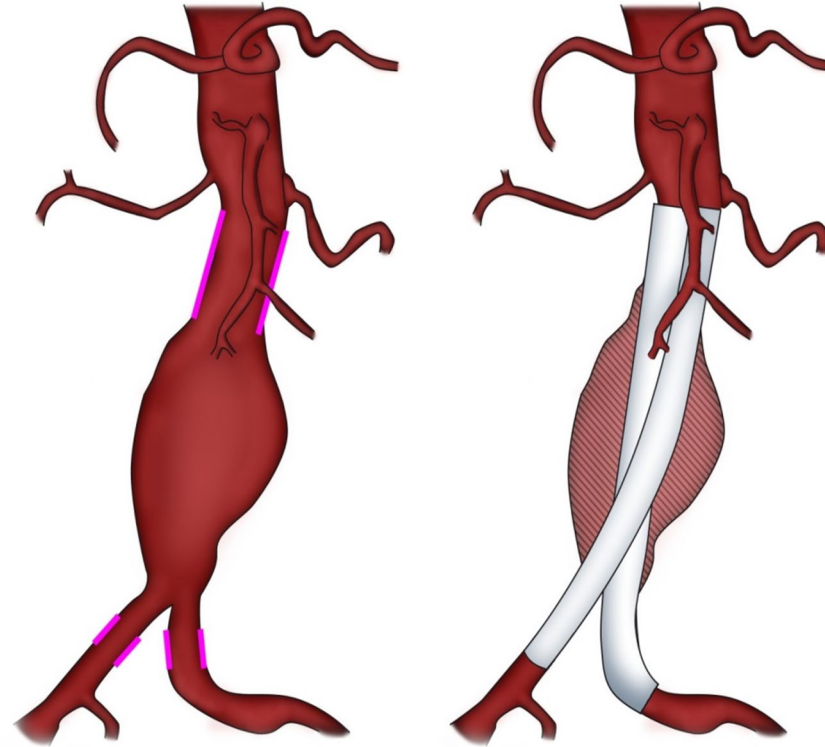
First Published July 23, 2019 | Article Commentary |



Vascular and
Endovascular Surgery

<https://doi.org/10.1177/1708538119864740>

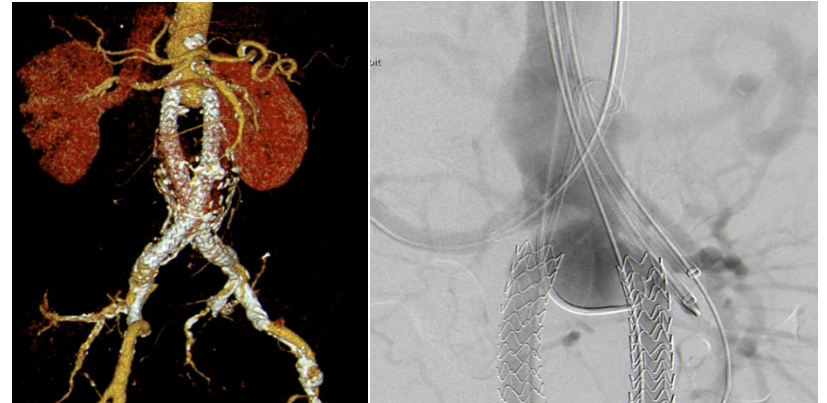
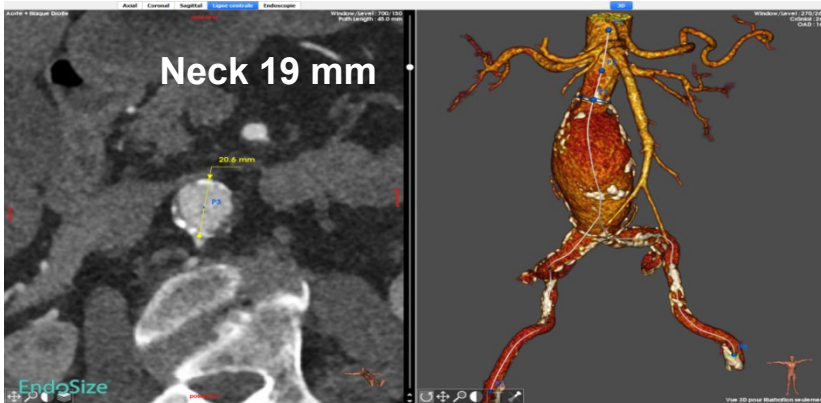
EVOLUTION RELATED CLASSIFICATION OF AAAS



CLASS 1

PRIMARY EVAS: nb 50

- Nb: 50
- Inclusion period: november 2013 october 2017
- Mean F.U.: 22 +/- 19 mths
- 1 ruptured Aneurysm of infra renal neck at 6y F.U.



(1 stent occlusion requiring thrombectomy)